

# Use of Intravascular Ultrasound to Improve Diagnosis and Treatment of Transjugular Intrahepatic Portosystemic Shunt Dysfunction in Patients in the Long-term Follow-up

Daniele Morosetti<sup>1</sup>, Ilaria Lenci<sup>2</sup>, Renato Argirò<sup>3</sup>, Martina Milana<sup>4</sup>, Fulvio Gasparri<sup>5</sup>, Sara Crociati<sup>6</sup>, Giuseppe Tisone<sup>7</sup>, Roberto Floris<sup>8</sup>, Leonardo Baiocchi<sup>9</sup>

## ABSTRACT

**Aim:** To evaluate the efficacy of intravascular ultrasound (IVUS) in transjugular intrahepatic portosystemic shunt (TIPS) revision associated with phlebography and invasive pressure measurement in patients with clinical or radiological signs of TIPS malfunction.

**Background:** Four patients underwent TIPS revision between February and August 2021. Right internal jugular vein access was achieved under ultrasonographic guidance, a catheter was advanced to achieve the Inferior Vena Cava (IVC) and afterward the Portal vein through the TIPS. Once the Portal vein was achieved, a phlebography was performed, followed by invasive pressure measurement and IVUS exam over the guidewire. Based on the combination of phlebography, invasive pressure measurement, and IVUS evaluations, TIPS dysfunction was treated either with angioplasty or stent apposition.

**Case description:** In all patients, we obtained the reduction of porto-systemic gradient. In three patients, angioplasty with a 10 mm diameter balloon catheter was performed. Anticoagulation therapy was added to one patient. In one patient, the Viatorr's proximal extremity in the suprahepatic vein wall was dislocated, so it was lengthened with a "Viabahn" covered stent. None of the patients developed hepatic encephalopathy after both TIPS placement and TIPS revision. No complications related to the procedure were observed during the follow-up. Clinical improvement in the immediate follow-up period was observed in all patients. In two patients, the abdominal ascites resolved. In another one, the abdominal pain disappeared, and a reduction of the longitudinal spleen diameter was recorded at 3 months follow-up.

**Conclusion:** The use of IVUS allowed us to correctly visualize the organic cause of TIPS malfunction and to obtain direct visualization of the results of endovascular treatment.

**Keywords:** Intravascular ultrasound, Transjugular intrahepatic portosystemic shunt dysfunction, Transjugular intrahepatic portosystemic shunt revision.

*Euroasian Journal of Hepato-Gastroenterology* (2022): 10.5005/jp-journals-10018-1374

## INTRODUCTION

Transjugular intrahepatic portosystemic shunt became a common approach for managing complications of portal hypertension. Despite this method is widely used to treat portal hypertension, shunt dysfunction may occur, especially in the long-term follow-up.<sup>1</sup> Transjugular intrahepatic portosystemic shunt patients who show recurrent signs and symptoms of portal hypertension or abnormal shunt gradient/parameters are referred for diagnostic examination and evaluated for interventional TIPS revision.<sup>2-9</sup>

Intravascular ultrasound guidance is a routinely used technique in interventional cardiology, while the use of IVUS in complex TIPS placement is growing in importance. However, there is a paucity of information on the safety and efficacy of the IVUS technique for TIPS revision.

Here, we present our TIPS follow-up protocol using intravascular ultrasound associated to phlebography and invasive pressure measurement for the evaluation of TIPS dysfunction in patients with direct and indirect signs of recurrent portal hypertension. The objective was to assess the quality improvement in diagnosis and treatment of TIPS dysfunction after IVUS associated to conventional phlebography and invasive venous pressure measurement.

<sup>1,3,5,8</sup>Department of Interventional Radiology Unit, Policlinico Universitario Tor Vergata, Rome, Italy

<sup>2,4,7,9</sup>Department of Experimental Medicine and Surgery, Policlinico Universitario Tor Vergata, Rome, Italy

<sup>6</sup>Department of Interventional Radiology Unit, University of Rome Tor Vergata, Rome, Latium, Italy

**Corresponding Author:** Sara Crociati, Department of Interventional Radiology Unit, University of Rome Tor Vergata, Rome, Latium, Italy, Phone: +39 3331579930, e-mail: sara.crociati94@gmail.com

**How to cite this article:** Morosetti D, Lenci I, Argirò R, *et al.* Use of Intravascular Ultrasound to Improve Diagnosis and Treatment of Transjugular Intrahepatic Portosystemic Shunt Dysfunction in Patients in the Long-term Follow-up. *Euroasian J Hepato-Gastroenterol* 2022; 12(1):50-56.

**Source of support:** Nil

**Conflict of interest:** None

## CASE DESCRIPTION

Four patients (51,7 ± 19,6 years, males) underwent TIPS revision between February 2021 and August 2021. This retrospective study was approved by our Institutional Review Board, and the

requirement for informed consent was waived. Medical records of patients who underwent endovascular procedures through IVUS were retrospectively reviewed.

Indication of TIPS revision was based on clinical criteria confirmed by diagnostic imaging performed with ultrasound and CT scan. Shunt dysfunction was defined as occlusion or stenosis (reduction of 50% of the shunt lumen or greater, a portosystemic gradient (PSG) >12 mm Hg) or occlusion/thrombosis.<sup>2-9</sup>

The same certified interventional radiologist with 12 years of attending experience was the primary operator in all cases. Right internal jugular vein access with a 9 Fr, 25 cm long introducer sheath (Terumo, Tokyo Japan) was achieved under ultrasonographic guidance, and a 5 Fr vertebral catheter (Terumo, Tokyo Japan) was advanced to approach the IVC and afterwards the Portal vein through the TIPS. Once the Portal vein was reached, phlebography was performed, followed by invasive pressure measurement and IVUS exam over the guidewire. Based on the combination of phlebography, invasive pressure measurement and IVUS evaluations, TIPS dysfunction was treated either with angioplasty or stent apposition. All patients underwent Doppler US evaluation 1 week, 1 month, 6 months, and yearly after TIPS revision procedure. Technical success was defined as vessel patency restoration confirmed by IVUS and invasive pressure measurement.

Complications were recorded as minor or major according to the Quality Improvement Guidelines for Transjugular Intrahepatic Portosystemic Shunts, 2016.<sup>9</sup>

### Intravascular Ultrasound

The IVUS equipment consisted of a 10-MHz probe placed at the extremity of a disposable diagnostic catheter for ultrasound imaging (VISIONS® PV 0.035 OTW Philips, Amsterdam, Dutch). The probe generates 360° images, allowing the evaluation of vascular morphology and geometry in blood vessels of the peripheral vascular system. During the procedure, the probe was advanced through the TIPS to assess the diameter of the lumen, the wall structure, and the integrity of the TIPS.

### Invasive Pressure Measurement

Venous pressures were measured (by saline manometer) in the portal vein, inside the stent, in IVC and in the right atrium, and PSGs were calculated.

### Statistical Analysis

The quantitative variables were presented as mean  $\pm$  st. dev. and compared through *t*-Student test for paired data. Descriptive statistics were used to determine the demographic characteristics of the population.

## RESULTS

Median follow-up period of TIPS revision was 27,2  $\pm$  6,6 months. The median pre-TIPS PSG was 18,5  $\pm$  2,4 mm Hg (16–21 mm Hg), and the median post-TIPS PSG was 7  $\pm$  3,8 mm Hg (2–10 mm Hg). Reduction of PSG was achieved in all patients. Two patients underwent TIPS revision for ascites, one for abdominal pain and distention with increased spleen diameter, and one for new onset of gastrointestinal bleeding. In all patients, a 10 mm diameter Viatorr was previously used. In three patients, the TIPS was placed as “Early TIPS” after variceal bleeding, while in one

we observed a portal thrombosis associated with the presence of gastro-esophageal varices. In three patients, angioplasty with a 10 mm diameter balloon catheter was associated to anticoagulation therapy. In one patient, the proximal extremity of the Viatorr stent was displaced towards the suprahepatic vessel wall. Thus, the stent was prolonged with a covered 11 mm  $\times$  5 cm Viabahn stent, but not dilated. No complications due to the procedure nor cases of hepatic encephalopathy were observed, both after the first TIPS and after revision. Clinical improvement in the immediate follow-up period was observed in all patients. In two patients, ascites regression occurred, and medical therapy was suspended. In one patient, the abdominal pain and tension disappeared, and a 1 cm reduction in longitudinal spleen diameter was recorded 3 months after the procedure. In one patient, no other variceal bleeding was recorded.

## DISCUSSION

Transjugular intrahepatic portosystemic shunt procedure has undergone technical improvement over time, particularly with the introduction of the Viatorr stent. Given the clinical and social conditions of patients undergoing TIPS and the recent introduction of the Viatorr stent, there are few clinical trials with long-term follow-up focused on the outcome of TIPS.<sup>9,10</sup> In the literature, TIPS dysfunctions are mainly related to inexact placement, reduced portal vein inflow, and hepatic vein outflow, together with myointimal hyperplasia and stenosis.

Stenosis of the hepatic vein occurs in 7–60% of cases, while multifocal stenosis is observed in 1–3% of patients.<sup>9,10</sup> However, clinical symptoms of TIPS dysfunction may vary, especially in patients undergoing Early TIPS for bleeding.<sup>11</sup>

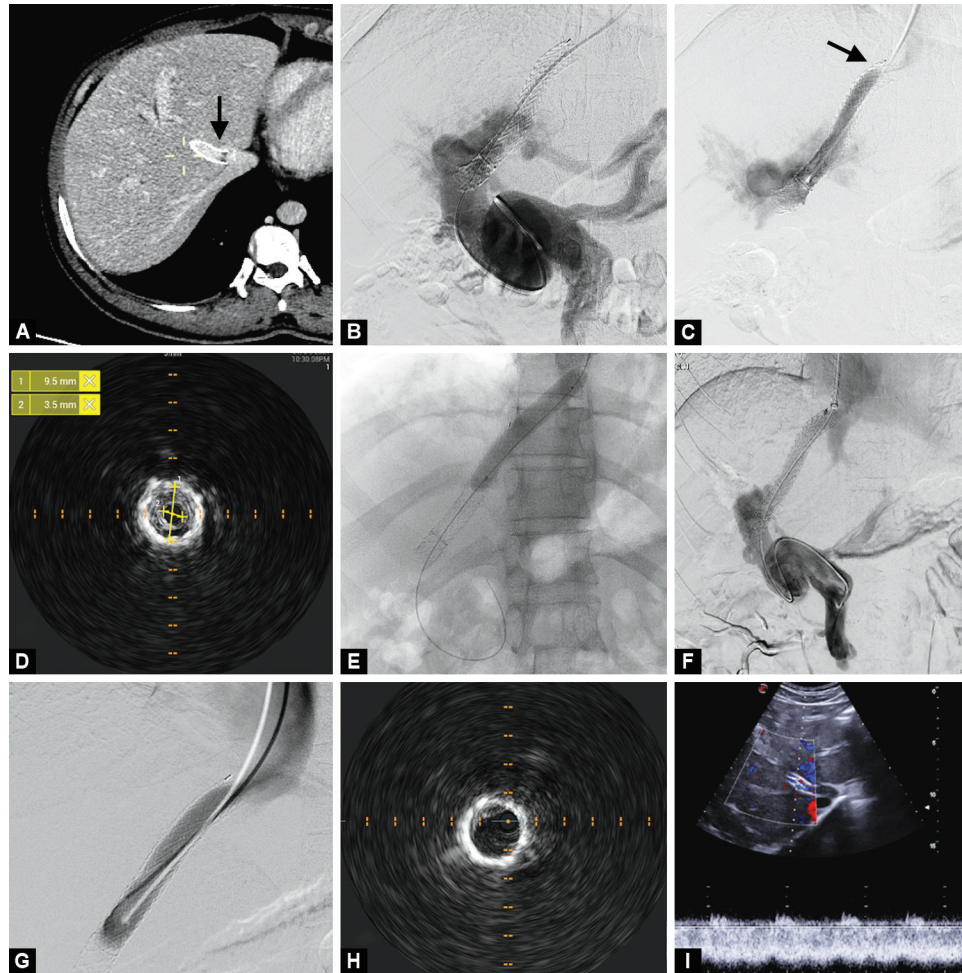
We included all patients with symptoms related to TIPS dysfunction by Doppler-US and contrast-enhanced CT scan. However, CT does not always allow optimal visualization of TIPS patency, especially in patients with increased abdominal circumference, ascites, poor cooperation, or complex anatomical localization of TIPS.

It is, therefore, essential to perform correct diagnosis and a targeted interventional endovascular procedure in order to restore the shunt caliber (Figs 1 to 4).

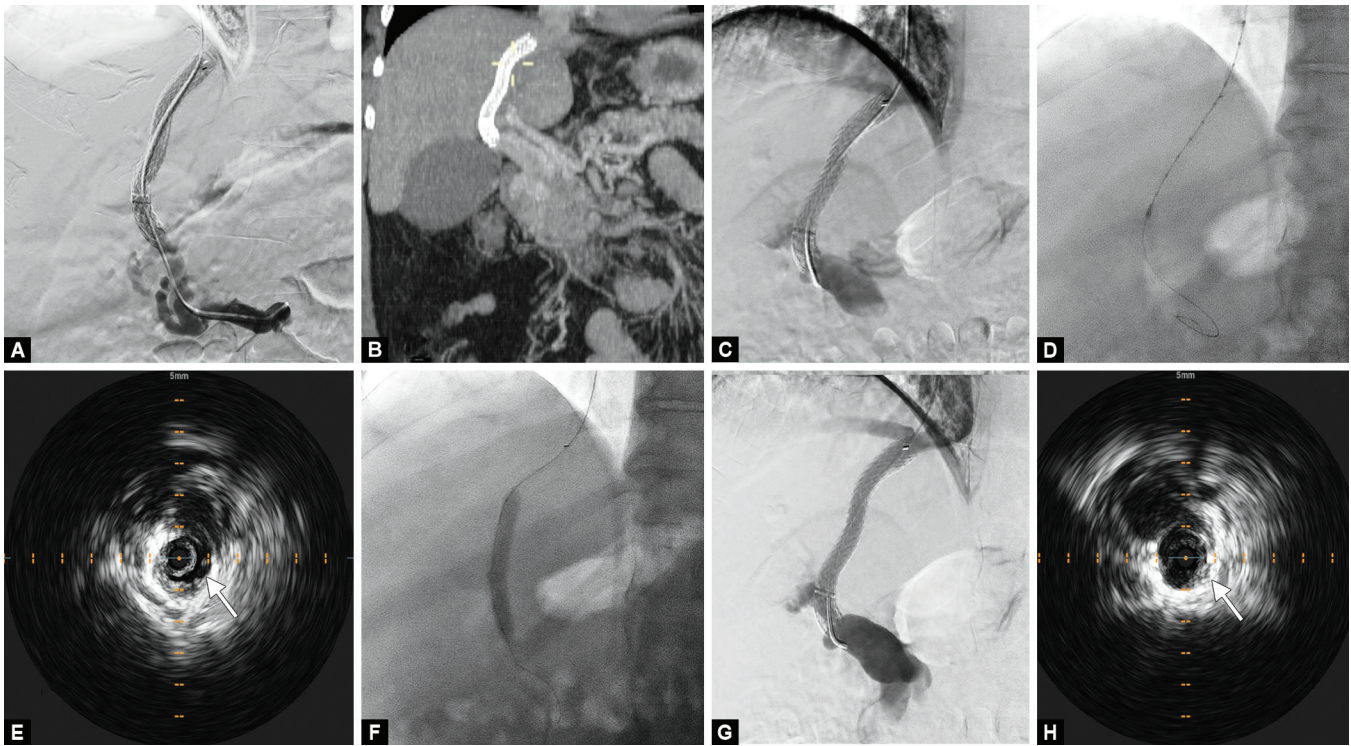
Intravascular ultrasound has been extensively investigated in arterial interventions and to a lesser extent during TIPS placement.<sup>12-17</sup> To our knowledge, we identified any clinical study focused on the use of IVUS as minimally invasive diagnostic method for the revision of TIPS. In literature, IVUS has been shown to be a useful method for TIPS placement. Intravascular ultrasound reduces the number of attempts to puncture the portal branches, the overall complication rate, the dose of radiation exposure for the patient, and the operator, and improves the overall clinical outcome.<sup>14-17</sup> However, in the study herein, we used a Philips probe, while commonly used IVUS probes are specifically designed for cardiology.

Analysis of TIPS outflow with IVUS was useful for the diagnosis and management of some TIPS dysfunction and to analyze the outcome after endovascular treatment (Figs 1 and 2). The endocavitary ultrasonography led us to evaluate both the wall of the portal vein and the stent (Figs 3 and 4).

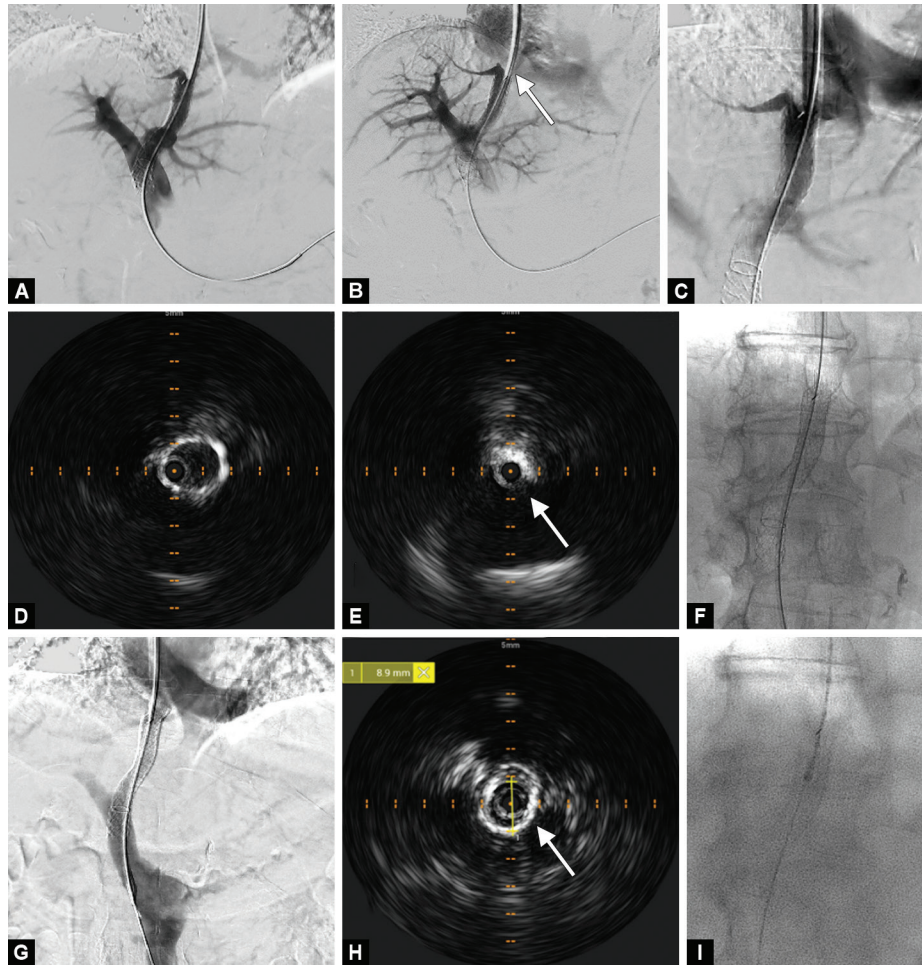
One limitation of the study is represented by the small sample size; Patients included received IVUS during treatment of TIPS



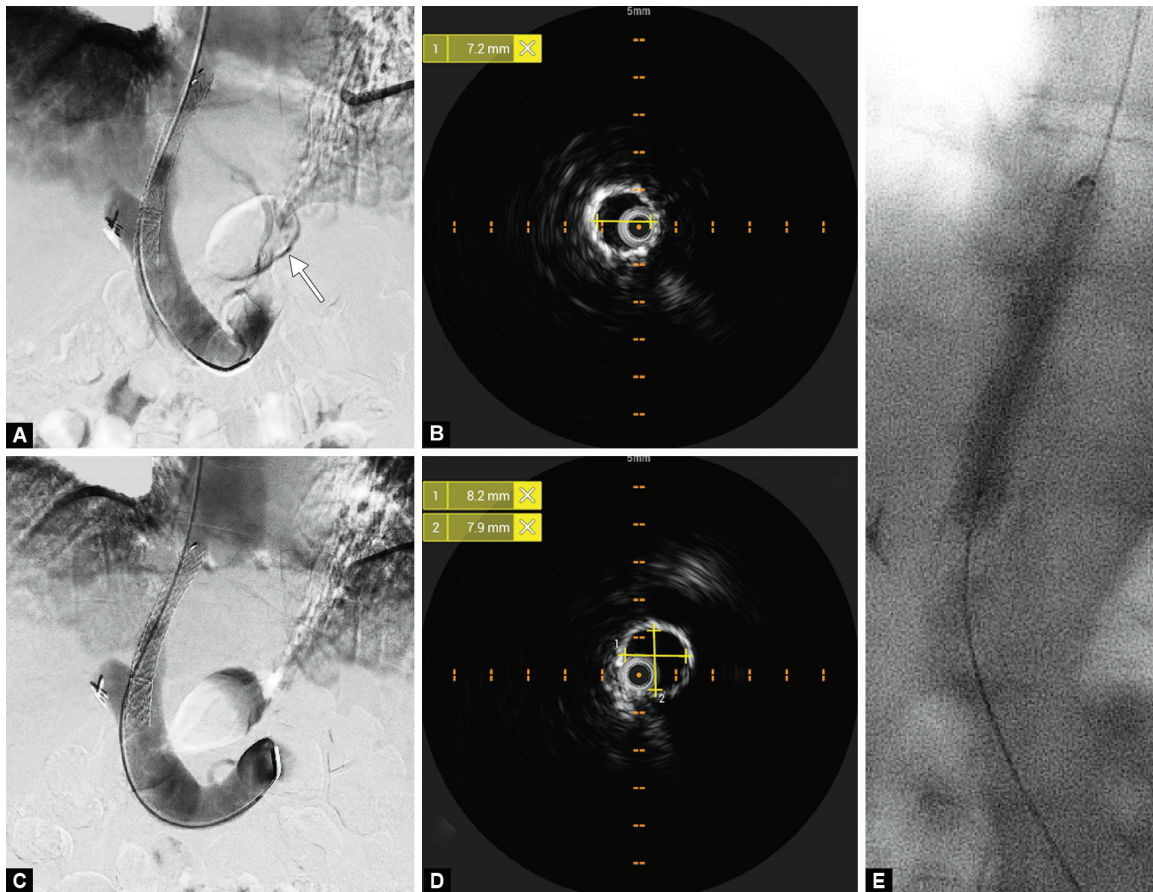
**Figs 1A to I:** Patient affected by cirrhosis at a young age due to schistosomiasis. Hemocromatosis in anamnesis. After almost 3 years from the TIPS procedure, he declared stomach aches and we discovered low TIPS blood flow using Doppler US and increased spleen longitudinal diameter. (A) CT scan showed an hypodense concentric apposition in the distal end of the Viatorr stent (black arrow); (B, C) In the phlebography, the intraparenchymal portal branches were highlighted with reduced blood flow through the TIPS. The selective phlebography inside the Viatorr confirmed significant stenosis at the distal end of the Viatorr stent (black arrow); (D) The IVUS showed a hypoechoic, probably fibrotic, concentric apposition which determined a reduced vessel lumen of 70%; (E) An angioplasty with a catheter balloon of 10 mm × 60 mm was performed; (F to H) The phlebographic and IVUS exams confirmed the stent patency restoration; (I) The Doppler US at 1-month follow-up confirmed the stent patency with a normal blood flow



**Figs 2A to H:** Patient previously treated for massive variceal bleeding with an “Early Tip”. Tips dysfunction after 18 months of follow-up. (A) TIPS placement in a patient with cavernomatosis and previous variceal bleeding; (B) CT scan performed in the follow-up period reported an increased dimension of the cavernomatosis in the hepatic hilum without signs of shunt dysfunction due to artifact for abdominal circumference; (C to E) The phlebography and IVUS examinations showed fibro-lipid layer on the uncovered part of the TIPS, probably caused by flow turbulence generated in the cavernomatous segment of the portal vein (E; arrow), which was subsequently treated with angioplasty with a 10 mm × 40 mm balloon catheter (F); (G, H): Control with phlebography, IVUS and venous pressures reported reduction of the long fibrolipidic apposition (arrow) and pressure values



**Figs 3A to I:** Patient treated with an “Early TIPS”. New onset of portal hypertension symptoms and refractory ascites after 20 months of TIPS procedure. (A to C) The phlebography, performed after distal catheterization of the portal vein, reported dislocation of the proximal end of the Viatorr stent which was dropping in the cranial wall of the hepatic vein, with a direct blood flow toward the cranial vessel wall of the suprahepatic vein (white arrow); (D, E) The IVUS dynamic evaluation confirmed the dislocation of the proximal end (white arrow); (F) A 10 mm × 5 cm Viabahn covered stent was applied in the proximal end of the Viatorr stent with a stent patency restoration; (G to I) The phlebography and IVUS control (white arrow) reported a restored stent caliber and a direct blood flow from the portal vein toward the right atrium, with a reduced opacification of the intraparenchymal portal branches



**Figs 4A to E:** Patient previously treated for acute massive variceal bleeding. (A) The phlebography evaluation showed the presence of gastroesophageal varices (white arrow) and initial cavernomatosis, in absence of intraluminal defects; (B) The IVUS examination reported a reduced stent diameter at the third middle of the stent compared to the diameter of the TIPS previously placed (8 mm × 8 cm); (C to E) An angioplasty with a 9 mm × 60 mm Armada 35 balloon catheter was performed with increased stent diameter at IVUS, an increased blood flow inside the TIPS, and a reduced opacification of the varices

dysfunction. Moreover, evaluation of IVUS with this kind of probe as an aid for minimally invasive diagnostic protocol during the follow-up of patients who underwent TIPS is not present in medical literature. We reported for the first time a new valid diagnostic option for the management of TIPS dysfunction.

The learning curve in our study was very short since our team has experience in the arterial district. At present, the method is expensive due to the cost of the probe, even if we managed to remain within limits established by the National Health System reimbursement.

### Clinical Significance

In this study, the use of IVUS allowed us to correctly visualize the organic and functional cause of TIPS dysfunction and to obtain direct visualization of the results of endovascular treatment. Although in a limited sample, IVUS increased the diagnostic accuracy and the precision of the technique.

### ORCID

Sara Crociati  <https://orcid.org/0000-0002-3529-0947>

### REFERENCES

1. Dariushnia SR, Haskal ZJ, Midia M, et al. Quality improvement guidelines for transjugular intrahepatic portosystemic shunts. *J Vasc Interv Radiol* 2016;27(1):1–7. DOI: 10.1016/j.jvir.2015.09.018.
2. Haskal ZJ, Pentecost MJ, Soulen MC, et al. Transjugular intrahepatic portosystemic shunt stenosis and revision: early and midterm results. *AJR Am J Roentgenol* 1994;163(2):439–444. DOI: 10.2214/ajr.163.2.8037046.
3. Saxon RR, Ross PL, Mendel-Hartvig J, et al. Transjugular intrahepatic portosystemic shunt patency and the importance of stenosis location in the development of recurrent symptoms. *Radiology* 1998;207(3):683–693. DOI: 10.1148/radiology.207.3.9609891.
4. LaBerge JM, Ferrell LD, Ring EJ, et al. Histopathologic study of stenotic and occluded transjugular intrahepatic portosystemic shunts. *J Vasc Interv Radiol* 1993;4(6):779–786. DOI: 10.1016/s1051-0443(93)71972-7.
5. Hagiwara S, Kudo M, Kawasaki T, et al. Prognostic factors for portal venous invasion in patients with hepatocellular carcinoma. *J Gastroenterol* 2006;41(12):1214–1219. DOI: 10.1007/s00535-006-1950-7.
6. Cura M, Cura A, Suri R, et al. Causes of TIPS dysfunction. *Am J Roentgenol* 2008;191(6):1751–1757. DOI: 10.2214/AJR.07.3534.

7. Maschke SK, Werncke T, Renne J, et al. Transjugular intrahepatic portosystemic shunt (TIPS) dysfunction: quantitative assessment of flow and perfusion changes using 2D-perfusion angiography following shunt revision. *Abdom Radiol (NY)* 2018;43(10):2868–2875. DOI: 10.1007/s00261-018-1547-7.
8. Nazarian K. Pictorial Essay Techniques for Transjugular Intrahepatic Portosystemic Shunt Revision; 1998.
9. Perelló MP, Mur JP, Vives MS, et al. Long-term follow-up of transjugular intrahepatic portosystemic shunt (TIPS) with stent-graft. *Diagn Interv Radiol* 2019;25(5):346–352. DOI: 10.5152/dir.2019.18416.
10. Weber CN, Nadolski GJ, White SB, et al. Long-term patency and clinical analysis of expanded polytetrafluoroethylene-covered transjugular intrahepatic portosystemic shunt stent grafts. *J Vasc Interv Radiol* 2015;26(9):1257–1265. DOI: 10.1016/j.jvir.2015.04.005.
11. D'Amico G, Maruzzelli L, Airoidi A, et al. Performance of the model for end-stage liver disease score for mortality prediction and the potential role of etiology. *J Hepatol* 2021;75(6):1355–1366. DOI: 10.1016/j.jhep.2021.07.018.
12. Chiocchi M, Morosetti D, Chiaravalloti A, et al. Intravascular ultrasound assisted carotid artery stenting: randomized controlled trial. Preliminary results on 60 patients. *J Cardiovasc Med* 2019;20(4):248–252. DOI: 10.2459/JCM.0b013e32835898f1.
13. Chiocchi M, Chiaravalloti A, Morosetti D, et al. Virtual histology-intravascular ultrasound as a diagnostic alternative for morphological characterization of carotid plaque: comparison with histology and high-resolution magnetic resonance findings. *J Cardiovasc Med* 2019;20(5):335–342. DOI: 10.2459/JCM.0b013e328356a5d2.
14. Kao SD, Morshedi MM, Narsinh KH, et al. Intravascular ultrasound in the creation of transhepatic portosystemic shunts reduces needle passes, radiation dose, and procedure time: a retrospective study of a single-institution experience. *J Vasc Interv Radiol*. 2016;27(8):1148–1153. DOI: 10.1016/j.jvir.2016.01.137.
15. Farsad K, Fuss C, Kolbeck KJ, et al. Transjugular intrahepatic portosystemic shunt creation using intravascular ultrasound guidance. *J Vasc Interv Radiol* 2012;23(12):1594–1602. DOI: 10.1016/j.jvir.2012.08.023.
16. Pillai AK, Andring B, Faulconer N, et al. Utility of Intravascular US-guided portal vein access during transjugular intrahepatic portosystemic shunt creation: retrospective comparison with conventional technique in 109 patients. *J Vasc Interv Radiol* 2016;27(8):1154–1159. DOI: 10.1016/j.jvir.2016.05.010.
17. Gipson MG, Smith MT, Durham JD, et al. Intravascular US-guided portal vein access: improved procedural metrics during TIPS creation. *J Vasc Interv Radiol* 2016;27(8):1140–1147. DOI: 10.1016/j.jvir.2015.12.002.