

## VIEWPOINT

# Following historical “tracks” of hair follicle miniaturisation in patterned hair loss: Are elastin bodies the forgotten aetiology?

D. Hugh Rushton<sup>1</sup>  | Gillian E. Westgate<sup>2</sup>  | Dominique J. Van Neste<sup>3</sup>

<sup>1</sup>School of Pharmacy & Biomedical Sciences, University of Portsmouth, Portsmouth, UK

<sup>2</sup>Centre for Skin Sciences, Faculty of Life Sciences, University of Bradford, Bradford, UK

<sup>3</sup>Skinterface, 121 Avenue du Couronnement, B-1200 Brussels, Belgium

**Correspondence**

Gillian E Westgate, Centre for Skin Sciences, Faculty of Life Sciences, University of Bradford, Bradford, West Yorkshire, BD7 1DP, UK.  
Email: g.westgate@bradford.ac.uk

**Abstract**

Pattern hair loss (PHL) is a chronic regressive condition of the scalp, where follicular miniaturisation and decreased scalp hair coverage occurs in affected areas. In all PHL cases, there is a measurable progressive shortening of the terminal hair growth duration, along with reduced linear growth rates. In both genders, PHL initially shows an increase in short telogen hairs  $\leq 30$  mm in length, reflecting a cycle completion of under 6 months in affected terminal hair follicles. To understand the miniaturisation process, we re-examine the dynamics of miniaturisation and ask the question, “why do miniaturised hair follicles resist treatment?” In the light of recent developments in relation to hair regeneration, we looked back in the older literature for helpful clues “lost to time” and reprise a 1978 Hermann Pinkus observation of an array of elastin deposits beneath the dermal papilla following subsequent anagen/telogen transitions in male balding, originally described by Arao and Perkins who concluded that these changes provide a “morphologic marker of the entire biologic process in the balding scalp.” Thus, we have reviewed the role of the elastin-like bodies in hair pathology and we propose that alterations in elastin architecture may contribute to the failure of vellus-like hair reverting back to their terminal status and may indicate a new area for therapeutic intervention.

**KEYWORDS**

androgenetic alopecia, dermis, elastin body, hair follicle, hair follicle miniaturisation, vellus hair

## 1 | INTRODUCTION

In this review, we examine hair follicle miniaturisation and how functional changes to the follicle and its environment might explain the variable nature of current treatment success and provide new insights for those researchers developing new hair regeneration strategies.<sup>1</sup> It is well established that common balding in men (male pattern hair loss, MPHL) and women (female pattern hair loss, FPHL)—referred here as patterned hair loss (PHL)—involves a progressive regression in the fundamental hair variables (density, growth phase, diameter

and growth rate) which involves androgen initiation in susceptible individuals.<sup>2–6</sup> In 1942, James Hamilton observed that following androgen ablation no reversal of miniaturised hair occurred in men with established PHL and we have previously reported that current medical treatments do not reverse miniaturisation.<sup>4–6</sup> These observations question why miniaturised terminal hair follicles cannot revert to their former terminal status. We revisit a 50-year-old observation initially reported by Arao and Perkins in 1969<sup>7</sup> and again by Pinkus in 1978<sup>8</sup> that an “elastin body” comprising dense elastic tissue deposited beneath the follicle after each cycle, might explain the

This is an open access article under the terms of the Creative Commons Attribution-NonCommercial License, which permits use, distribution and reproduction in any medium, provided the original work is properly cited and is not used for commercial purposes.

© 2021 The Authors. *Experimental Dermatology* published by John Wiley & Sons Ltd.

irreversibility of follicle miniaturisation. In dissecting the mechanisms driving follicle miniaturisation, we have looked again into the 20th century literature to reprise the excellent work of such authors as, Van Scott<sup>9</sup> Noback<sup>10</sup> Arao<sup>7</sup> Headington,<sup>11</sup> Kligman,<sup>12</sup> Latannand,<sup>13</sup> Montagna,<sup>14</sup> Parakkal,<sup>15</sup> Pinkus<sup>8,16</sup> and Uno.<sup>17</sup>

## 2 | BACKGROUND—TRACKING HAIR FOLLICLE MINIATURISATION

It is generally accepted that a scalp hair follicle cyclically reproduces itself so as to maintain complete scalp coverage. Each hair cycle transition appears to be heralded by a change in the dynamics of the cycle to arrive at a new steady state. In balding, this initially includes a shortened cycle length with slowing down of daily growth rates without any significant change in hair diameter followed by a progressive regression through an “intermediate” stage, that ultimately leads to a stable miniaturised or transformed vellus-like follicle<sup>4,18</sup> even before the clinician can perceive reduced scalp coverage, terminal hair (diameters > 60  $\mu\text{m}$ ) decrease (Figure S1). The earliest measurements in affected follicles involve a shortening of the anagen phase, an increase in telogen (shed) hairs and, in particular, those telogen club hairs  $\leq 30$  mm in length, a reduced rate of hair growth, followed by a reduction in hair diameter.<sup>19–21</sup> From the clinical point of view, a substantial amount of individual hair follicle regression is required before noticeable hair loss is perceived by clinicians (>15%<sup>19</sup>).

We present herein our opinion that current treatments do not reverse miniaturisation; that their success is due to preventing complete regression and maintaining a prolonged productive phase in terminal follicles not yet irreversibly miniaturised.<sup>5</sup> However, if reversing the miniaturisation process is the ultimate research objective to provide an effective and improved treatment for PHL, then the following fundamental questions of the miniaturisation process itself are raised:

1. Are those miniaturised hairs ( $\leq 40$   $\mu\text{m}$  in diameter,  $\leq 30$  mm in length) found in balding subjects produced by the same vellus hair follicles that we observe in healthy non-balding scalps? If so, is there any means to non-invasively differentiate between these two sub-populations in order to understand miniaturisation in PHL?
2. What might be preventing miniaturised hair follicles from being converted back to their formal terminal hair status?

### 2.1 | A brief history lesson into anatomical—clinical correlations and the significance of structure of the follicular unit

The tradition of medical schools took several centuries before realising that human hair follicles were worth some “academic”

consideration with biological and clinical implications. Historical changes that occur in common baldness in men were qualified by Duhring as early as 1883 as a change from “perfect hair” being replaced by “imperfect hair”.<sup>22</sup> We will also mention later that the same author already reported that hair follicles were surrounded by an elastic “basket,” a somewhat neglected network. The process of decreased “perfection” was nicely described in 1958 by Van Scott<sup>9</sup> “as a progressive diminution in the size of terminal hairs.” In the 1960s, the prevailing view “that balding in men results from the metamorphosis of hair follicles from terminal to vellus,” a supposition supported in 1967 by Uno et al.<sup>23</sup> In 1951, Noback<sup>10</sup> “classified the vellus hair as one in which the follicle has no erectile tissue.” This was later referred to by Uno et al and others, who were of the view that “vellus type” hairs that develop from terminal hair during the balding process may still have wisps of arrector pili muscle (APM) attached to them.<sup>23,24</sup> Danforth (1939) reported “vellus hair follicles of the forehead undergo no changes from childhood to old age”.<sup>25</sup> These early seemingly forgotten observations may provide insights into the miniaturisation of terminal hairs to “vellus-like hairs” or what we refer to as miniaturised hairs and their histological identification through APM remnants. The histochemistry methods used, including the detection of elastin, is also important in interpreting the architecture, as APM attachment site to follicles is marked using elastin staining and the APM in miniaturised follicles retains its attachment to the stela.<sup>13</sup> It is not yet clear whether the loss of attachment of the APM is “causal” in follicle miniaturisation but was also described by Torkamani et al where they used 3D morphometry to show that vellus-like hairs were no longer attached, in contrast to follicles in alopecia areata where APM attachment was maintained.<sup>26</sup>

### 2.2 | Miniaturised hairs on the scalp do not transition back to terminal hairs with treatment

Numerous studies have attempted to define vellus hairs by utilising hair diameters  $\leq 30$   $\mu\text{m}$  (biopsies) and  $\leq 40$   $\mu\text{m}$  (non- and semi-invasive methods).<sup>27–29</sup> From our investigations, a validated, quantitative parameter for a vellus hair was determined and a working classification established; Table S1. Thus, a hair  $\leq 40$   $\mu\text{m}$  in diameter and  $\leq 30$  mm in length is that of a vellus or vellus-like hair. This definition has been employed in unit area trichogram evaluations to characterise miniaturising terminal hairs in MPH and FPHL studies.<sup>19,30–32</sup> Having revisited the concept that in PHL there are both vellus and vellus-like (miniaturised) follicles, we demonstrate that the miniaturised follicle itself appears rather stable with time, once formed (although eventual deletion has been reported<sup>33</sup>). Although their proportion increases in untreated PHL (Table 1), this vellus-like population appears to be unaffected by hair growth treatments.<sup>4,5,34,35</sup> We illustrate this with our UAT findings in men treated with topical 3% minoxidil + anti-androgens and oral finasteride (1.25 mg) for 12 months, Table 2. As well as showing that the number of vellus-like hairs remains stable, the

**TABLE 1** Unit area trichogram changes in frontal hair variables of untreated men exhibiting male pattern hair loss (MPHL) over 12 months and 24 months, values at T-12 and T-24 were compared with their baseline T-0 values (Mean  $\pm$  SD)

Frontal Area (Mean $\pm$ SD)	Time - 0	(n = 22)	Time -12 months
Total Hair/cm <sup>2</sup> (Range)	230 $\pm$ 54 (144–346)		**215 $\pm$ 50 (140–330)
<sup>a</sup> Vellus-Like Hair/cm <sup>2</sup> (Range)	35 $\pm$ 18 (4–119)		*41 $\pm$ 20 (6–110)
Anagen Hair/cm <sup>2</sup> (Range)	147 $\pm$ 45 (58–239)		***131 $\pm$ 48 (43–244)
Frontal Area (Mean $\pm$ SD)	Time-0	(n = 10)	Time -24 months
Total Hair/cm <sup>2</sup> (Range)	226 $\pm$ 41 (159–311)		**199 $\pm$ 30 (129–238)
<sup>a</sup> Vellus-Like Hair/cm <sup>2</sup> (Range)	50 $\pm$ 30 (21–87)		*63 $\pm$ 31 (27–111)
Anagen Hair/cm <sup>2</sup> (Range)	120 $\pm$ 28 (80–164)		**96 $\pm$ 20 (68–128)

Abbreviation: SD, standard deviation.

Student's *t* test (paired samples) -

<sup>a</sup>Vellus-like in these cases would reflect follicle miniaturisation and the resident normal vellus hair.

\*(*p* < 0.05–1 tail); \*\*(*p* < 0.01); \*\*\*(*p* < 0.001).

**TABLE 2** Unit area trichogram changes in hair variables in 30 men exhibiting MPHL treated with topical 3% minoxidil + anti-androgens and oral finasteride (1.25 mg) for 12 months

Variable (Mean $\pm$ SD)	Frontal T = 0	Frontal T = 12	Difference 0 v 12	Significance level
Total Hair Density/cm <sup>2</sup>	196 $\pm$ 77	**233 $\pm$ 75	37 $\pm$ 29	** <i>p</i> < 0.0001
Anagen Hair/cm <sup>2</sup>	130 $\pm$ 53	**167 $\pm$ 61	37 $\pm$ 32	** <i>p</i> < 0.0001
§Vellus-Like Hair/cm <sup>2</sup>	34 $\pm$ 25	37 $\pm$ 27	3 $\pm$ 22	NS
Telogen Hair $\leq$ 30 mm/cm <sup>2</sup>	36 $\pm$ 25	29 $\pm$ 27	-7 $\pm$ 19	* <i>p</i> < 0.05

Student's *t* test (paired samples)—NS, not significant; \**p* < 0.05, \*\**p* < 0.0001, SD, standard deviation: §Vellus-like hairs reflect follicle miniaturisation, and this population is not influenced by treatment. Treatment resulted in a decrease in telogen hair  $\leq$ 30 mm per cm<sup>2</sup>, indicating longer growing hairs due to an extended anagen phase. However, given the absolute increase in hairs per cm<sup>2</sup> but no change in the absolute vellus-like hair population, reactivation of the dormant (kenogen) hair phase, is the most likely cause for the increased hair growth observed in the medical treatment of PHL.

number of short ( $\leq$ 30 mm club hairs) decreases with treatment, suggesting that the increase in hair growth comes from increase in hair growth duration, not a decrease in vellus-like hairs, suggesting rescue of intermediate hair follicles and/or activation of follicles in kenogen.<sup>6</sup> The point at which miniaturisation becomes inevitable was observed when the terminal hair diameter in actively changing FPHL patients was  $\leq$ 50  $\mu$ m.<sup>31</sup> Recent research<sup>36</sup> provides a huge database as evidence of many years' worth of clinical data and clearly shows that the terminal follicle goes through a dynamic transition with shorter anagen cycles, still producing a hair of significant diameter, but with bulbs seated above the dermal adipose layer, and suggests that subsequent decrease in terminal hair diameter from  $>$ 60  $\mu$ m to between 40 and 50  $\mu$ m might be the point at which miniaturisation of a terminal hair follicle becomes irreversible. In over 20 years of treating MPHL with topical minoxidil, anti-androgens and oral finasteride, using unit area trichograms (UAT) and contrast-enhanced-phototrichograms, we have found no change in the absolute vellus-like hair population, suggesting "vellus-like" hairs can be stabilised but not reversed with current treatments. Furthermore, while treatment maintained or improved total hair/cm<sup>2</sup>, increased anagen hair/cm<sup>2</sup>, and hairs able to grow longer than 30 mm in length/cm<sup>2</sup>, such transformations are not achieved by reversing hair follicle miniaturisation, implying rescue of follicles not yet miniaturised or activation of kenogen<sup>6</sup>

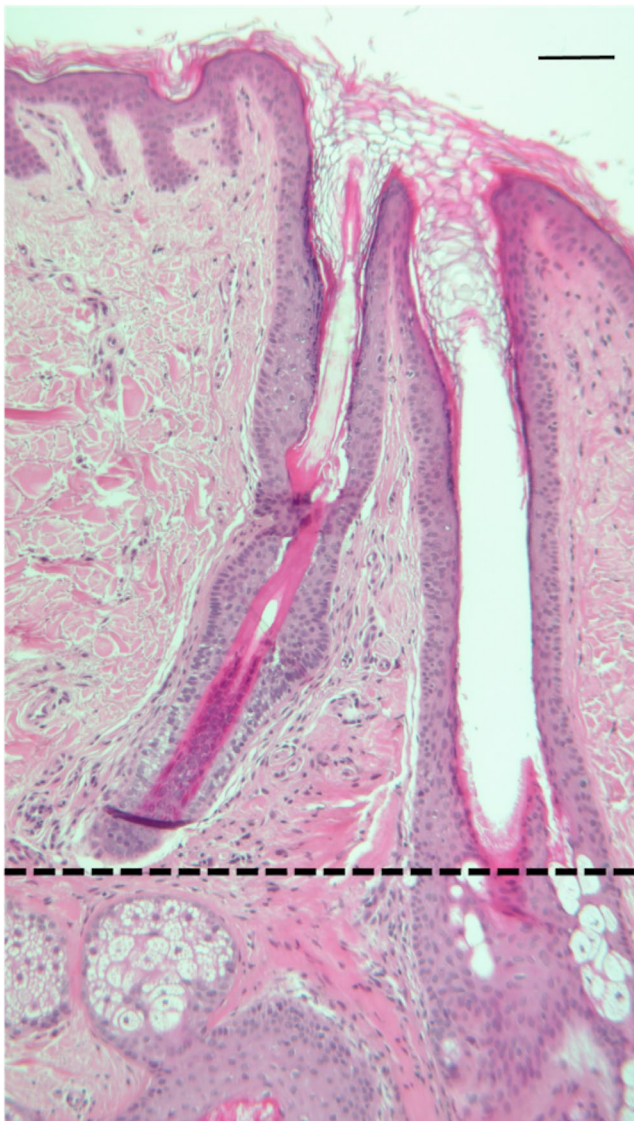
or "empty" follicles in telogen raises an intriguing question; what is preventing the reversal of miniaturisation?

### 2.3 | Are Arao-Perkins elastin-like bodies the forgotten aetiology?

Following the description by Duhring in 1883 that an elastic basket contained the hair follicle,<sup>22</sup> Tatsuyoshi Arao and Edwin Perkins<sup>7</sup> described the complex and intricate elastin fibre deposition around hair follicles; with the key features being the presence of a delicate elastin filament network at the intersection of the arrector pili muscle and the outer root sheath, and a knot of elastin-like fibres in the base of the dermal papilla (DP), referred to as an "elastin-like" body owing to the differences in staining colours observed with the orcein-haematoxylin stain used. This led to the term Arao-Perkins (AP) body and although being mentioned in the hair biology literature, notably for this review by Pinkus (1978)<sup>8</sup> in relation to follicle miniaturisation in pattern hair loss, few citations have appeared since. In 2016, Cranwell & Sinclair reference the Pinkus paper but make no comment on the dense elastic tissue deposited beneath the follicle after each cycle, which might explain the irreversibility of follicle miniaturisation.<sup>24</sup> The potential and significant implications of the Pinkus findings appear to have

been overlooked—even Pinkus himself noted 'Preceding observers had only scant attention to elastic fibres and thereby missed significant features of diagnostic and pathogenetic importance',<sup>16</sup> little has changed since then.

Here, we re-examine the significance of the follicle elastin architecture in relation to changes in balding scalp, particularly in relation to the terminal to vellus transition in follicle miniaturisation. As stated above, the so-called 'terminal to vellus' transition implies that the balding vellus follicle is the same as a true vellus follicle. We, and others before us, believe this is not the case. In an excellent series of papers on the balding macaque, Hideo Uno described the miniaturised follicles as "transformed vellus follicles" and distinguishable from scalp vellus follicles unchanged since childhood.<sup>17,37</sup> This is also confirmed in human<sup>13</sup> and shown in Figure 1. Where the vellus follicle clearly does not have an arrector pili muscle attached. Employing



**FIGURE 1** Human scalp H&E. Natural vellus follicle is shown without an arrector pili muscle and its bulb does not extend beyond the level of the sebaceous duct in the adjacent terminal hair follicle, as illustrated by the dotted line. Scale bar 100  $\mu$ m

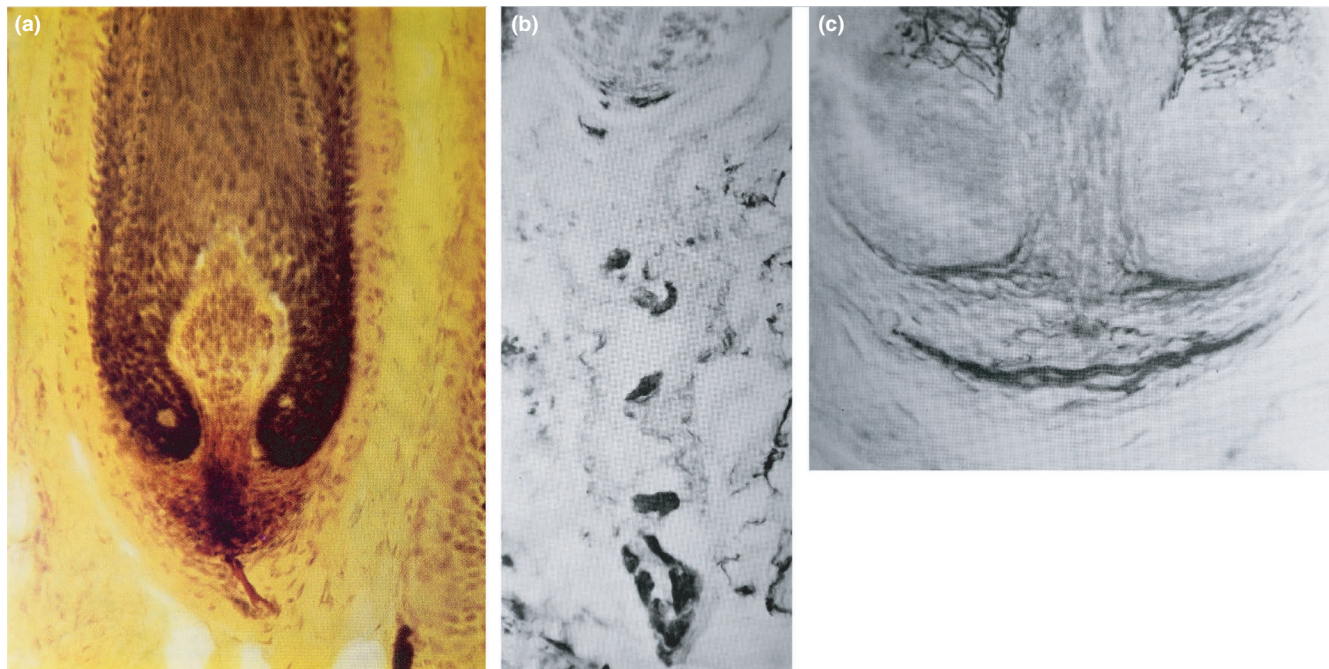
elastin staining, Uno clearly distinguishes true vellus scalp follicles as having no arrector pili muscle (APM)<sup>23</sup> whereas transformed vellus-like follicles either retain attachment or evidence of the terminal follicle APM being close by [13].

Elastin stains are widely used in hair histopathology, where such stains can be helpful in diagnosis between scarring and non-scarring alopecia, importantly by differentiating between a follicular scar and a follicular streamer underlying a regressed follicle.<sup>38,39</sup>

The types of stain used include Verhoeff-Van Gieson, also known as elastic Van Gieson stain (EVG)<sup>38</sup> and acid alcoholic orcein, claimed by Pinkus to be able to differentiate types of elastin.<sup>7,8</sup> These studies conclude that there is a fine elastic fibre network surrounding the anagen hair follicle, not only in human scalp as originally described by Duhring in 1883<sup>22</sup> but also in the macaque.<sup>23,37</sup> Such staining is described as a "coat" of fine elastic fibres at the follicle isthmus, relatively less in the connective tissue sheath and an elastic fibre bundle or basket at the base of the dermal papilla. Arao<sup>7</sup> noted that the elastin-like body in the DP was more developed in young versus older adults, and, as Arao quoted "the most beautiful, finest structures of the elastin filaments are formed at puberty" suggested a physiological "maturation process" and/or an intimate relationship to androgen action on the hair follicle? So, what is the role of the elastic basket surrounding the hair bulb and why is the elastin body of Arao and Perkins so relevant in modified hair cycling occurring in pattern hair loss?

Pattern balding is generally associated with mild inflammation and fibrosis<sup>40</sup> and the conversion of terminal follicles to smaller "vellus-like" follicles that reside in the upper dermis, that classically involves multiple anagen to catagen to telogen conversions.<sup>11,12,41</sup> However, Whiting, using scalp biopsies theorised that miniaturisation could happen in one single hair cycle.<sup>27</sup> While miniaturisation might have occurred due to rapid cycling over a period of 12–18 months,<sup>33</sup> but within one cycle is difficult to accept as catastrophic follicular changes would be required. Understanding the role and fate of the follicular micro-environment and especially the extracellular matrix (ECM) in catagen is important, as is the role of the inflammatory component<sup>40,42–44</sup> and further investigations are needed.

In the absence of balding, the AP elastin body is observed at the base of the DP in anagen and, apparently, does not impede the growth of the next terminal anagen follicle (Figure 2A, C) and the elasticity of the basket might be involved in determining the depth to which an anagen bulb descends. How the follicle "knows" when to stop descending is not known. While Arao and Perkins<sup>7</sup> showed variability of the AP body with age in their brief reports, perhaps of utmost interest was the observation by Pinkus<sup>8</sup> who detected a distinct ladder-like pattern of AP bodies in the follicle streamer under regressed follicles in balding, with AP bodies seemingly a permanent marker of the previous hair cycle in follicles undergoing miniaturisation, Figure 2B. As the normal catagen process in non-bald subjects does not leave a "mark" in the form of an AP elastin-like body in the follicle streamer, we propose that there must be a system that degrades and resorbs elastic tissue remnants of a previous cycle, removing an impediment to return to terminal anagen growth. So,



**FIGURE 2** Elastin staining in neck and immediately below a terminal anagen hair follicle in human scalp A, C, and in the stelae beneath, a miniaturised hair follicle in human scalp showing several elastic “Arao-Perkins” bodies distributed as a ladder, B. The image in A shows a terminal anagen HF stained for elastin using orcein-haematoxylin in iodised ferric chloride, counterstained with metanil yellow, showing the elastin-containing “plug” at the base of the anagen follicle. (Reproduced with permission from Arao and Perkins 1967; Reference [7],  $\times 100$ ). B, C show elastin staining using acid alcoholic orcein and Giemsa solutions as described by Pinkus 1978 and reproduced from reference [8] with permission. B  $\times 100$ , C  $\times 200$

do changes in elastic tissues contribute to, or just mark cyclic alterations in balding?

### 3 | HYPOTHESIS

We hypothesise that the lack of catabolic capabilities and/or altered deposition of elastic tissue during follicle miniaturisation in balding represents a type of elastosis—damaging the tissue and preventing new terminal hair growth. We speculate that in the hair follicle in balding, this process involves androgen action and thus have examined what is known about androgen-mediated changes in ECM and elastic tissues in particular. The transformation of a terminal anagen follicle from anagen to telogen involves remarkable tissue remodelling over a short few days or weeks, with two thirds of the follicle regressing during catagen.<sup>15,45</sup> The earliest hair biologists noted structural changes to the connective tissue sheath and “pleating” of the basal lamina,<sup>12,15,39</sup> and however, the significance of changes to elastin during catagen has not been studied in detail, so the observations made by Pinkus in the 1970s of the elastic body ladder<sup>8,16</sup> have not been reexamined in relation to catagen in follicle miniaturisation. It is well known that transforming-growth-factor beta (TGF $\beta$ -1) is increased in catagen and drives catagen.<sup>46,47</sup> It is also understood that an effect of androgens on shortening the hair cycle may also be mediated by TGF $\beta$  production by the DP cells.<sup>48,49</sup> TGF $\beta$  is also known to

increase ECM turnover, and in tissues where elastin is an important component, the effects of TGF $\beta$  have been shown to act transcriptionally to increase elastin synthesis.<sup>50</sup>

Thus, the “Arao Perkins” body as a marker of the hair cycle as seen in miniaturising follicles as a “ladder” of insoluble elastic tissue, may in fact, reflect a marker of androgen action on the follicle in successive cycles? This, in turn, may help provide a mechanism of anti-androgen action in arresting hair loss by preventing the abnormal deposition of insoluble elastin and explain the finding of Hamilton<sup>3</sup> in 1942, that androgen ablation in castrated balding males, averted progression of the balding process.

Given that there is also an elastic network surrounding the anagen hair follicle (as described herein), we also might speculate whether there is a positive role for elastic component in the immediate surrounding of the hair roots in, (i) helping the catagen follicle mechanically regress? (ii) facilitating the increase in anagen density with pregnancy reflecting hormonally induced circulation of growth factors and enzymes that help in relaxation of collagen-elastic fibres (elastases and collagenases) that may help in relaxation of any fibrotic-elastotic barriers that prevent undue lateral or deeper follicular extension, (iii) the intriguing possibility that minoxidil might act on hair growth through its actions on smooth muscle type cells to increase elastin production, as in aorta,<sup>51</sup> and (iv) the lack of elastin in the stelae is indicative of scarring alopecia,<sup>52</sup> suggesting loss of the elastic network is part of the loss of follicle tissues, indicating its importance to normal hair structure.

## 4 | OPEN QUESTIONS AND HOW TO ANSWER THESE

We ask the question “Are Arao-Perkins elastin bodies, containing abnormally deposited elastin, preventing the reversal of hair follicle miniaturisation in female and male pattern hair loss?” In order to explore this, we propose that scalp tissue from males and females with pattern hair loss is stained using both the histochemical stains as used originally, but also complimented with antibody staining for both elastin and collagen. The lysyl oxidase (LOX) family encodes copper-dependent amine oxidases that are important in determining the tensile strength and structural integrity of connective tissues, including skin, by catalysing the crosslinking of elastin or collagen.<sup>53</sup> LOX functions in the organisation of the extracellular matrix in the ovary under the influence of hormonal activity<sup>54,55</sup> and LOX with TGF $\beta$  regulates elastin gene expression in dermal fibroblasts.<sup>56</sup> We also consider other fibrotic disorders, such as idiopathic pulmonary fibrosis (IPF) and kidney disease that also involve alteration in elastin deposition under the influence of TGF $\beta$  and LOX. IPF is associated with elevated elastin-collagen crosslinking and activation of myofibroblasts—a cell type that forms the follicle connective tissue sheath (CTS). The extracellular matrix exhibits a loss of elasticity and in the lung, this equated to loss of tissue function.<sup>57</sup> Kidney disease fibrosis is also associated with greater crosslinking of the collagen and elastin fibres due to elevation of LOX. Techniques used in renal disease pathology include elastin imaging<sup>58</sup> so comparison of the follicle in AGA and kidney would be a worthy exercise, not least as these two organs have already been compared recently in this journal.<sup>59</sup>

In future studies, particular attention needs to be made to an examination of the changes in stela under follicles that are undergoing miniaturisation<sup>60</sup> to seek out the “Arao-Perkins” bodies and to characterise them using modern molecular methods and characterising this particular type of fibrosis. Strategies such as expanding the size of the DP to reverse miniaturisation<sup>61</sup> also should consider whether the Arao-Perkins elastin body may remain an impediment to efficacy. A molecular approach is also suggested to understand androgen action on fibroblasts isolated from the DP, CTS and dermis in relation to production and metabolism/crosslinking of elastin, at both gene expression and protein modification levels. Finally, functional studies to examine key controls in signalling pathways to elastin gene expression in scalp skin should yield targets for future therapeutic intervention, as recently suggested for Gamma aminobutyric acid (GABA) action in human dermal fibroblasts.<sup>62</sup>

## 5 | CONCLUSION AND PERSPECTIVES

We hope that this journey back in time, looking at the past lessons from eminent hair researchers, will in future lead to the identification of new treatment solutions to “unblock” the reversal of hair miniaturisation, focusing on abnormal elastin deposition as the cause of a regenerative “block.” New regeneration treatments, such as cell therapy,<sup>61</sup> are proposed to target what might be considered to be failing

terminal follicles prior to full miniaturisation. We predict that future research into the role of the elastin body in follicle biology might deliver a new adjuvant to current and future therapeutics to help rescue and/or maintain the optimal follicle size, structure and function of terminal follicles and promote clinically useful hair growth.

### ACKNOWLEDGEMENT

We would like to acknowledge Professor Andrew Messenger for critical review of the manuscript.

### CONFLICT OF INTEREST

The authors state no conflicts of interest.

### AUTHOR CONTRIBUTION

DHR conceived the hypothesis, and both DHR and DVN contributed the data included. DHR, DVN and GEW contributed equally to writing the paper.

### DATA AVAILABILITY STATEMENT

The data that support the findings of this study are available from the corresponding author upon reasonable request.

### ORCID

D. Hugh Rushton  <https://orcid.org/0000-0001-8340-9802>

Gillian E. Westgate  <https://orcid.org/0000-0001-6645-9568>

### REFERENCES

- McElwee KJ, Tosti A. New developments in hair research. *Exp Dermatol.* 2020;29(3):204-207.
- Hamilton JB. The relationship between common baldness and male sex hormones. *Trans N Y Acad Sci.* 1946;8:101-102.
- Hamilton JB. Male hormone stimulation is prerequisite and an incitant in common baldness. *Am J Anat.* 1942;71(3):451-480.
- Rushton DH, Norris MJ, Van Neste D. Hair regrowth in male and female pattern hair loss does not involve the conversion of vellus hair to terminal hair. *Exp Dermatol.* 2016;25(6):482-484.
- Van Neste D. Placebo-controlled dose-effect studies with topical minoxidil 2% or 5% in male-patterned hair loss treated with oral finasteride employing an analytical and exhaustive study protocol. *Skin Res Technol.* 2020;26(4):542-557.
- Guarrera M, Rebora A. The higher number and longer duration of kenogen hairs are the main cause of the hair rarefaction in androgenetic alopecia. *Skin Appendage Disord.* 2019;5(3):152-154.
- Arao T, Perkins E. The interrelation of elastic tissue and human hair follicles. In: Montagna W and Dobson RE, ed. *Advances in biology of skin. Vol Hair growth: proceedings of the University of Oregon Medical School Symposium on the Biology of Skin, 1967.* Oxford: Pergamon Press; 1969:433-440.
- Pinkus H. Differential patterns of elastic fibers in scarring and non-scarring alopecias. *J Cutan Pathol.* 1978;5(3):93-104.
- Van Scott EJ, Ekel TM. Geometric relationships between the matrix of the hair bulb and its dermal papilla in normal and alopecic scalp. *J Invest Dermatol.* 1958;31(5):281-287.
- Noback CR. Morphology and phylogeny of hair. *Ann N Y Acad Sci.* 1951;53(3):476-492.
- Headington JT. Transverse microscopic anatomy of the human scalp. A basis for a morphometric approach to disorders of the hair follicle. *Arch Dermatol.* 1984;120(4):449-456.

12. Kligman AM. The human hair cycle. *J Invest Dermatol.* 1959;33:307-316.
13. Lattanand A, Johnson WC. Male pattern alopecia a histopathologic and histochemical study. *J Cutan Pathol.* 1975;2(2):58-70.
14. Montagna W, Chase HB, Melaragno HP. Histology and cytochemistry of human skin. I. Metachromasia in the mons pubis. *J Natl Cancer Inst.* 1951;12(3):591-597.
15. Parakkal PF. Morphogenesis of the hair follicle during catagen. *Z Zellforsch Mikrosk Anat.* 1970;107(2):174-186.
16. Pinkus H. Epithelial-mesodermal interaction in normal hair growth, alopecia, and neoplasia. *J Dermatol.* 1978;5(3):93-101.
17. Uno H. Nonhuman primate model of baldness. Premature aging of hair follicle and hormones. *Int J Dermatol.* 1982;21(1):21-23.
18. Randall VA. Androgens and hair growth. *Dermatol Ther.* 2008;21(5):314-328.
19. Rushton DH, Ramsay ID, Norris MJ, Gilkes JJ. Natural progression of male pattern baldness in young men. *Clin Exp Dermatol.* 1991;16(3):188-192.
20. Van Neste DJ, Rushton DH. Gender differences in scalp hair growth rates are maintained but reduced in pattern hair loss compared to controls. *Skin Res Technol.* 2016;22(3):363-369.
21. Van Neste D. Natural scalp hair regression in preclinical stages of male androgenetic alopecia and its reversal by finasteride. *Skin Pharmacol Physiol.* 2006;19(3):168-176.
22. Dhuring LA. Traité pratique des maladies de la peau traduit et annoté sur la 2e édition par le Dr Toussaint Barthélémy et le Dr Adolphe Colson avec une préface par Alfred Fournier. In: Paris: Masson; 1883:279.
23. Uno HA, Allegra F, Adachi K, Montagna W. Studies of common baldness of the stump-tailed macaque: I. Distribution of the hair follicles. *J Invest Dermatol.* 1967;49:288-296.
24. Cranwell W, Sinclair R. Male Androgenetic Alopecia. In: Feingold KR, Anawalt B, Boyce A, et al, *Endotext.* South Dartmouth (MA); 2000. PMID: 25905192.
25. Danforth CH. Physiology of human hair. *Physiol Rev.* 1939;19:94-111.
26. Torkamani N, Rufaut N, Jones L, Sinclair R. The arrector pili muscle, the bridge between the follicular stem cell niche and the interfollicular epidermis. *Anat Sci Int.* 2017;92(1):151-158.
27. Rushton DH. Chemical and morphological properties of scalp hair in normal and abnormal states [PhD]. Cardiff: Welsh School of Pharmacy, University of Wales. 1988.
28. Whiting DA, Waldstreicher J, Sanchez M, Kaufman KD. Measuring reversal of hair miniaturization in androgenetic alopecia by follicular counts in horizontal sections of serial scalp biopsies: results of finasteride 1 mg treatment of men and postmenopausal women. *J Invest Dermatol Symp Proc.* 1999;4(3):282-284.
29. Sinclair R. Male pattern androgenetic alopecia. *BMJ.* 1998;317(7162):865-869.
30. Rushton H, James KC, Mortimer CH. The unit area trichogram in the assessment of androgen-dependent alopecia. *Br J Dermatol.* 1983;109(4):429-437.
31. Rushton DH, Ramsay ID, James KC, Norris MJ, Gilkes JJ. Biochemical and trichological characterization of diffuse alopecia in women. *Br J Dermatol.* 1990;123(2):187-197.
32. Rushton DH, Unger WP, Cotterill PC, Kingsley P, James KC. Quantitative assessment of 2% topical minoxidil in the treatment of male pattern baldness. *Clin Exp Dermatol.* 1989;14(1):40-46.
33. Messenger AG, Sinclair R. Follicular miniaturization in female pattern hair loss: clinicopathological correlations. *Br J Dermatol.* 2006;155(5):926-930.
34. Van Neste D. Viable terminal scalp hair follicles constitute a necessary and sufficient biological end-organ that conditions clinical efficacy of finasteride in males with male pattern hair loss without implying reversal of miniaturized follicles. *Skin Res Technol.* 2019;25(5):701-711.
35. Van Neste D. Maintenance of optimised hair growth from viable terminal scalp hair follicles at baseline with oral finasteride in male pattern hair loss and first evidence of a "drug dependency" and a post-finasteride "rebound effect". *Skin Res Technol.* 2019;25(5):712-719.
36. Dominique VN. Exhaustive analysis of scalp hair regression: subjective and objective perception from initial hair loss to severe miniaturisation and drug-induced regrowth. *Plast Aesthet Res.* 2021;8(16). <http://dx.doi.org/10.20517/2347-9264.2020.220>
37. Uno HAK, Montagna, W. Morphological and biochemical studies of hair follicles in common baldness of the stump-tailed macaque (*Macaca, speciosa*). In: *Advances in Biology of Skin*, 6th edn. Oxford (Eds: W Montagna, RL Dobson) Pergamon Press; 1968:221-244.
38. Tan T, Guitart J, Gerami P, Yazdan P. Elastic staining in differentiating between follicular streamers and follicular scars in horizontal scalp biopsy sections. *Am J Dermatopathol.* 2018;40(4):254-258.
39. Horenstein MG, Jacob JS. Follicular streamers (stelae) in scarring and non-scarring alopecia. *J Cutan Pathol.* 2008;35(12):1115-1120.
40. Jaworsky C, Kligman AM, Murphy GF. Characterization of inflammatory infiltrates in male pattern alopecia: implications for pathogenesis. *Br J Dermatol.* 1992;127(3):239-246.
41. Birch MP, Messenger JF, Messenger AG. Hair density, hair diameter and the prevalence of female pattern hair loss. *Br J Dermatol.* 2001;144(2):297-304.
42. Westgate GE, Craggs RI, Gibson WT. Immune privilege in hair growth. *J Invest Dermatol.* 1991;97(3):417-420.
43. Westgate GE, Messenger AG, Watson LP, Gibson WT. Distribution of proteoglycans during the hair growth cycle in human skin. *J Invest Dermatol.* 1991;96(2):191-195.
44. Muneeb F, Hardman JA, Paus R. Hair growth control by innate immunocytes: perifollicular macrophages revisited. *Exp Dermatol.* 2019;28(4):425-431.
45. Kloepper JE, Sugawara K, Al-Nuaimi Y, Gaspar E, van Beek N, Paus R. Methods in hair research: how to objectively distinguish between anagen and catagen in human hair follicle organ culture. *Exp Dermatol.* 2010;19(3):305-312.
46. Foitzik K, Lindner G, Mueller-Roever S, et al. Control of murine hair follicle regression (catagen) by TGF-beta1 in vivo. *FASEB J.* 2000;14(5):752-760.
47. Hibino T, Nishiyama T. Role of TGF-beta2 in the human hair cycle. *J Dermatol Sci.* 2004;35(1):9-18.
48. Stenn KS, Paus R. Controls of hair follicle cycling. *Physiol Rev.* 2001;81(1):449-494.
49. Yoo HG, Kim JS, Lee SR, et al. Perifollicular fibrosis: pathogenetic role in androgenetic alopecia. *Biol Pharm Bull.* 2006;29(6):1246-1250.
50. Daamen WF, Quaglini D. Signaling pathways in elastic tissues. *Cell Signal.* 2019;63:109364.
51. Slove S, Lannoy M, Behmoaras J, et al. Potassium channel openers increase aortic elastic fiber formation and reverse the genetically determined elastin deficit in the BN rat. *Hypertension.* 2013;62(4):794-801.
52. Fung MA, Sharon VR, Ratnarathorn M, Konia TH, Barr KL, Mirmirani P. Elastin staining patterns in primary cicatricial alopecia. *J Am Acad Dermatol.* 2013;69(5):776-782.
53. Laczko R, Csiszar K. Lysyl oxidase (LOX): functional contributions to signaling pathways. *Biomolecules.* 2020;10(8):1093.
54. Harlow CR, Rae M, Davidson L, Trackman PC, Hillier SG. Lysyl oxidase gene expression and enzyme activity in the rat ovary: regulation by follicle-stimulating hormone, androgen, and transforming growth factor-beta superfamily members in vitro. *Endocrinology.* 2003;144(1):154-162.
55. Henmi H, Endo T, Nagasawa K, et al. Lysyl oxidase and MMP-2 expression in dehydroepiandrosterone-induced polycystic ovary in rats. *Biol Reprod.* 2001;64(1):157-162.

56. Huang M, Liu Z, Baugh L, et al. Lysyl oxidase enzymes mediate TGF-beta1-induced fibrotic phenotypes in human skin-like tissues. *Lab Invest*. 2019;99(4):514-527.
57. Upagupta C, Shimbori C, Alsilmi R, Kolb M. Matrix abnormalities in pulmonary fibrosis. *Eur Respir Rev*. 2018;27(148):180033.
58. Sun Q, Baues M, Klinkhammer BM, et al. Elastin imaging enables noninvasive staging and treatment monitoring of kidney fibrosis. *Sci Transl Med*. 2019;11(486):eaat4865.
59. Carre JL, Suzuki T, Paus R. Do hair follicles operate as primitive, multifocal kidney-like excretory (mini-) organs? *Exp Dermatol*. 2020;29(3):357-365.
60. El-Domyati M, Attia S, Saleh F, Abdel-Wahab H. Androgenetic alopecia in males: a histopathological and ultrastructural study. *J Cosmet Dermatol*. 2009;8(2):83-91.
61. Pantelireis N, Higgins CA. A bald statement - current approaches to manipulate miniaturisation focus only on promoting hair growth. *Exp Dermatol*. 2018;27(9):959-965.
62. Uehara E, Hokazono H, Hida M, Sasaki T, Yoshioka H, Matsuo N. GABA promotes elastin synthesis and elastin fiber formation in normal human dermal fibroblasts (HDFs). *Biosci Biotechnol Biochem*. 2017;81(6):1198-1205.

#### SUPPORTING INFORMATION

Additional supporting information may be found online in the Supporting Information section.

Figure S1 Hair types (terminal, intermediate, miniaturised with the vellus-like and nano hair) with increasing severity of PHL. (Reproduced with permission from the publisher)<sup>s1</sup>

Supplementary Material TABLE S1 Absolute parameters for the hair variables obtained with the Unit Area Trichogram (UAT)<sup>s3,s4</sup> in 20 normal male and 20 normal female Caucasian subjects aged between 20 and 30 years

**How to cite this article:** Rushton DH, Westgate GE, Van Neste DJ. Following historical “tracks” of hair follicle miniaturisation in patterned hair loss: Are elastin bodies the forgotten aetiology? *Exp Dermatol*. 2022;31:102-109. <https://doi.org/10.1111/exd.14393>