



Case report

Evaluation of coexistence of cancer and active tuberculosis; 16 case series

Beyhan Çakar^{a,*}, Aydın Çiledağ^b^a The Department of Tuberculosis Control at Ministry of Health, Dispensary Number 7, Ankara, Turkey^b Ankara University School of Medicine, Chest Disease Department, Ankara, Turkey

ARTICLE INFO

Keywords:

Coexistent

Cancer

Tuberculosis

Tuberculosis treatment

ABSTRACT

Introduction: Tuberculosis is an important risk factor for cancer. Pulmonary TB and lung cancer(LC) may mimic each other especially in the aspect of the clinical and radiological features. The aim of the study was to evaluate the features and risk factors of cases with coexistence cancer and active TB.

Methodology: We retrospectively reviewed the medical records of patients with coexisting TB and cancer a period from 2009 to 2014. We evaluated demographic data, the ways diagnosis of TB cases, the location of TB and cancer, TB treatment results of the cases.

Results: We recorded 374 TB cases in our dispensary at this study period. In 16 (4%) of these cases, a coexistence of cancer and TB was detected. The male/female ratio was 12/4. The mean age was $62,12 \pm 15,13$ years. There were TST results except three cases. There were ten pulmonary TB and six extra-pulmonary TB (four peripheral lymphadenopathy TB, one abdominal TB lymphadenopathy and one salivary gland TB). Cancer types were as follows; eight lung cancer, two breast cancer, one base of tongue, one endometrium cancer, one hypopharyngeal cancer, one stomach cancer, one bladder cancer and one maxillary cancer. Diagnosis of all cases was confirmed by bacteriologic and/or histopathological examination. Squamous cell carcinoma was the most common type of cancers. This rate was 9/16. All TB cases were new. There were risk factors out of two case in the cases. Five cases were died during TB treatment. Others completed TB treatment without any complication.

Conclusions: In our study, the coexistence of LC and pulmonary TB was more common. The local immunity is deteriorated in cancer cases. If there is pulmonary infiltrates in lung or peripheral lymphadenopathy, we must search tuberculosis too out of metastatic lesion and other infectious diseases. We should not make delay in the diagnosis of active TB in cancer cases.

1. Introduction

Cancer and tuberculosis is the most cause of morbidity and mortality, and a major public health problem worldwide. The interaction between lung cancer(LC) and active tuberculosis is known for many years. The first description of ‘cancerous phthisis’ was reported by Bayle in 1810 [1–5]. Chronic infections like pulmonary tuberculosis process that may lead to carcinogenesis of the lung tissue according to the production of cytokines, thus stimulate tumor growth and progression, this may result in genetic damage [6]. Malignancy itself may effect bone marrow and cause depletion in all cell lines, thus immune response may not be deteriorate [7,8]. Tuberculosis is an important risk factor for cancer. The dormant bacilli may activate due to disturbed defense mechanisms. Pulmonary cancer mortality was higher in people with tuberculosis than in those without. Diagnosis may be delay and the patient's survival may be shorter [9].

One-third of the world's population is infected with *Mycobacterium*

Tuberculosis bacillus. According to global tuberculosis report 2016 of WHO, TB affects more than 9 million people and causes the death of 1.8 million people each year, especially in developing countries [10]. In the world, there were approximately 14 million new cancer cases, 8.2 million cancer related death and 32.6 million people living with cancer in 2012 and the three most common cancer diagnosed among men. lung, prostate and colorectal Ca, among in women breast, colorectal and LC. Cigarette smoking is the important risk factor and cases almost 20% of global cancer deaths and 70% of global LC deaths [11]. In our study, our aim was to evaluate features of coexisting of cancer and active TB cases in a six-year period.

2. Methodology

We retrospectively reviewed data from the recorded files of patients between the years of January 2009 and December 2014. We collected demographics data (age, gender occupation), clinical features and

* Corresponding author. Ankara Tuberculosis Control, Dispensary No 7, 06100, Cebeci, Ankara, Turkey.

E-mail addresses: becakar@yahoo.com (B. Çakar), aciledag@yahoo.com (A. Çiledağ).

Table 1
The features of cases with coexistence of cancer and active tuberculosis.

Years M/F*	Occupation	TST/BCG*scar	Risk factors	TB localization	Sputum smear and culture, Biopsy results	Resistant test to drugs (AFB)	Histological type of lung cancer	TB diagnosis way and the latent time between onset of TB treatment and diagnosis of cancer (day)**	TB treatment result
87/M	Retired	18 mm/0	Cigarette smoker(Family contact +)	Pulmonary TB	+ / + (Mycobacterium Tuberculosis complex)	Sensitive to major drugs (HRZE)	Lung Ca (Squamous cell carcinoma)	Sputum smear AFB positive during fourth chemotherapy (171day)	Cure*
77/M	Retired	18 mm/0	HBSAg +, AntiHCV* +, DM + Cr: viral hepatic C+ CVD* + Renal failure	TBLD* (Extra thoracic LN)	- / - Lymph node biopsy (granulomatous inflammation with caseous necrosis)		Non hodgkin lymphoma Large Cell Ca in Lung and bronchial Ca (moderately differentiated Squamous cell carcinoma)	Suspected inflammation in chest radiograph, + Right supraclavicular, axillary and inguinal lymph node biopsy (12day)	Died within second month TB treatment
57/M	Retired	10 mm/2	Cigarette Smoker	Pulmonary TB	+ / + (Mycobacterium tuberculosis complex)	Sensitive to major drugs (HRZE)	Non hodgkinslymphoma, Large Cell treatment in 2001 and BAL (squamous cell carcinoma) in 2010)	First TB diagnosis (BAL liquid AFB positive).Then CA diagnosis (Wedge resection (30day)	Treatment Completion
60/M	Retired	10 mm/2	Hypertension Cigarette smoker	Pulmonary TB	- / + (Mycobacterium tuberculosis complex)	Absent resistant test to drugs	Moderately differentiated Squamous cell carcinoma of the base of tongue	Suspected inflammation in chest radiograph, sputum smear AFB positive(46day)	Treatment Completion
69/F	House women	24 mm/1	Absent	TBLD(Intra-abdominal LN)	Lymph node biopsy (granulomatous inflammation with caseous necrosis)		Endometrial Ca and mixed Mullerian Tumor	Diagnosis intra -abdominal lenf nodu biopsy during Serviks Ca operation(34day)	Died within sixth month TB treatment
69/F	Retired	16 mm/0	Her relative TB (before 50 years)	TBLD(Right supraclavicular LN)	Lymph node biopsy (granulomatous inflammation with caseous necrosis)		Breast Ca(Biopsy result was absent in file)	Right supraclavicular lymph node in control operation	Treatment Completion
59/M	Driver	12 mm/1	Cigarette Smoker	Pulmonary TB	+ / + (MOTT(M.szulgat)	Absent resistant test to drugs	Lung Ca (pleomorphic carcinoma)	Suspected inflammation in chest radiograph, (24day)	Cure
80/M	Retired	15 mm/0	Absent	TBLD (Cervical LN)	Lymph node biopsy (granulomatous inflammation with caseous necrosis)		Lung Ca (Squamo cell carcinoma, poorly differentiate	To investigate metastase to find right supraclavicular lymph node (10 day)	Treatment Completion
50/M	Worker	Absent	COPD	Pulmonary TB	Trans thoracic Lung biopsy (caseous necrosis)		Lung and bronchial Ca(FOB biopsy) (Squamo cell carcinoma)	To investigate metastase to find right supraclavicular lymph node (14day)	Died within first month TB treatment
64/F	House women	16 mm/2	Her relative TB (before 10 years)	TBLD Left axillar LN)	Lymph node biopsy (granulomatous inflammation with caseous necrosis)		Left Breast Ca (high grade invasive ductal carcinoma)	To investigate metastase to find left axillar lymphadenitis TB diagnosis (85day)	Treatment Completion
35/M	Driver	0 mm/1	Cigarette Smoker	Pulmonary TB	+ / + (Mycobacterium tuberculosis complex)	Sensitive to major drugs	Hypopharyngeal Ca (moderately differentiated Squamous cell carcinoma)	During medical therapy and radiotherapy(111 day)	Treatment Completion
42/M	Building worker	0 mm/1	Cigarette Smoker	Pulmonary TB	+ / + MOTT*(There wasn't type in the record)	No resistant to drugs testin the record)	Lung Ca (Squamous cell carcinoma)	Suspected inflammation in chest radiograph, (30 day)	Died within second month of TB treatment
43/M	Butcher	Absent	Cigarette Smoker	Pulmonary TB	+ / + (Mycobacterium tuberculosis complex)	No resistant to drugs testin the record)	Stomach Ca (Biopsy result was absent in the record)	Smear AFB positive during third chemotherapy (360 day)	Died within second month TB treatment (Liver metastases, membranous glomerulopathy
70/M	Retired	0 mm/1	Cigarette Smoker, COPD	Pulmonary TB	BAL - / + (Mycobacterium tuberculosis complex)	Absent resistant test to drugs	Prostate Ca (High grade urothelial carcinoma,)	Pulmonary inflammation in chest graphy during chemotherapy (5day)	Treatment Completion
52/M	Dental technician	Absent	Cigarette Smoker	Pulmonary TB	+ / + (Mycobacterium tuberculosis complex)	Sensitive to major drugs (HRZE)	Lung Ca (Neuroendocrin tumor)	During third cure chemotherapy(210 day)	Treatment Completion

(continued on next page)

Table 1 (continued)

Years M/F**	Occupation	TST/BCG*scar	Risk factors	TB localization	Sputum smear and culture, Biopsy results	Resistant test to drugs (AFB)	Histological type of lung cancer	TB diagnosis way and the latent time between onset of TB treatment and diagnosis of cancer (day)**	TB treatment result
80/F	House women	27 mm/0	Her husband TB (before 44 years)	Salivary gland TB	Lymph node biopsy (granulomatous inflammation with caseous necrosis)		Maxillary Ca(Squamous cell carcinoma)	Salivary gland biopsy considering metastase (176day)	Treatment Completion

List of Abbreviations: M: male, F: female, TST: Tuberculin skin test, BCG: Bacillus Calmette-Guerin, AFB: Acid Fast Bacille, BAL: Broncho alveolar lavage COPD: Chronic obstructive pulmonary disease, CVD: Serebro vascular disease, DM: Diabetes Mellitus, TBLN: Tuberculosis lymphadenitis. LN: Lymph node, TNF: Tumour Necrosis Factor, MOTT: Mycobacterium other than tuberculosis, MOTT(mycobacteria other than tuberculosis). *Cure is defined TB treatment result of pulmoner TB case with sputum smear AFB positive. TB Treatment: TB treatment complation and cure consisted of two months of HRZE plus 4 to 7 months of HR (H isovit, R rifampicin, E ethambutol, Z pyrazinamide (day)** the latent time between onset of TB treatment and diagnosis of cancer.

laboratory results (sputum smear microscopy, culture, sensitive test for mycobacterium tuberculosis, tuberculin skin test (TST), histopathology, the location of TB and cancer, the ways diagnosis of TB cases, risk factors, TB treatment results of cases from medical records of cases with the coexistence cancer and active TB. All registered patients were evaluated. This study was approved by The Department of Tuberculosis Control at Ministry of Health (number 147 Date 10/March/2015). Patient' informed consent was not required because of the study was retrospective.

3. Results

3.1. Case population

We recorded 374 TB cases in our dyspansery in this study period. In 16 (4%) of these cases was detected coexistent TB and cancer. There were twelve male and four female cases. The mean age was 62,12 ± 15,13 (35–87) years.

3.2. Case features

As shown in Table 1, there were ten pulmonary TB and six extra-pulmonary TB (four peripheral TB lymphadenopathy, one abdominal TB lymphadenopathy and one salivary gland TB) in cases with cancer. All TB cases were new cases. Acid fast bacilli (AFB) in sputum smear was found positive (conventional Ziehl-Neelsen (ZN) microscopy) in nine pulmonary TB cases while diagnosis of one pulmonary TB case was defined by histopathological examination for cultures, Löwenstein-Jensen (LJ) culture method have used. Type of mycobacteria were *Mycobacterium Tuberculosis complex* in seven cases and *Mycobacteria other than tuberculosis (MOTT)* in two case (in MOTT type of a case was *M. szulgai*, in other case there wasn't MOTT type in the medical record) There were drug susceptibility testing in four cases and sensitive to major drugs. There weren't drug susceptibility testing in other three cases in the records. There were TST results except three cases. Their TST (Mantoux test is used) results were between 0 mm and 27 mm. The diagnosis of extra-pulmonary TB cases were confirmed by histopathological examination. Cancer types were as follows; eight LC, two breast cancers, one base of tongue cancer, one endometrium cancer, one hypopharyngeal cancer, one stomach cancer, one bladder cancer and one maxillary cancer. There were six pulmonary TB and two peripheral TB lymphadenopathy in eight LC cases (Figs. 1 and 2), peripheral TB lymphadenopathy in two breast cancer cases, a salivary TB in maxillary cancer case, an abdominal TB lymphadenopathy in endometrium cancer and pulmonary TB in other cancer types. Diagnosis of all cases were confirmed by bacteriologic or histopathological examination. Histopathological aspects in cancers; squamous cell carcinoma was the most common type of cancers (9/16) and others were neuroendocrin tumor, high grade urothelial carcinomas, high grade invasive ductal carcinoma, pleomorphic carsinoma, Mullerian Tumor. There weren't histopathological results of two cancer cases in the medical record. The latent time between onset of TB treatment and diagnosis of cancer (biopsy date) were between 5–365 days in our study . Mean time were 90.37 days. The occupation of our cases were as follows; seven retired, three house women, one driver, one worker, one building worker, one butcher and one dental technician (see Table 1).

3.3. Risk factors

Risk factors for cancers are, cigarette smoking (tobacco and tobacco products), exposure to cancer-causing agents in the environment (sunlight, radon gas, air pollution, and infectious agents, exposure to cancer-causing agents in the workplace, genetic factors., Reactivation of latent TB infection (LTBI) may cause TB infection. The risk factors for activation of LTBI are HIV infection, patients using TNF-α inhibitors or corticosteroids, silicosis, apical fibrotic lesions, low weight, diabetes

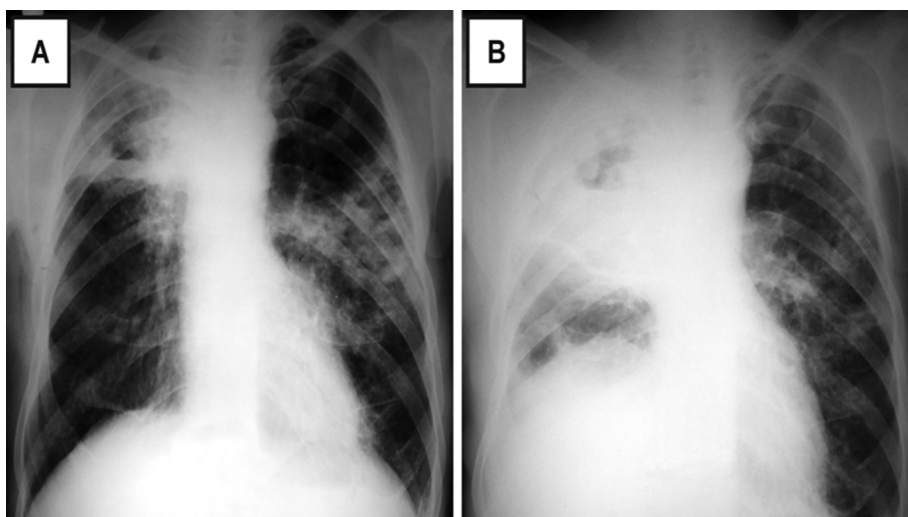


Fig. 1. A chest X-ray of 87 year -old male with squamous cell lung carcinoma. During fourth chemotherapy an infiltration was detected in left hemithorax. Sputum smear was positive for AFB. (A) Chest X ray during diagnosis of Pulmonary TB and (B) following for TB treatment.

mellitus, blood and lymph system cancers and jejunoileal bypass and organ transplantations. Our cases with coexistence active TB and cancer had cigarette smoking history in 9 case, TB family contact history in 4 case. The comorbid disorders were chronic obstructive pulmonary disease (COPD) in 1 case, hypertension in 1 case, cerebrovascular disease (CVD), diabetes mellitus (DM), renal failure, chronic viral hepatitis C in 1 case. There were no risk factors in two cases. Four cases were diagnosed TB after medical therapy and one case after radiotherapy.

3.4. TB treatment

TB treatment consisted of two months of HRZE (H: isoniazid, R: rifampicin, E: ethambutol, Z: pyrazinamide) plus 4 to 7 months of HR. Eleven TB cases completed TB treatment. Others died during TB treatment. There were two cases with *MOTT*. *M. szulgai* was identified in one sputum culture in a case, but other culture results were negative. The TB treatment regimen was changed. There was one case in the medical record who has liver metastases and membranous glomerulopathy died within second month TB treatment.

4. Discussion

The relationship between pulmonary TB and LC has been known for years. Pulmonary TB and LC are able to mimic each other sometimes with clinical and radiological features. The common symptoms were fever, night sweats, loss of appetite, weight loss, fatigue, chest pain.

Cancer cells invasion in healed TB lesions might also lead to TB reactivation by weakening the local immunity. Two diseases may be located in ipsilateral lung, contralateral lung or same lobe location. TB bacilli may live at a dormant status in granulomas and induce TB sensitivity [12]. If the local immunity is deteriorated, reactivation of a latent TB, primary mycobacterial infection, new exogenous infection may cause TB infection [13–16].

Chronic inflammation like pulmonary TB process that may lead to carcinogenesis of the lung tissue with leading to Deoxyribo Nucleic Acid (DNA) damage according to express nitric oxide synthase from infected macrophage, thus chronic inflammation and scarring due to TB can lead to the development of cancer [12,13]. The development of LC at the site of scars and old TB lesion infection was shown in the studies [1,11,14]. According to Harikrishna et al., [17] possible association between cancer and TB; by chance without any apparent relation, simultaneous development of both TB and cancer, metastatic carcinoma developing in an old TB scar, secondary TB infection in cancer. In our study, the cases with TB and cancer were found in ipsilateral or contralateral lung or extra-pulmonary regions. All tuberculosis cases new in our study. The discordant organ involvement may be by chance without any apparent relation. Smoking is an important risk factor for LC. Chemotherapy, immune dysfunction, radiotherapy, severely malnutrition may lead to immune-suppression. Radiotherapy might lead to granulomas microenvironment deregulation, allowing TB mycobacteria to proliferate [12,13]. The effects of radiation on the immune system are local tissue damage, peripheral depletion of lymphocytes and an

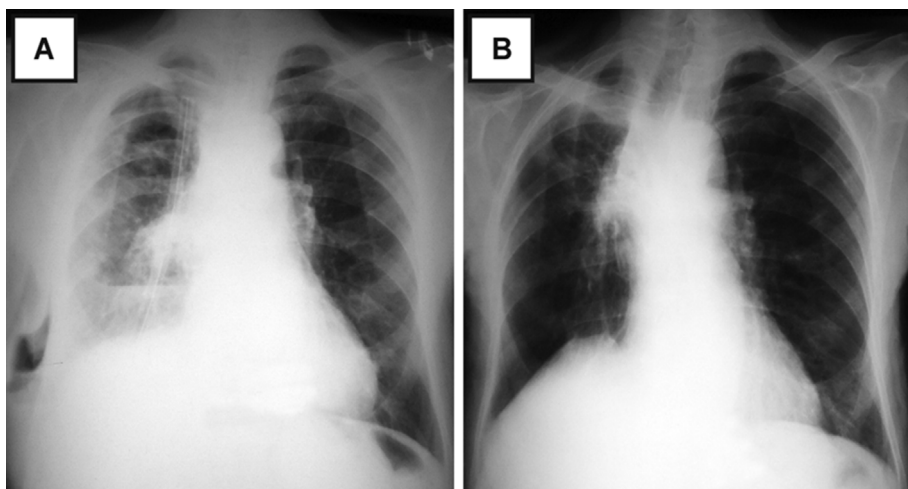


Fig. 2. A chest X-ray of 80 year-old male, showing a mass tumor in right lung. After bronchoscopy, a diagnosis of squamous cell lung carcinoma was achieved. An axillary lymph node was detected and biopsy was performed. Pathology of the biopsy showed granulomatous inflammation with caseous necrosis. (A) Chest X ray during diagnosis of TB and (B) following for TB treatment.

alteration in the immune cellular balance, namely, B cells, T cells, and natural killer cells [18].

In our study, risk factors were cigarette smoking, hypertension, DM, COPD, CVD, chronic viral hepatic C, chemotherapy, radiotherapy, TB family contact history. Lymphadenopathy in setting of TB and Lung cancer should be investigated carefully as lung cancer itself can cause granulomatous reaction and or tubercular lymphadenopathy can mimic like mets to LN radiographically. The lymph nodes due tuberculous lymphadenitis may lead to overstaging in TNM system. The biopsy specimens reveal infiltration by cancer cell, should also be sent to a microbiology laboratory to perform stain and culture for M tuberculosis [5]. The diagnosis ways of TB cases were suspected inflammation in chest radiograph during medical chemo therapy and radiotherapy or during regional lymph node biopsy to investigate for metastases.

Tuberculosis cases were diagnosed either same time or sequentially after cancer treatment. According to Wu et al. have reported an average 4 and 11 months delay in cancer diagnosis among TB patients [1]. We found 5–365 days in our study. Squamous cell carcinoma was the most common type of cancers. This rate was 9/16. Tamura et al. [12] analyzed clinical data on 25 cases with coexisting LC and active pulmonary tuberculosis and reported that the incidence of LC among patients with active pulmonary tuberculosis 0.7% while the incidence of active pulmonary tuberculosis in untreated LC g cancer patients 1.9%. Ventsiavichius et al. [19] found (2.1%) coexisting LC and tuberculosis that patients with LC who were opered, their histology were squamous-cell tumors in 52.2%, adenocarcinoma 21.7%, and adenosquamous-cell carcinomas 26.1%. Vencevicius et al. [20] 2.1% patients were diagnosed LC and tuberculosis-associated in pathology. Cicenias et al. [14] found same rate too. Kamboj et al. [21] showed that foreign-born patients with underlying hematologic neoplasm had a tuberculosis rate 50–100 times higher than United State-born patients. They suggested the initiation of latent tuberculosis infection therapy for those with a 5-mm induration. Matthew et al. [22] showed that patient with hematologic, head and neck, and LC had a 9-fold higher rate of developing active tuberculosis compared to those without cancer, latent tuberculosis screening and therapy be suggested in these cases. Our cases didn't use latent tuberculosis infection therapy when cancer was diagnosed. Kurasawa et al. [23] showed that coexistence of LC and pulmonary TB about 2–4% of LC and about 1–2% of TB. LC was more periphery origin and squamous cell carcinoma histopathologically. The lesions of LC and TB are mainly located in same lung, and sometimes in same lobe. Chen et al. [24] found epidermoid carcinoma a 64.5% of with coexisting pulmonary TB and LC. In our study, the coexistence of TB and cancer in TB patients was %4 and it was more in contrast to these previous reports. Squamous cell carcinoma was the most common type of cancers. Eleven TB cases completed TB treatment with out any complation, while five cases were died during TB treatment.

5. Conclusions

In our study, the coexistence of LC and pulmonary TB was more common. Squamous cell carcinoma was the most common type of cancers. The local immunity is deteriorated in cancer cases. If there is pulmonary infiltrates in lung or peripheral lymphadenopathy, we must search tuberculosis too out of metastatic lesion and other infectious diseases. We should not make delay in the diagnosis of active TB in cancer cases. Early TB diagnosis may extend median survival.

Financial disclosure

None declared.

Competing interests

None.

Acknowledgments

This study was no funded.

Appendix A. Supplementary data

Supplementary data related to this article can be found at <http://dx.doi.org/10.1016/j.rmcr.2017.11.004>.

References

- [1] C.Y. Wu, H.Y. Hu, C.Y. Pu, N. Huang, H.C. Shen, C.P. Li, Y.J. Chou, Pulmonary tuberculosis increases the risk of lung cancer: a population-based cohort study, *Cancer* 117 (2011) 618–624.
- [2] C.R. Horsburgh Jr., C.E. Barry 3rd, C. Lange, Treatment of tuberculosis, *N. Engl. J. Med.* 373 (22) (2015) 2149–2160 26.
- [3] W.W. Lin, M. Karin, A cytokine-mediated link between innate immunity, inflammation, and cancer, *J. Clin. Investig.* 117 (5) (2007) 1175–1183.
- [4] B.M. Saunders, W.J. Britton, Life and death in the granuloma: immunopathology of tuberculosis, *Immunol. Cell Biol.* 85 (2) (2007) 103–111.
- [5] M.E. Falagas, V.D. Kouranos, Z. Athanassa, P. Kopterides, Tuberculosis and malignancy, *Q. J. Med.* 103 (2010) 461–487.
- [6] S. Ballaz, J.L. Mulshine, The potential contributions of chronic inflammation to lung carcinogenesis, *Clin. Lung Cancer* 5 (2003) 46–62.
- [7] S.I. Cha, K.M. Shin, J.W. Lee, S.Y. Lee, C.H. Kim, J.Y. Park, T.H. Jung, The clinical course of respiratory tuberculosis in lung cancer patients, *Int. J. Tuberc. Pulm. Dis.* 13 (8) (2009) 1002–1007.
- [8] M. Sakuraba, M. Hirama, A. Hebisawa, Y. Sagara, A. Tamura, H. Komatsu, Coexistent Lung carcinoma and active pulmonary tuberculosis in the same lobe, *Ann. Thorac. Cardiovasc Surg.* 12 (1) (2006) 53–55.
- [9] E.A. Engels, M. Shen, R.S. Chapman, R.M. Pfeiffer, Y.Y. Yu, X. He, Q. Lan, Tuberculosis and subsequent risk of Lung cancer in Xuanwei, China *Int. J. Cancer* 124 (5) (2009) 1183–1187 1.
- [10] World Health organization. Global tuberculosis report. 2016. Available at http://who.int/tb/publications/global_report/en/.
- [11] WHO, WHO list of priority medical devices for cancer management, (2017), pp. 9–10 ISBN: 978-92-4-156546-2.
- [12] A. Tamura, A. Hebisawa, K. Hayashi, Y. Sagara, Y. Kawabe, N. Nagayama, K. Machida, K. Fukushima, H. Yotsumoto, M. Mori, Lung cancer in patients who had received thoracoplasty for pulmonary tuberculosis, *Jpn. J. Clin. Oncol.* 29 (11) (1999) 541–545.
- [13] D. Karnak, O. Kayacan, S. Beder, Reactivation of pulmonary tuberculosis in malignancy, *Tumori* 88 (2002) 251–254.
- [14] S. Cicenias, V. Vencevicius, Lung cancer in patients with tuberculosis, *World J. Surg. Oncol.* 5 (2007) 22.
- [15] R.E. Jacobs, P. Gu, A. Chachoua, Reactivation of pulmonary tuberculosis during cancer treatment, *Int. J. Mycobacteriol.* 4 (4) (2015) 337–340.
- [16] A. Christopoulos, M.W. Saif, E.G. Sarris, K.N. Syrigos, Epidemiology of active tuberculosis in lung cancer patients: a systematic review, *Clin. Respir. J.* 8 (4) (2014) 375–381.
- [17] J. Harikrishna, V. Sukaveni, D.P. Kumar, Cancer and tuberculosis, *J. Indian Acad. Clin.* 13 (2) (2012) 142–144.
- [18] Ramon E.A. Jacobsa, Reactivation of pulmonary tuberculosis during cancer treatment, *Int. J. Mycobacteriol.* 4 (4) (2015) 337–340 (2015).
- [19] V. Ventsiavichius, S. Tsitsenas, R. Tikuishis, Potentialities of surgical treatment for concomitance of pulmonary tuberculosis and lung cancer, *Probl. Tuberk. Bolezn. Legk.* 5 (2007) 32–36.
- [20] V. Vencevicius, S. Cicenias, P. Miliauskas, Surgical treatment of Lung carcinoma in tuberculosis patients, *Med. Kaunas* 40 (12) (2004) 1170–1174.
- [21] M. Kamboj, K.A. Sepkowitz, The risk of tuberculosis in patients with cancer, *Clin. Infect. Dis.* 42 (11) (2006) 1592–1595.
- [22] P. Matthew, Cheng, Risk of active tuberculosis in patients with cancer: a systematic review and metaanalysis, *Clin. Infect. Dis.* 64 (5) (2017) 635–644.
- [23] T. Kurasawa, The coexistence of pulmonary tuberculosis and lung cancer, *Nihon Rinsho* 56 (12) (1998) 3167–3170.
- [24] Y.M. Chen, J.Y. Chao, C.M. Tsai, P.Y. Lee, R.P. Perng, Shortened survival of lung cancer patients initially presenting with pulmonary tuberculosis, *Jpn. J. Clin. Oncol.* 26 (5) (1996) 322–327.