








Original Article



How Long Can the Next Intervention Be Delayed after Balloon Dilatation of Homograft in the Pulmonary Position?

Hye-In Jeong , MD¹, Jinyoung Song , MD, PhD¹, Eun Young Choi , MD²,
Sung Ho Kim, MD², Jun Huh , MD¹, I-Seok Kang , MD¹, Ji Hyuk Yang , MD³,
and Tae Gook Jun , MD³

¹Department of Pediatrics, Samsung Medical Center, Sungkyunkwan University School of Medicine, Seoul, Korea

²Department of Pediatrics, Sejong General Hospital, Bucheon, Korea

³Department of Thoracic Surgery, Samsung Medical Center, Sungkyunkwan University School of Medicine, Seoul, Korea

OPEN ACCESS

Received: Feb 28, 2017

Revised: Apr 11, 2017

Accepted: May 31, 2017

Correspondence to

Jinyoung Song, MD, PhD

Department of Pediatrics, Samsung Medical Center, Sungkyunkwan University School of Medicine, 81, Irwon-ro, Gangnam-gu, Seoul 06351, Korea.

Tel: +82-2-3410-3539

Fax: +82-2-3410-0043

E-mail: amyjys@naver.com


Copyright © 2017. The Korean Society of Cardiology

This is an Open Access article distributed under the terms of the Creative Commons Attribution Non-Commercial License (<https://creativecommons.org/licenses/by-nc/4.0>) which permits unrestricted noncommercial use, distribution, and reproduction in any medium, provided the original work is properly cited.

ORCID iDs

Hye-In Jeong 


<https://orcid.org/0000-0001-8843-0651>

Jinyoung Song 

<https://orcid.org/0000-0002-9660-5949>

Eun Young Choi 


<https://orcid.org/0000-0001-5936-9388>

Jun Huh 

<https://orcid.org/0000-0003-4523-9632>

I-Seok Kang 

<https://orcid.org/0000-0003-4264-0826>

Ji Hyuk Yang 

<https://orcid.org/0000-0002-7349-6778>

Tae Gook Jun 

<https://orcid.org/0000-0002-5161-4665>

ABSTRACT

Background and Objectives: We investigated the effectiveness of balloon dilatation of homograft conduits in the pulmonary position in delaying surgical replacement.

Subjects and Methods: We reviewed the medical records of patients who underwent balloon dilatation of their homograft in the pulmonary position from 2001 to 2015. The pressure gradient and ratio of right ventricular pressure were measured before and after the procedure. The primary goal of this study was to evaluate the parameters associated with the interval to next surgical or catheter intervention.

Results: Twenty-eight balloon dilations were performed in 26 patients. The median ages of patients with homograft insertion and balloon dilatation were 20.3 months and 4.5 years, respectively. The origins of the homografts were the aorta (53.6%), pulmonary artery (32.1%), and femoral vein (14.3%). The median interval after conduit implantation was 26.7 months. The mean ratio of balloon to graft size was 0.87. The pressure gradient through the homograft and the ratio of right ventricle to aorta pressure were significantly improved after balloon dilatation ($p < 0.001$). There were no adverse events during the procedure with the exception of one case of balloon rupture. The median interval to next intervention was 12.9 months. The median interval of freedom from re-intervention was 16.6 months. Cox proportional hazards analysis revealed that the interval of freedom from re-intervention differed only according to origin of the homograft ($p = 0.032$), with the pulmonary artery having the longest interval of freedom from re-intervention ($p = 0.043$).

Conclusion: Balloon dilatation of homografts in the pulmonary position can be safely performed, and homografts of the pulmonary artery are associated with a longer interval to re-intervention.

Keywords: Allografts; Angioplasty, balloon; Pulmonary valve stenosis; Re-intervention

INTRODUCTION

Right ventricular outflow tract reconstruction with a homograft conduit has been widely used for over 30 years.¹⁾ Congenital heart disease with pulmonary atresia and truncus arteriosus are typical diseases that require a homograft conduit at an early age. The short-term results of

Conflict of Interest

The authors have no financial conflicts of interest.

Author Contributions

Conceptualization: Song J, Huh J, Kang IS, Yang JH, Jun TG; Data curation: Jeong HI, Choi EY, Kim SH; Formal analysis: Song J; Investigation: Jeong HI, Song J; Methodology: Jeong HI, Song J; Project administration: Song J; Software: Song J; Supervision: Song J; Validation: Huh J, Kang IS, Yang JH, Jun TG; Visualization: Huh J, Kang IS, Yang JH, Jun TG; Writing - original draft: Jeong HI, Song J; Writing - review & editing: Song J, Huh J, Kang IS, Yang JH, Jun TG.

homograft conduits are excellent, but stenosis is both an inevitable outcome and the primary indication for subsequent surgical re-intervention.²⁾³⁾ This stenosis, exacerbated by calcification, might be accelerated in the pediatric population despite various preservation techniques.⁴⁾⁵⁾ Although the most effective alternate palliation is conduit replacement, there have been various efforts to reduce the risk associated with repetitive replacements, such as balloon dilatation, stent implantation, and percutaneous pulmonary valve implantation.⁶⁾¹²⁾ The effect of balloon dilatation of homografts in the pulmonary position in congenital heart disease is controversial due to the difficulty in defining efficacy and the small size of published studies. Some studies have reported that balloon dilatation fails to prolong homograft life and recommend abandoning balloon dilatation of homograft conduits.²⁾³⁾⁶⁾¹³⁾ However, recent retrospective studies have concluded that balloon dilatation of homograft conduits in the pulmonary position has a favorable effect.⁷⁾⁸⁾ Balloon dilatation of homografts in children or adolescents can postpone surgical valve or percutaneous valve implantation by 1 or 2 years, reducing the overall number of valve replacements needed. Accordingly, we retrospectively reviewed our experience to determine whether balloon dilatation is associated with postponement of conduit replacement.

SUBJECTS AND METHODS

We retrospectively reviewed the medical records of all patients who underwent balloon dilatation of a homograft in the pulmonary position at Samsung Medical Center or Sejong General Hospital from January 2001 to December 2015. Patients with medical records lacking hemodynamic data or without follow-up were excluded. Patient demographics, cardiac diagnoses, catheter intervention records (including hemodynamic data), and surgical records were obtained. The time of homograft conduit insertion, balloon dilatation, and subsequent intervention such as balloon dilatation, stent insertion, or conduit change were recorded, and the intervals between each event were calculated.

The decision for cardiac catheterization was based on echocardiographic evaluation and the patient's clinical condition. Balloon dilatation was performed by a cardiac interventionist specializing in congenital heart disease, and the decision to perform the procedure was based not only on pressure differences through homograft conduit stenosis and right ventricular pressure compared to descending aortic pressure, but also on the degree of calcification. A conventional balloon was chosen by the interventionist according to the conduit size described in the surgical record. A double balloon technique was chosen when the available balloon was limited. A standard balloon angioplasty technique was used as described previously,¹⁴⁾¹⁵⁾ and pressures before and after balloon dilatation were measured.

Two-dimensional (2D) echocardiography was performed the day after the procedure, and routine echocardiographic follow-up was maintained after discharge. Future interventions were decided after discussion with surgeons. The last follow-up date was the date of the following intervention or the last hospital visit.

We arbitrarily defined a favorable result after balloon dilatation as postponement of the next intervention to 24 months or later and investigated differences between patients divided according to time to next intervention (less than 24 months vs. greater than 24 months).

Statistical analyses were performed using SPSS 23.0 (IBM Corp., Armonk, NY, USA). The mean, median, standard deviation, and range were calculated for continuous variables.

Frequencies were calculated for nominal variables. Changes after balloon dilatation were compared with the Wilcoxon signed rank test. Kaplan-Meier curves were used to analyze freedom from re-intervention. Cox proportional hazard model was used to identify risk factors for early re-intervention. The log-rank method was used to compare Kaplan-Meier curves of the 2 groups. The time to the following intervention was compared using the Mann-Whitney U test. Values of $p < 0.050$ were considered statistically significant. The institutional review board approved this study, and the requirement for consent from patients or parents was waived.

RESULTS

Twenty-eight balloon dilatations were performed in 26 patients, 16 of whom were male. The original diagnoses included pulmonary atresia/ventricular septal defect ($n=9$), truncus arteriosus ($n=5$), Ross operation ($n=6$), tetralogy of Fallot ($n=3$), transposition of the great arteries/pulmonary stenosis ($n=3$), pulmonary atresia without ventricular septal defect ($n=1$), and congenitally corrected transposition of the great arteries/pulmonary stenosis ($n=1$). The origins of the homograft were the aorta ($n=15$), pulmonary artery ($n=9$), and femoral vein ($n=4$). The median ages at conduit insertion and balloon dilatation were 20.3 (0.4–557.0) months and 4.5 (0.6–53.3) years, respectively. The median interval from conduit insertion to balloon dilatation was 26.7 (3.3–137.4) months, and the interval to next intervention from balloon dilatation was 12.9 (0.1–100.0) months. Conduit size ranged from 9 mm to 25 mm (median 15 mm). The median follow-up period after balloon dilatation was 12.6 months, and subsequent intervention such as surgical or balloon intervention was confirmed in 25 cases.

A second trial was performed in 2 patients, and a double balloon was used in 1 trial. There was 1 case of balloon rupture in 1 trial, but there were no serious complications. The hemodynamic data before and after balloon dilatation are summarized in **Table 1**. The pressure difference through the stenotic conduit and the ratio of right ventricle to aorta pressure were both significantly improved after balloon dilatation ($p < 0.001$). The median period of freedom from re-intervention was 16.6 months (**Figure 1**). Cox regression analysis showed that homograft type was a unique risk factor of decreased period of freedom from re-intervention (**Table 2**). However, pressure differences, right ventricle pressure ratio, balloon size to conduit diameter ratio, interval from homograft insertion, and conduit size were not significant risk factors. The median period of freedom from re-intervention was 37.6 months for pulmonary artery homografts, 18.7 months for aorta homografts, and 1.3 months for femoral vein homografts ($p=0.043$) (**Figure 2**).

Table 1. Patient characteristics according to balloon dilatation of homografts

Characteristic	Before balloon	After balloon	p value
Age at conduit insertion (months)	20.3 (0.4–557.0)	-	-
Age at ballooning (years)	4.54 (0.58–53.33)	-	-
Interval from conduit insertion (months)	26.7 (3.3–137.4)	-	-
Interval to next intervention (months)	-	12.9 (0.1–100.0)	-
F/u interval (months)	-	12.6 (0.1–100.0)	-
Conduit size (mm)	15 (9–25)	-	-
Size ratio (balloon/conduit)	0.87±0.19 (0.56–1.18)	-	-
Pressure ratio (RV/Ao)	0.82±0.17 (0.53–1.16)	0.66±0.19 (0.30–1.16)	<0.001
dP (mmHg)	53.89±14.55 (20.0–92.0)	37.43±17.57 (8.0–76.0)	<0.001

Ao = aorta; dP = pressure difference; F/u = follow-up; RV = right ventricle.

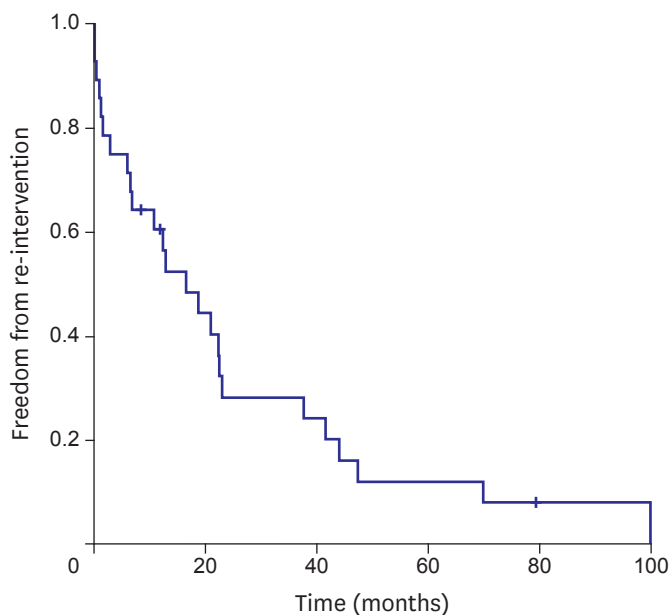


Figure 1. Freedom from re-intervention after balloon dilatation of homografts.

In cases of favorable result after balloon dilatation as defined above, the pressure ratio of the right ventricle to the aorta before balloon dilatation was significantly lower than in other cases. Age of conduit operation, interval from conduit surgery to balloon dilatation, pressure difference before balloon dilatation, and size ratio of balloon to conduit were not different between patients with favorable results and other patients (Table 3).

DISCUSSION

Based on our findings, balloon dilatation of homograft conduits in the pulmonary position led to postponement of valve replacement, with the greatest benefit seen with pulmonary artery homografts. While the interval in some cases was small, reducing the number of repetitive cardiac surgeries or postponing a subsequent surgery is a worthwhile goal, especially for pediatric patients, because surgical conduit revision is associated with increased risk of mortality.¹⁶⁾ Percutaneous pulmonary valve implantation represents a possible alternative, but is not currently available in many areas.

Table 2. Relative risk by Cox proportional hazards model

Variable in the equation	B	SE	Wald	Sig	Exp (B)	95% CI for Exp (B)	
						Lower	Upper
dP before balloon	0.030	0.035	0.739	0.390	1.030	0.963	1.102
PR (RV/Ao) before balloon	1.918	2.941	0.425	0.514	6.806	0.021	2,167.277
Conduit size	-0.099	0.145	0.469	0.493	0.905	0.681	1.203
Size ratio (balloon/conduit)	1.971	1.411	1.951	0.162	7.178	0.452	114.057
Homograft type (femoral)	-	-	4.966	0.083	-	-	-
Homograft type (pulmonary)	-1.929	0.902	4.572	0.032	0.145	0.025	0.851
Age at conduit insertion	-0.002	0.004	0.203	0.652	0.998	0.992	1.005
Interval from conduit insertion	-0.003	0.012	0.053	0.818	0.997	0.975	1.020

Ao = aorta; CI = confidence interval; dP = pressure difference; PR = pulmonary regurgitation; RV = right ventricle; SE = standard error.

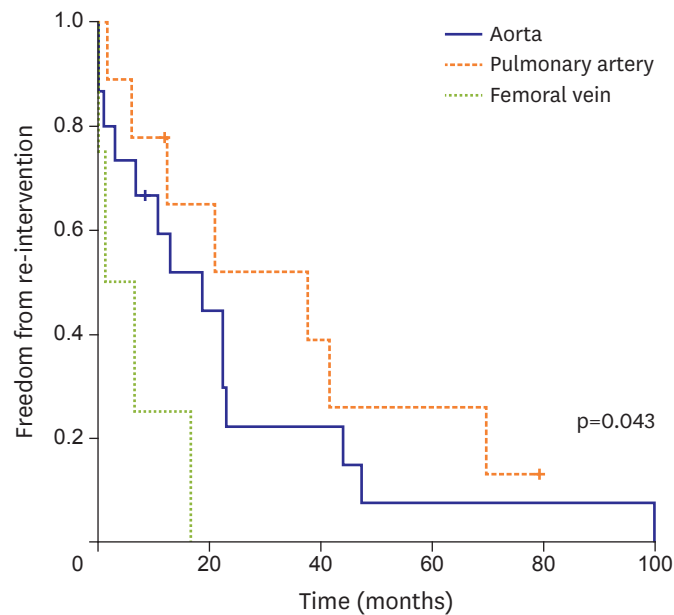


Figure 2. Differences in freedom from re-intervention according to type of homograft; aorta, pulmonary artery and femoral vein.

Sanatani et al.⁶ concluded that balloon dilatation of homograft conduits is not recommended due to the very limited and only transient benefit observed in a small series of patients. However, despite the small number of patients in their study, the next operation was postponed in a majority of patients. The transient effect of balloon dilatation reported in their study was verified by echocardiography; however, pressures measured by Doppler and catheterization can differ significantly. It is also important to note that the majority of conduits in their study were aortic homografts; however, pulmonary homografts are known to last longer than aortic homografts.⁴⁾⁵⁾¹⁷⁾¹⁹⁾ Consistently, we found that balloon dilatation in pulmonary homografts provided better results than aortic or femoral vein homografts, although the reasons behind these differences are not entirely clear. Bertels et al.⁷ reported favorable effects after balloon dilatation of homografts, but could not identify any significant factors predictive of a favorable effect. Powell et al.¹⁰ proposed that absence of calcification and younger conduit age are factors associated with better results. While our definition of a 24-month delay to re-intervention after ballooning as a favorable result was both subjective and arbitrary, a total of one-third of our patients met this criteria. Thus, we considered it meaningful to compare patients with favorable results to other patients. The group with favorable results after balloon dilatation had a longer interval from conduit insertion, although the difference was not significant (27.0 months vs. 22.3 months), which was

Table 3. Differences in patients who received re-intervention after balloon dilatation based on a 24-month re-intervention threshold

Re-intervention	After 24 months	Before 24 months	p value
No. of patients	9	19	-
Age at conduit insertion (months)	30.6 (1.0–173.9)	15.8 (0.4–557.0)	0.357
Age at ballooning (years)	6.4 (2.3–16.3)	3.3 (0.6–53.3)	0.243
Pre-balloon dP (mmHg)	47.0±10.5	54.2±15.8	0.243
Pre-balloon (RV/Ao)	0.72±0.10	0.87±0.18	0.042
Size ratio (balloon/conduit)	0.90±0.19	0.86±0.19	0.562
Interval from conduit insertion (months)	27.0 (13.5–137.4)	22.3 (3.3–83.1)	0.498

Ao = aorta; dP = pressure difference; RV = right ventricle.

similar to Bertels et al.'s findings.⁷⁾ We also did not evaluate calcification in our study, as this parameter is difficult to quantify.

In cases of bioprosthetic valves in the pulmonary position, balloons with the same diameter as the valve are recommended for dilatation.¹⁵⁾ Balloon size compared to conduit size was not a factor associated with good outcomes in our study, consistent with the results of previous studies.⁶⁾⁷⁾²⁰⁾ Balloon pressure rather than balloon size might be important, because good results have been reported with ultra-noncompliant balloons for angioplasty of homografts.⁸⁾ We used both high pressure and conventional balloons because of limited availability. Specifically, we were concerned about conduit rupture in cases with high pressure or using large balloons based on case reports of conduit rupture requiring urgent surgery.⁷⁾⁸⁾

Based on length of time to the next intervention after balloon dilatation, femoral vein homografts were associated with the worst outcomes in our study. The reasons for this result are not clear, but femoral vein homografts tended to be used in small patients because of the smaller size of the homografts. Rapid somatic growth in patients compared to static conduits and subsequent rapid calcification could also explain the worse outcomes associated with femoral vein homograft.

Relatively early balloon dilatation at a lower right ventricular pressure compared to systemic pressure was an important factor for better outcome, defined as delayed re-intervention in our study. Although the difference did not reach the level of significance, the pressure gradient over conduits was also lower in the patient group with a good outcome. Due to different clinical objectives for each case, our criteria (postponement of 24 months) should be considered as only one possible outcome. However, the period of freedom from re-intervention in this study was similar to that of another study.⁷⁾

There were several limitations to this study. First, a retrospective review does not have the statistical strength of a randomized control study. In addition, the indications for balloon dilatation were not applied uniformly to all patients with homograft conduits. Based on our standard practice, a maximal pressure gradient over the conduit greater than 50 mmHg was an indication for catheterization, while a similar pressure gradient or a ratio of right ventricle to aorta pressure greater than 0.65 was used as an indication for balloon dilatation.²¹⁾ However, it was the interventionist who ultimately decided on balloon dilatation in each case after considering not only hemodynamic data, but also the degree of calcification and conduit size compared to somatic size, among other criteria. Another limitation of this study was that the time to re-intervention could have been biased by previous interventions other than those used as indications for intervention. We also did not document the impact on pulmonary regurgitation after balloon dilatation because it was difficult to quantify the amount of regurgitation in cases of severe stenosis. Right ventricular function was not evaluated for the same reason. Finally, the small number of patients in our study made it challenging to draw conclusions about the effect of balloon dilatation on postponing valve replacement. In the future, well controlled studies comprising a larger patient series will be useful for determining the optimal timing for balloon dilatation of homograft conduits in the pulmonary position.

In conclusion, based on our retrospective analysis of a small series of patients, balloon dilatation of homograft conduits in the pulmonary position appeared safe and had a limited effect on postponement of the next re-intervention. The longest delays to re-intervention

occurred with pulmonary homografts, and a relatively lower right ventricle/aorta pressure ratio was associated with a better outcome, as defined by postponement of the next re-intervention.

REFERENCES

1. Ross DN, Somerville J. Correction of pulmonary atresia with a homograft aortic valve. *Lancet* 1966;2:1446-7.
[PUBMED](#) | [CROSSREF](#)
2. Tatebe S, Nagakura S, Boyle EM Jr, Duncan BW. Right ventricle to pulmonary artery reconstruction using a valved homograft. *Circ J* 2003;67:906-12.
[PUBMED](#) | [CROSSREF](#)
3. Oosterhof T, Meijboom FJ, Vliegen HW, et al. Long-term follow-up of homograft function after pulmonary valve replacement in patients with tetralogy of Fallot. *Eur Heart J* 2006;27:1478-84.
[PUBMED](#) | [CROSSREF](#)
4. Saravalli OA, Somerville J, Jefferson KE. Calcification of aortic homografts used for reconstruction of the right ventricular outflow tract. *J Thorac Cardiovasc Surg* 1980;80:909-20.
[PUBMED](#)
5. Yankah AC, Alexi-Meskishvili V, Weng Y, Schorn K, Lange PE, Hetzer R. Accelerated degeneration of allografts in the first two years of life. *Ann Thorac Surg* 1995;60:S71-6.
6. Sanatani S, Potts JE, Human DG, Sandor GG, Patterson MW, Gordon Culham JA. Balloon angioplasty of right ventricular outflow tract conduits. *Pediatr Cardiol* 2001;22:228-32.
[PUBMED](#) | [CROSSREF](#)
7. Bertels RA, Dalinghaus M, Witsenburg M, et al. Results of balloon dilatation of stenotic homografts in pulmonary position in children and young adults. *Cardiol Young* 2012;22:589-95.
[PUBMED](#) | [CROSSREF](#)
8. Hainstock MR, Marshall AC, Lock JE, McElhinney DB. Angioplasty of obstructed homograft conduits in the right ventricular outflow tract with ultra-noncompliant balloons: assessment of therapeutic efficacy and conduit tears. *Circ Cardiovasc Interv* 2013;6:671-9.
[PUBMED](#) | [CROSSREF](#)
9. Peng LF, McElhinney DB, Nugent AW, et al. Endovascular stenting of obstructed right ventricle-to-pulmonary artery conduits: a 15-year experience. *Circulation* 2006;113:2598-605.
[PUBMED](#) | [CROSSREF](#)
10. Powell AJ, Lock JE, Keane JF, Perry SB. Prolongation of RV-PA conduit life span by percutaneous stent implantation. Intermediate-term results. *Circulation* 1995;92:3282-8.
[PUBMED](#) | [CROSSREF](#)
11. McElhinney DB, Hellenbrand WE, Zahn EM, et al. Short- and medium-term outcomes after transcatheter pulmonary valve placement in the expanded multicenter US melody valve trial. *Circulation* 2010;122:507-16.
[PUBMED](#) | [CROSSREF](#)
12. Sreeram N, Hutter P, Silove E. Sustained high pressure double balloon angioplasty of calcified conduits. *Heart* 1999;81:162-5.
[PUBMED](#) | [CROSSREF](#)
13. Böhm JO, Botha CA, Horke A, et al. Is the Ross operation still an acceptable option in children and adolescents? *Ann Thorac Surg* 2006;82:940-7.
[PUBMED](#) | [CROSSREF](#)
14. Lloyd TR, Marvin WJ Jr, Mahoney LT, Lauer RM. Balloon dilation valvuloplasty of bioprosthetic valves in extracardiac conduits. *Am Heart J* 1987;114:268-74.
[PUBMED](#) | [CROSSREF](#)
15. Waldman JD, Schoen FJ, Kirkpatrick SE, Mathewson JW, George L, Lamberti JJ. Balloon dilatation of porcine bioprosthetic valves in the pulmonary position. *Circulation* 1987;76:109-14.
[PUBMED](#) | [CROSSREF](#)
16. LeBlanc JG, Russell JL, Sett SS, Potts JE. Intermediate follow-up of right ventricular outflow tract reconstruction with allograft conduits. *Ann Thorac Surg* 1998;66:S174-8.
[PUBMED](#) | [CROSSREF](#)
17. Albert JD, Bishop DA, Fullerton DA, Campbell DN, Clarke DR. Conduit reconstruction of the right ventricular outflow tract. Lessons learned in a twelve-year experience. *J Thorac Cardiovasc Surg* 1993;106:228-35.
[PUBMED](#)

18. McGrath LB, Gonzalez-Lavin L, Graf D. Pulmonary homograft implantation for ventricular outflow tract reconstruction: early phase results. *Ann Thorac Surg* 1988;45:273-7.
[PUBMED](#) | [CROSSREF](#)
19. Bando K, Danielson GK, Schaff HV, Mair DD, Julsrud PR, Puga FJ. Outcome of pulmonary and aortic homografts for right ventricular outflow tract reconstruction. *J Thorac Cardiovasc Surg* 1995;109:509-17.
[PUBMED](#) | [CROSSREF](#)
20. Zeevi B, Keane JF, Perry SB, Lock JE. Balloon dilation of postoperative right ventricular outflow obstructions. *J Am Coll Cardiol* 1989;14:401-8.
[PUBMED](#) | [CROSSREF](#)
21. Aggarwal S, Garekar S, Forbes TJ, Turner DR. Is stent placement effective for palliation of right ventricle to pulmonary artery conduit stenosis? *J Am Coll Cardiol* 2007;49:480-4.
[PUBMED](#) | [CROSSREF](#)