



Percutaneous Electromagnetic Transthoracic Nodule Localization for Ground Glass Nodules

Seung Hwan Song, M.D.¹, Hyun Soo Lee, M.D.², Duk Hwan Moon, M.D.², Sungsoo Lee, M.D., Ph.D.²

¹Department of Thoracic and Cardiovascular Surgery, Sanggye Paik Hospital, Inje University College of Medicine; ²Department of Thoracic Surgery, Gangnam Severance Hospital, Yonsei University College of Medicine, Seoul, Korea

ARTICLE INFO

Received April 26, 2021

Revised October 6, 2021

Accepted October 19, 2021

Corresponding author

Sungsoo Lee

Tel 82-2-2019-3381

Fax 82-2-3461-8282

E-mail chestlee@yuhs.ac

ORCID

<https://orcid.org/0000-0001-8998-9510>

Background: A recent increase in the incidental detection of ground glass nodules (GGNs) has created a need for improved diagnostic accuracy in screening for malignancies. However, surgical diagnosis remains challenging, especially via video-assisted thoracoscopic surgery (VATS). Herein, we present the efficacy of a novel electrical navigation system for perioperative percutaneous transthoracic nodule localization.

Methods: Eighteen patients with GGNs who underwent electromagnetic navigated percutaneous transthoracic needle localization (ETTNL), followed by 1-stage diagnostic wedge resections via VATS between January and December 2020, were included in the analysis. Data on patient characteristics, nodules, procedures, and pathological diagnoses were collected and retrospectively reviewed.

Results: Of the 18 nodules, 17 were successfully localized. Nine nodules were pure GGNs, and the remaining 9 were part-solid GGNs. The median nodule size was 9.0 mm (range, 4.0–20.0 mm); and the median depth from the visceral pleura was 5.2 mm (range, 0.0–14.4 mm). The median procedure time was 10 minutes (range, 7–20 minutes). The final pathologic results showed benign lesions in 3 cases and malignant lesions in 15 cases.

Conclusion: Perioperative ETTNL appears to be an effective method for the localization of GGNs, providing guidance for a 1-stage VATS procedure.

Keywords: Ground glass nodule, Percutaneous localization, Electromagnetic bronchoscopy, Transthoracic localization

Introduction

In recent years, computed tomography (CT) has been increasingly used to screen high-risk patients for lung cancer. Widespread CT screening has led to an increased number of incidental detections of small pulmonary nodules (PNs), including ground glass nodules (GGNs). A significant proportion of these cases may be malignant [1,2]. Therefore, an accurate and definitive histologic diagnosis is essential. However, resection of GGNs or PNs, especially using video-assisted thoracoscopic surgery (VATS), is a challenging task [3,4]. To address this problem, perioperative localization can be used as a helpful method for achieving successful resection.

Several conventional methods are currently used to localize PNs. Most methods require either CT or fluoroscop-

ic guidance, using a hookwire, dye, microcoil, fiducial marker, or radiotracer [5]. Although these methods have been widely used, they are associated with several complications, including pneumothorax, bleeding, dislodgement or migration of markers, and dye diffusion [5].

A new, electromagnetic navigation bronchoscopy (ENB)-guided percutaneous transthoracic approach has recently been introduced to localize PNs [6,7]. Unlike the conventional ENB-guided method, this new approach uses an intraoperative electromagnetic tracking sensor for percutaneous transthoracic localization. In this study, we assessed the efficacy of the intraoperative electromagnetic navigated percutaneous transthoracic needle localization (ETTNL) method.



Methods

Patient selection and retrospective review

A retrospective electronic chart review was performed for all patients who underwent intraoperative ETTNL using the SPiN Perc (Veran Medical Technologies, St. Louis, MO, USA) between January and December 2020 at Gangnam Severance Hospital. Patient data, such as demographics, imaging studies, details of surgery, pathological information, and details of the postoperative course were collected for review. This study was conducted in accordance with the Declaration of Helsinki (revised in 2013) and was approved by the Institutional Review Board of Gangnam Severance Hospital (approval no., 3-2020-0419). Informed consent was obtained from all participants.

Indications

Patients who had pure or part-solid GGNs that were observed for longer than 3 months underwent the ETTNL procedure, regardless of nodule size. Patients with solid nodules were excluded from the study.

Nodule localization procedure

All patients underwent preoperative chest CT (1) to obtain baseline inspiration and expiration images and (2) to create virtual airway images after attaching a navigational tracking pad to the patient's chest. Based on the location of the lesion, the patient was placed in either the supine or lateral decubitus position. These images were saved in the Digital Imaging and Communications in Medicine format

and transferred to dedicated software (SPiNDrive/Perc; Veran Medical Technologies). After the target lesion was identified by the software, the registration process was performed to create a virtual airway map under ENB guidance after general anesthesia in the operating room. The patient was intubated with a single lumen endotracheal tube during the registration phase. Thereafter, a navigational pathway from the entry point of the skin to the target lesion was created. Upon completion of the registration process, the ENB was removed, and the patient's chest was prepared and draped using a sterile technique at the determined entry site. A 19G Chiba electromagnetic real-time tracking needle was introduced with navigational guidance during the expiration breathing phase. When the needle reached the distal margin of the target lesion, the tracking sensor in the inner cannula was removed, and dye (methylene blue) was injected for marking (Figs. 1, 2). In 5 cases, a microcoil was used for dual localization. Using the same 19G Chiba needle cannula, the microcoil was deployed before dye injection [6,7].

Surgical procedure

The ETTNL system was removed after lesion marking. The endotracheal tube was changed from a single lumen to a double lumen. The patient was positioned and then prepared and draped for surgery using a sterile technique. Two expert surgeons performed the surgical procedure via VATS. A thoracoscope was inserted under 1-lung ventilation, and the lung was carefully inspected to identify the target lesion. In patients with dual localization, the lesion was identified either by dye or by using C-arm fluoroscopy guidance. The target lesion was resected via diagnostic

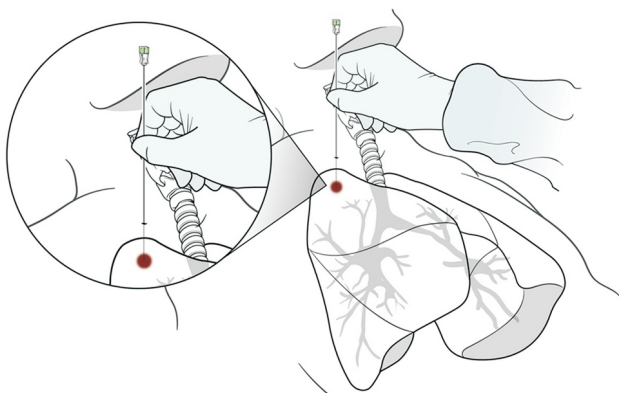


Fig. 1. Schematic diagram of percutaneous electromagnetic transthoracic nodule localization.

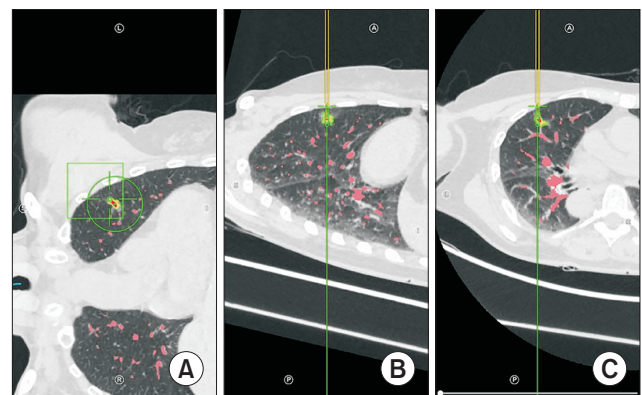


Fig. 2. The entrance point (A), the path (B), and the target (C) shown on screen.

wedge resection. The specimens were collected and sent for a frozen pathologic diagnosis. Depending on the pathology findings, additional segmentectomy or lobectomy with mediastinal lymph node dissection was performed.

Definitions

The depth from the visceral pleura was defined as the distance between the visceral pleura and the proximal margin of the target lesion, whereas the depth from the entry point was defined as the distance from the entry point of the skin to the distal margin of the target lesion. The procedure time was defined as the time interval between the start of the registration phase and the withdrawal of the localization needle (the end of nodule marking).

Statistical analysis

The characteristics of the patients, procedures, and pathologies were summarized using descriptive statistics. Categorical variables were expressed as counts and percentages, whereas continuous variables were expressed as median and range. All analyses were performed using IBM SPSS ver. 25.0 (IBM Corp., Armonk, NY, USA).

Table 1. Baseline characteristics of patients and procedures (n=18)

Characteristic	Value
Age (yr)	58 (29–74)
Sex	
Male	11 (61.1)
Female	7 (38.9)
Type of ground glass nodule	
Pure	9 (50.0)
Part-solid	9 (50.0)
Location	
Right upper lobe	6 (33.3)
Right middle lobe	1 (5.6)
Right lower lobe	3 (16.6)
Left upper lobe	7 (38.9)
Left lower lobe	1 (5.6)
Type of surgery	
Wedge resection	14 (77.8)
Segmentectomy	1 (5.6)
Lobectomy	3 (16.6)
Procedure time (min)	10 (7–20)
Localization	
Dye only	13 (72.2)
Dye+microcoil	5 (27.8)
Success	17 (94.4)

Values are presented as number (range) or number of patients (%).

Results

The patients included 11 men, with a median age of 58 years (range, 29–74 years). There were 9 pure and 9 part-solid GGNs. The nodules were located mostly in the upper lobes of both sides (6 in the right upper lobe and 7 in the left upper lobe). In total, 14 patients underwent wedge resection, 1 underwent segmentectomy, and 3 underwent lobectomy. The median procedure time was 10 minutes (range, 7–20 minutes) (Table 1). The target lesion was successfully localized in 17 patients (94.4%). All surgical resections were performed using VATS. No complications were associated with either localization or surgical resection.

The median nodule size was 9.0 mm (range, 4.0–20.0 mm). The median depth from the visceral pleura was 5.2 mm (range, 0.0–14.4 mm) with a median depth from the entry point of 69.1 mm (range, 36.8–104.7 mm). After diagnostic wedge resection, the median safety margin was 8.5 (range, 0.0–18.0) mm (Table 2). There were 3 benign lesions (1 case each of smoking-related interstitial fibrosis, granulomatous inflammation, and interstitial fibrosis) and 15 cancerous or precancerous lesions (2 cases of atypical adenomatous hyperplasia, 4 cases of adenocarcinoma *in situ*, 6 cases of minimally invasive adenocarcinoma, and 3 cases of invasive adenocarcinoma) (Table 3).

Discussion

The detection of focal GGNs has increased with the adoption of CT as the primary modality for screening high-risk

Table 2. Baseline characteristics of nodules (n=18)

Characteristic	Value
Size (mm)	9.0 (4.0–20.0)
Depth from visceral pleura (mm)	5.2 (0.0–14.4)
Depth from entry point (mm)	69.1 (36.8–104.7)
Safety margin (mm)	8.5 (0.0–18.0)

Values are presented as number (range).

Table 3. Pathologic characteristics of nodules (n=18)

Characteristic	No. of patients (%)
Benign	
Smoking-related interstitial fibrosis	1 (5.6)
Granulomatous inflammation	1 (5.6)
Interstitial fibrosis	1 (5.6)
Atypical adenomatous hyperplasia	2 (11.1)
Adenocarcinoma <i>in situ</i>	4 (22.2)
Minimally invasive adenocarcinoma	6 (33.3)
Invasive adenocarcinoma	3 (16.6)

patients for lung cancer. Previous studies have demonstrated a correlation between GGNs and early-stage lung cancer. Nakata et al. [8] reported that a persistent focal GGN might suggest early adenocarcinoma or its precursor, especially for lesions larger than 1 cm or with a solid component. Asamura et al. [9] also described both non-solid and part-solid GGN lesions as early lung cancers. These findings suggest the importance of an accurate and prompt histologic diagnosis of GGNs after observation for several months.

Although VATS is known to be a safe and definitive diagnostic method for PNs, it has been considered to be challenging to identify lesions clearly using a thoracoscope. Suzuki et al. [3] reported that VATS failed to localize small PNs in approximately 54% of cases; they also reported that the rate of conversion to thoracotomy was approximately 63% when the distance from the pleural surface was >5 mm and the diameter \leq 10 mm. These data have led to the development of a variety of localization methods. Among them, CT-guided localization using a hookwire, lipiodol, or microcoil has been widely adopted [10]. These methods have shown a high success rate, but have several limitations despite their accuracy. First, CT-guided localization is associated with numerous complications, including pneumothorax, bleeding, dislodgement or migration of markers, and dye diffusion [5]. Second, CT-guided localization is performed under local anesthesia, possibly inducing unnecessary anxiety in patients during the procedure. Finally, the procedure is not performed in the operating room, resulting in a potential delay between the time of localization and surgery. Unlike the traditional CT-guided localization technique, ETTNL is performed under general anesthesia in the operating room, with precise targeting and in a brief time. The surgical procedure under 1-lung ventilation was performed immediately after localization. Therefore, complications such as pneumothorax or hemothorax could be handled securely and immediately. Furthermore, patients do not experience unnecessary anxiety or pain during the procedure.

ENB has been used to enhance the diagnostic yield. Gildea et al. [11] performed one of the first prospective studies evaluating the diagnostic capabilities of ENB in targeting lesions located at the periphery of the lung or mediastinal lymph nodes. The reported overall success rate was 80%, with a 74% diagnostic yield for peripheral lung lesions. Another study by Eberhardt et al. [12] evaluated the diagnostic yield of ENB and reported an overall success rate of 67%. Based on these studies, the American College of Chest Physicians guidelines has suggested that ENB is use-

ful [13]. However, recent prospective and randomized trial data have shown that the diagnostic yield of ENB may only be approximately 38% [14,15]. This indicates that ENB alone may not be adequate for the diagnosis of peripheral lung nodules.

In response to recent findings, the ETTNL method, a newly developed technique, was introduced to improve the diagnostic yield. Hsu and Wu [6] recently presented 6 cases using perioperative ETTNL via VATS to localize and resect small PNs. They used a microcoil with dye or indocyanine green for ETTNL during VATS, and all cases were successful. Furthermore, Long et al. [7] reported 31 cases of ETTNL localization using dye, with a success rate of 94%. These data presented a shorter procedure time than was reported for ENB [6,7]. For these reasons, it seems that ETTNL could be more advantageous than ENB in terms of both accuracy and procedure duration. The ENB procedure can be performed simultaneously in the operating room. However, there are several differences between the ETTNL and ENB procedures. Using ENB, only the bronchoscopic approach is available, and this procedure is unfamiliar to surgeons. However, both bronchoscopic and transthoracic approaches are available for ETTNL, and the procedure is familiar to surgeons.

In this study, we performed ETTNL in 18 patients. In the first 13 cases, localization was performed using dye only, whereas both dye and a microcoil were used in the 5 subsequent cases. Using dye alone was successful in specifying the location of the lesion. However, in order to estimate the depth of the lesion, we used dual localization (dye and microcoil), and lung resection was performed under C-arm guidance. In the present study, 1 patient had a 5-mm lesion in the superior segment of the right lower lobe. The depth from the visceral pleura was 6.7 mm. To obtain an adequate safety margin, we performed superior segmentectomy of the right lower lobe, and the pathologic diagnosis was atypical adenomatous hyperplasia.

Three unplanned lobectomies were performed in this study. Among the cases of lobectomy, localization succeeded in 2 cases and failed in 1 case. In the 2 successful cases, the lesions were located in the right middle lobe and the left upper lobe, with sizes of 12.0 mm and 14.0 mm, respectively. After wedge resection, the safety margins were 0.0 mm and 2.0 mm, respectively. We had to consider more extensive resection to obtain an appropriate margin. Furthermore, the distance to the intersegmental plane was inappropriately close for performing segmentectomy. Therefore, lobectomy was performed in these patients. There was 1 case of localization failure among the 3 lobectomies; this

patient had a part-solid nodule in the right upper lobe. The nodule was located 13.4 mm from the visceral pleura and the size was 15.0 mm on CT images. After dual localization, diagnostic wedge resection was performed. Although the microcoil was revealed, the lesion was not identified on frozen pathology. Following this, complete lobectomy of the right upper lobe was performed, and the final pathological diagnosis was invasive adenocarcinoma. A possible explanation for this may be that the microcoil was dislodged or migrated during the procedure.

Based on our experience, several factors must be considered when performing ETTNL. First, the position of the patient may be important for both CT and ETTNL. The patient's position during chest CT prior to localization, either lateral or supine, based on the location of the lesion, should be maintained for the localization procedure in the operating room. Second, the location of the lesion may be another important consideration for localization. If the lesion is at the posterior side of the lung, it may hinder the localization procedure; in such cases, the prone position should be chosen during CT and the localization procedure. Third, in contrast to previous ETTNL studies, the targeted lesions were confined to GGNs in this study. Meanwhile, upper lobe predominance was observed in this study, with 6 right upper lobe cases and 7 left upper lobe cases. However, this was a coincidence, and there is no limitation of ETTNL for lower lobe lesions. Some studies have shown that GGNs may be closely associated with lung adenocarcinoma, and their management should be distinct from that of solid nodules. Sublobar resection has been accepted as the treatment strategy for small GGNs, unlike solid lesions, because of its invasiveness [16-18]. As such, the efficacy of ETTNL in GGNs was the focus of this study.

This study has some limitations. The data were collected and analyzed retrospectively, and the study population was small. Moreover, there was no experimental or control group to compare ETTNL with other localization methods or no localization. Therefore, further large-scale and follow-up studies are required. Despite these limitations, however, a major strength of the study is that it attempted to reveal the efficacy of a newly developed technique.

This study indicates that ETTNL may be an effective and promising technique for the localization of small and non-palpable GGNs. ETTNL may also lead to safe and confirmative resection via VATS and a definitive diagnosis, all in 1 stage.

Conflict of interest

No potential conflict of interest relevant to this article was reported.

Acknowledgments

The authors thank Medical Illustration & Design, part of the Medical Research Support Services of Yonsei University College of Medicine, for all artistic support related to this work.

ORCID

Seung Hwan Song: <https://orcid.org/0000-0002-3910-5585>

Hyun Soo Lee: <https://orcid.org/0000-0003-3684-6510>

Duk Hwan Moon: <https://orcid.org/0000-0003-1388-2471>

Sungsoo Lee: <https://orcid.org/0000-0001-8998-9510>

References

1. National Lung Screening Trial Research Team, Aberle DR, Adams AM, et al. *Reduced lung-cancer mortality with low-dose computed tomographic screening*. N Engl J Med 2011;365:395-409.
2. Aberle DR, DeMello S, Berg CD, et al. *Results of the two incidence screenings in the National Lung Screening Trial*. N Engl J Med 2013;369:920-31.
3. Suzuki K, Nagai K, Yoshida J, et al. *Video-assisted thoracoscopic surgery for small indeterminate pulmonary nodules: indications for preoperative marking*. Chest 1999;115:563-8.
4. Saito H, Minamiya Y, Matsuzaki I, et al. *Indication for preoperative localization of small peripheral pulmonary nodules in thoracoscopic surgery*. J Thorac Cardiovasc Surg 2002;124:1198-202.
5. Lin MW, Chen JS. *Image-guided techniques for localizing pulmonary nodules in thoracoscopic surgery*. J Thorac Dis 2016;8(Suppl 9):S749-55.
6. Hsu PK, Wu YC. *The feasibility of electromagnetic navigation-guided percutaneous microcoil localization for thoracoscopic resection of small pulmonary nodules*. J Thorac Cardiovasc Surg 2019;157:e211-4.
7. Long J, Petrov R, Haithcock B, et al. *Electromagnetic transthoracic nodule localization for minimally invasive pulmonary resection*. Ann Thorac Surg 2019;108:1528-34.
8. Nakata M, Saeki H, Takata I, et al. *Focal ground-glass opacity detected by low-dose helical CT*. Chest 2002;121:1464-7.
9. Asamura H, Suzuki K, Watanabe S, Matsuno Y, Maeshima A, Tsuchiya R. *A clinicopathological study of resected subcentimeter lung cancers: a favorable prognosis for ground glass opacity lesions*. Ann Thorac Surg 2003;76:1016-22.

10. Park CH, Han K, Hur J, et al. *Comparative effectiveness and safety of preoperative lung localization for pulmonary nodules: a systematic review and meta-analysis*. Chest 2017;151:316-28.
11. Gildea TR, Mazzone PJ, Karnak D, Meziane M, Mehta AC. *Electromagnetic navigation diagnostic bronchoscopy: a prospective study*. Am J Respir Crit Care Med 2006;174:982-9.
12. Eberhardt R, Anantham D, Herth F, Feller-Kopman D, Ernst A. *Electromagnetic navigation diagnostic bronchoscopy in peripheral lung lesions*. Chest 2007;131:1800-5.
13. Rivera MP, Mehta AC, Wahidi MM. *Establishing the diagnosis of lung cancer: diagnosis and management of lung cancer, 3rd ed: American College of Chest Physicians evidence-based clinical practice guidelines*. Chest 2013;143(5 Suppl):e142S-e165S.
14. Ost DE, Ernst A, Lei X, et al. *Diagnostic yield and complications of bronchoscopy for peripheral lung lesions: results of the AQUIRE Registry*. Am J Respir Crit Care Med 2016;193:68-77.
15. Yarmus L, Akulian J, Wahidi M, et al. *A prospective randomized comparative study of three guided bronchoscopic approaches for investigating pulmonary nodules: the PRECISION-1 Study*. Chest 2020;157:694-701.
16. Zhang Y, Fu F, Chen H. *Management of ground-glass opacities in the lung cancer spectrum*. Ann Thorac Surg 2020;110:1796-804.
17. Sagawa M, Oizumi H, Suzuki H, et al. *A prospective 5-year follow-up study after limited resection for lung cancer with ground-glass opacity*. Eur J Cardiothorac Surg 2018;53:849-56.
18. Lee GD, Park CH, Park HS, et al. *Lung adenocarcinoma invasiveness risk in pure ground-glass opacity lung nodules smaller than 2 cm*. Thorac Cardiovasc Surg 2019;67:321-8.