

This is an Open Access article licensed under the terms of the Creative Commons Attribution-NonCommercial-NoDerivs 3.0 License ([www.karger.com/OA-license](http://www.karger.com/OA-license)), applicable to the online version of the article only. Distribution for non-commercial purposes only.

## Original Paper

---

# Isolated Hand Paresis: A Case Series

Karl B. Alstadhaug<sup>a, b</sup> Ane Sjulstad<sup>a</sup>

<sup>a</sup>Department of Neurology, Nordland Hospital Trust, Bodø, and <sup>b</sup>Institute of Clinical Medicine, University of Tromsø, Tromsø, Norway

## Key Words

Stroke · Stroke mechanism · Cortical hand · Hand knob · Monoparesis · Hand motor cortex

## Abstract

**Background:** Hand knob infarction is a well-known stroke entity. Based on very limited data, embolic stroke mechanism has been considered the most frequent cause; however, prognosis is considered good. We wanted to shed more light on this phenomenon by assessing a cohort of patients referred to a general hospital stroke unit. **Methods:** Every subject admitted to our stroke unit with an acute isolated hand paresis in the period from 2007 to 2012 was identified prospectively. Patients who had suffered from a stroke in the hand motor cortex or an adjacent area explaining the acute loss of hand function were included in the study. The Trial of Org 10172 in Acute Stroke Treatment criteria were used to classify subtypes of stroke according to etiology. The patients were followed up during autumn 2012. **Results:** Seventeen subjects were admitted, but in 2 of them symptoms were transitory and magnetic resonance imaging was negative. Two patients were excluded due to persisting sensory deficits. The remaining 13 (11 males and 2 females) patients with an average age of 62.9 ( $\pm 13.4$ ) years were included, representing 1.5% of all ischemic strokes diagnosed at the stroke unit in the given period. All patients were right-handed, and the dominant hand was affected only in 4 (31%). The average Medical Research Council's scale score was 3.1 ( $\pm 1.4$ ) on admission, and classified as bad. On follow-up, which occurred on average 29.8 ( $\pm 19.8$ ) months after the stroke, the score was 4.6 ( $\pm 0.4$ ) and was classified as fair to good. No patient experienced a new stroke. The outcome was good to excellent in 10 patients (77%). Two patients died (15%), 1 of probable cardiac arrest and 1 of unknown cause. One patient did not participate in the follow-up. The majority of patients had evidence of both small artery (77%) and large artery (85%) disease. On average, there were 1.6 ( $\pm 0.4$ ) new ischemic lesions per patient. Six patients had a solitary lesion (46%). In 5 of them, small artery occlusion was considered the probable stroke mechanism. In 4 cases, the stroke was of undetermined etiology. Three

---

Karl B. Alstadhaug  
Department of Neurology Nordland Hospital Trust  
NO–8092 Bodø (Norway)  
E-Mail Karl.bjornar.alstadhaug@nlsh.no

patients had atrial fibrillation, and in 2 of them cardioembolism was the probable stroke mechanism. Two patients with definite large artery atherosclerosis underwent carotid endarterectomy, and 1 of them had comorbid atrial fibrillation. **Conclusion:** Strokes causing isolated hand paresis seem to have a heterogeneous etiology. Prognosis regarding hand function is good, but long-term outcome depends on stroke etiology and secondary prophylaxis.

Copyright © 2013 S. Karger AG, Basel

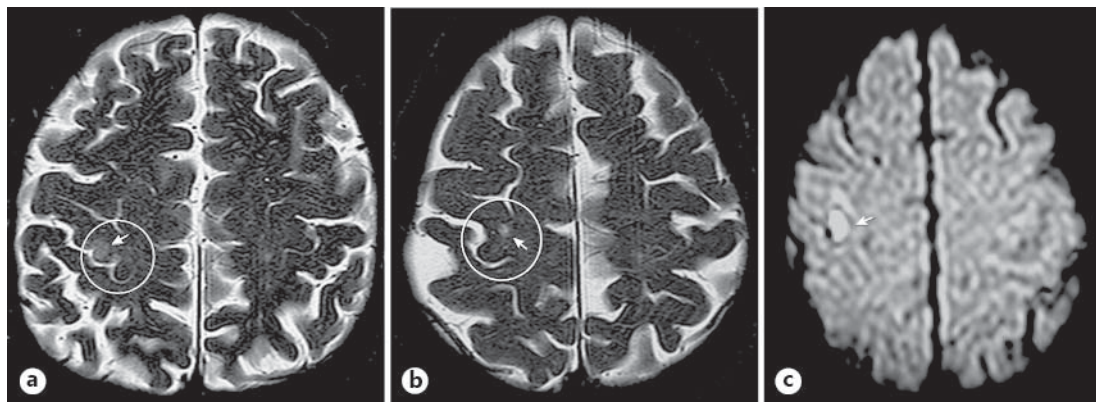
## Introduction

Isolated hand paresis may suggest a disease in the peripheral nervous system [1], but it may also represent damage to the superior aspect of the precentral gyrus, the hand motor cortex, or the adjacent area [2]. There is considerable variation in the vascularization of the precentral gyrus [3] and the morphology of the hand motor cortex [4], but the ‘hand knob infarction’ is a well-known stroke entity. Several cases have been reported in the literature: some single cases [5–7] and some case series [8–12]. To our knowledge, Peters et al. [11] presented the largest cohort to date consisting of 29 patients. Pikula et al. [12] reported 8 patients with arm weakness, but the loss of power was predominantly distal. In general, good recovery of the strokes has been reported, but both short- and long-term outcome depends on etiology. In the majority of cases, a potential source of embolism was found. Thus, it has been concluded that embolic stroke mechanisms are the most frequent and likely cause [5, 8, 9, 11]. Keeping this in mind, isolated hand paresis would signal a less favorable prognosis than previously reported. With its sophisticated function orchestrating the hand, it is plausible to believe that the hand knob is especially vulnerable to small vessel disease and perfusion failure. To test a ‘lacunar hypothesis’ [13] and to assess related long-term outcome, we prospectively recorded every patient with acute hand paresis admitted to our stroke unit during the last 5 years, reviewed onset of clinical manifestations and findings on examinations, assigned the stroke subtype [14], and followed up the patients during autumn 2012. To better illustrate the material, case examples are given.

## Material and Methods

### *Patient Population*

In 2004, the stroke unit of our Department of Neurology was given a 10-year concession for an electronic stroke database by the Norwegian Data Protection Authority. The county of Nordland, Norway, has a population of around 240,000 inhabitants and it has only one Department of Neurology. However, there are several smaller hospitals in the county that treat stroke patients. Complicated cases are usually transferred to our department. As per January 1, 2012, the primary stroke unit area of the Nordland Hospital Trust comprised 78,565 inhabitants [15]. We studied every patient who was admitted to the unit due to an isolated hand paresis in the period from June 2007 to June 2012. Subjects were identified prospectively by one of the authors (K.B.A.). Patients, who had suffered from a stroke in the hand motor cortex or an adjacent area explaining the acute loss of hand function, were included in the study. If symptoms were short lasting and/or magnetic resonance imaging (MRI) was negative, the patients were excluded from the study. If diffusion weighted images (DWI) revealed additional lesions outside the hand knob area, the patients could only be included in the study if the lesions were considered to be ‘clinically silent’. During autumn 2012, all included patients were summoned for ambulatory control by the other author (A.S.).



**Fig. 1.** **a** T<sub>2</sub>-weighted MRI showing a small infarction in the lateral part of the epsilon-shaped knob of the right precentral gyrus. **b** T<sub>2</sub>-weighted MRI showing a small infarction in the inverted omega-shaped knob of the right precentral gyrus. **c** DWI MRI showing a small infarction in the right lateral part of the hand knob on the motor cortex.

#### *Clinical Assessment*

All patients underwent evaluation, diagnostics and treatment according to national [16] and international standards [17]. Furthermore, electrocardiography (ECG) and/or Holter ECG/telemetry, MRI and/or computed tomography (CT), and vascular imaging (Doppler ultrasonography and/or MR angiography) were performed. When indicated, echocardiography was conducted. For assessing disability, the modified Rankin Scale (mRS) was used [18, 19]. There is no validated instrument for scoring isolated hand impairment, and hand function was thus described by its faced values during a thorough neurological examination. In several patients, a film was used to document minor function loss on admission. Consent for filming was given by the patients. Muscle strength was graded according to the Medical Research Council's (MRC) scale score for muscle power. Plus or minus was added to broaden the scale. Hand function was classified as bad if the MRC score was lower than 4, fair if 4±, and good if 5– to 5. Active multidisciplinary evaluation and eventually rehabilitation were given if considered necessary according to the guidelines [16, 17]. mRS was used to rate outcome, but outcome was also classified as: bad (death, new disabling stroke or hand function with a MRC score lower than 4), good (no new disability and unchanged or improved hand function with a MRC score of 4), and excellent (no new disability and hand function with a MRC score of 5).

#### *Radiological Assessment*

All patients, except 1, were examined with a 1.5-T MR system (Magnetom Vision; Siemens Medical Systems). One patient (case 5) had a positive CT scan but no MRI. Lesions were identified on DWI and T<sub>2</sub>-weighted images by experienced radiologists. First, the precentral gyrus was identified, and second, the hand knob was localized as an epsilon-shaped structure (case 7, fig. 1a) or more frequently as an inverted-omega structure (case 9, fig. 1b).

#### *Classifying the Subtypes of Ischemic Stroke*

We used a system for subtype categorization of ischemic stroke that was developed in 1993 for the Trial of Org 10172 in Acute Stroke Treatment (TOAST) [14]. This classification system, which is validated and easy to use, denotes five subtypes of ischemic stroke: (1) large artery atherosclerosis (LAA), (2) cardioembolism (CE), (3) small artery occlusion (SAO),

(4) stroke of determined etiology (SDE), and (5) stroke of undetermined etiology (SUE). The latter category was used when two or more potential factors were considered to have caused the stroke.

#### *Data Acquisition and Analysis*

Data was obtained during the stay in the department, retrospectively from the patient journal, the stroke database, and the follow-up control. Demographics, clinical characteristics, premorbidity, vascular risk factors, radiological and other supplementary findings, and finally treatment, were evaluated. Data was analyzed with SPSS software (version 18.0 for Windows; SPSS Inc., Chicago, Ill., USA), and are mainly descriptively displayed.

## Results

### *Cases*

In the given 5-year period, 17 subjects were admitted to the stroke unit because of an acute isolated hand paresis. In 2 of them, symptoms were transitory and workup was negative. They were diagnosed with transient ischemic attack and were excluded from the study. Two other patients were also excluded after the follow-up because examination revealed a good hand function, but persistent sensory loss of the affected hand. In 1 of these patients, DWI had revealed two small ischemic lesions. One was identified in the left caudate nucleus and the other one just beneath the ipsilateral hand knob. In the other patient, DWI revealed 5–6 smaller lesions in the corresponding hand hemisphere. He underwent an endarterectomy of the right carotid artery, and had an excellent outcome 12 months later. The remaining 13 patients were diagnosed with a small stroke in the corresponding ‘hand knob’ or adjacent brain area. Three case examples are given beneath. Seven of the patients were filmed. Baseline characteristics and clinical data of the included subjects are given in table 1.

*Case 7.* A 76-year-old female with hypertension and paroxysmal atrial fibrillation noticed sudden loss of fine motor control in the two ulnar fingers of the left hand, and 4 days later of the whole hand. On admission, her international normalized ratio was 2.8. A small loss of speed and power (MRC score 5–; online suppl. video 1; for all online suppl. material, see [www.karger.com/doi/10.1159/000350708](http://www.karger.com/doi/10.1159/000350708)) of the hand and fingers was found. ECG showed atrial fibrillation, but transthoracic echocardiography revealed no cardiac thrombus. MRI revealed two minor ischemic lesions: one in the right semiovale center and one in the right motor cortex (fig. 1a). A highly significant carotid stenosis was found, and the patient underwent endarterectomy. According to the TOAST classification, the presence of LAA and the high risk of CE are mutually exclusive, and consequently this type of stroke should be classified as SUE. However, in this case LAA was considered probable. On follow-up 32 months later, the clinical status was unchanged (mRS 1).

*Case 9.* A previously healthy 61-year-old male was writing on his PC when the fingers of his left hand suddenly did not obey. This lasted for 30 min. Two days later, he was suddenly not able to roll tobacco. On examination the following day, only a minor reduction of finger velocity was observed on tapping (MRC 5–; online suppl. video 2). MRI revealed two small ischemic lesions: one in the right parietal-occipital region and one in the right motor cortex (fig. 1b). A significant carotid stenosis was found, and the patient underwent endarterectomy. On follow-up about 2.5 years later mRS was 0.

*Case 10.* A previously healthy 56-year-old secretary suddenly experienced loss of fine motor control in the second to fourth fingers of the left hand while typewriting. Initially, she had experienced some tingling distally in the fingers. On admission, reduced speed of finger play (online suppl. video 3) and reduced power (MRC score 4+) for hand contraction and

**Table 1.** Demographics, premorbidity, clinical and paraclinical characteristics at time of onset and admission

	Males	Females	Total
<b>Demographics</b>			
Subjects	11 (85)	2 (15)	13 (100)
Age, years	62.4±13.9	66.0±14.1	62.9±13.4
BMI	25.8±4.7	27.5±3.5	26.1±4.3
Handedness (R/L)	11/0	2/0	13/0
<b>Concomitant vascular disease or risk</b>			
Arterial hypertension	8 (62)	1 (50)	9 (69)
Diabetes mellitus	2 (18)	0	2 (15)
Hyperlipidemia	5 (46)	0	5 (39)
Cardiac disease	2 (18)	1 (50)	3 (23)
Peripheral vascular disease	1 (9)	0	1 (8)
Previous TIA and/or stroke	6 (55)	0	6 (46)
Thrombophilia	1 (9)	0	1 (8)
Prestroke mRS	0.5±1.2	0	0.4±1.1
<b>Natural stimulants</b>			
Alcohol units, per week	9.0±23.7 <sup>a</sup>	2.0±0	9.0±23.7
Current smoker (yes/no)	3/11	1/2	4/13
Previous smoker (yes/no)	5/11	1/2	6/13
Drug abuse (yes/no)	1/11	0/2	1/13
<b>Clinical and paraclinical parameters</b>			
Dominant hand affected	4 (36)	0	4 (31)
MRC score	4.4±0.5	2.9±1.4	3.1±1.4
MRI lesions	1.5±0.7	2.0±0	1.6±0.7
Cardiac dysrhythmia	1 (9)	2 (100)	3 (23)
Leukoaraiosis	9 (82)	1 (50)	10 (77)
Significant carotid artery stenosis	1 (9)	1 (50)	2 (15)
Carotid artery atherosclerosis	10 (91)	1 (50)	11 (85)

Values are mean ± SD or n (%). <sup>a</sup> One patient reported 12 units per day.

wrist extension were found. A suspect Babinski's sign was observed on the left side; however, the reflexes were normal. DWI MRI revealed two small ischemic lesions: one in the lateral part of the right hand knob (fig. 1c) and another just beneath. A 24-hour Holter ECC and an ECG were negative, and no other pathology or specific risk factors were found, and she was discharged with antithrombotic treatment. However, 1 month later a paroxysmal atrial fibrillation was found, and treatment was switched to an anticoagulant. On follow-up 3 years later, she had no symptoms or disability (mRS 0).

#### *Workup*

The majority of patients (n = 10, 77%) were current or previous smokers, had hypertension (n = 9, 69%) and white matter changes indicating small vessel disease (n = 10, 77%). However, LAA was found in 11 patients (86%), including internal carotid artery stenosis of greater than 50% in 5 patients (38%). Three of these patients had stenosis greater than 70% and underwent carotid endarterectomy (21%). One received anticoagulant due to a paroxysmal atrial fibrillation (patient 7). Two more patients had a high-risk source of CE. One had a congenital cardiomyopathy, and an atrial fibrillation (patient 1) was recognized on ECG. Another patient with no revealed risk factors during hospital stay suffered from paroxysmal atrial fibrillation 1 month after being discharged (patient 10). On average, 1.6 (±0.7) DWI lesions were found per patient. Six patients had a solitary lesion (46%).

**Table 2.** Suspected stroke mechanism, secondary prophylaxis, stroke recurrence, hand function and mRS

Case (sex)	Probable stroke mechanism (number of MRI lesions)	Prophylaxis	Stroke recurrence	Hand function on follow-up	Outcome mRS/ classification
1 (m)	CE (1)	AC, S, AH	no	good	0/excellent
2 (m)	SUE (2)	AP, S	no	fair	1/good
3 (m)	SAO (1)	AP, S, AH	no	good	0/excellent
4 (m)	SUE (3)	AP, S, AH	no	good	0/excellent
5 (m)	SAO (1)	AP, S, AH, AD	no	fair	1/good
6 (m)	SAO (1) <sup>b</sup>	AP, AH	no	fair	1/good
7 (f)	LAA (2)	AC, AH, CEA	no	fair	1/good
8 <sup>a</sup> (m)	SUE (2)	AP, S	no	fair	1/good
9 (m)	LAA (2)	AP, S, CEA	no	good	1/good
10 (f)	CE (2)	AC, S, AH	no	fair	1/good
11 <sup>a</sup> (m)	LAA (6)	AP, S, AH, CEA	no	good	1/good
12 (m)	SAO (1)	AP, S, AH	no	good	1/good
13 (m)	SUE (2)	AP, S, AH	–	fair <sup>c</sup>	5/bad
14 (m)	SUE (1)	AP, S, AH, AD	–	–	5/bad
15 (m)	SAO (1)	AP, S, AH	no	fair <sup>d</sup>	–

AC = Anticoagulant; AH = antihypertensive medication; AP = antiplatelet medication; CEA = carotid endarterectomy; S = statin.

<sup>a</sup> Excluded after follow-up; <sup>b</sup> CT lesion; <sup>c</sup> 3 months after the stroke; <sup>d</sup> 1.5 months after the stroke.

### Follow-Up

The mean follow-up period was 29.8 (±0.7) months. Two patients died (15%). One (case 14) died from cardiac arrest 2 months after a single lacunar infarction in his right hand knob. He had diabetes with multiple and severe concomitant vascular disease; both legs had been amputated and massive atherosclerosis was found in his carotids. Another patient (case 13) had recovered well at 3-month follow-up, but died unexpectedly from unknown cause 6 months after the stroke. He had a history of hypertension, and workup gave evidence of both small and large artery disease. The etiology of the stroke remained unknown. One patient (case 15) did not present to the planned follow-up consultation. However, 3 months after the stroke his hand function was described by the rehabilitation doctor as fair. Prior to the isolated infarction in the right hand knob, the patient had experienced a lacunar stroke in the pons. He was very hypertensive during the hospital stay, and ultimately he admitted using amphetamines for the last 15 years. None of the patients who were followed experienced a second stroke. Table 2 shows the follow-up data.

### Discussion

The incidence of acute isolated hand paresis is not known, but it is considered to constitute less than 1% of all ischemic strokes [10, 11]. Usually, embolism, either from cardiac or large artery disease, has been suggested [5, 8, 9, 11]. A good recovery and favorable outcome have also been reported [11]. Data from the present study indicates that acute isolated hand paresis is uncommon, but not rare. The strength of the present study is the prospective recording and a study population representative for the general population. Small sample size renders inferential analyses impossible, and conclusions should thus be drawn with caution.

### *Incidence*

A total of 866 ischemic strokes were diagnosed and treated in our stroke unit in the given 5-year period. With an incidence of 1.5%, isolated hand paresis caused by ischemic stroke is slightly higher than previously reported. This may be due to the prospective identification and the increased vigilance. Peters et al. [11] retrospectively identified 29 (0.83%) patients with isolated hand paresis out of 3,499 stroke patients in a 5-year period. In that study, multiple diffusely distributed DWI lesions also affecting the hand knob were not included. Excluding clinically silent lesions would potentially underestimate CE as stroke mechanism. If only patients with single lesions were included in the present study (n = 6), an incidence of 0.7% would have been found.

### *Risk Factors*

In the present study, the risk factors appear to be distributed as in other stroke cohorts from the general population [20]. No infarct was classified as SDE. However, in addition to conventional risk factors, 4 patients had possible prothrombotic factors. A 49-year-old patient (case 3) had hypertension and activated protein C resistance due to factor V Leiden, but had never suffered from venous thrombosis. Ten years before, he had experienced a lacunar infarct and MRI revealed high signal lesions in both hemispheres compatible with small vessel disease. A solitary hand knob lesion was found on DWI. Only minor atherosclerotic changes were found in his carotids. One patient abused amphetamine and another abused alcohol, and 1 patient suffered from prostate cancer.

### *Stroke Mechanisms*

Establishing exact stroke mechanisms is difficult. Despite thorough investigations, only plausible mechanisms may be launched in the majority of cases. Peters et al. [11] found that approximately 50% of their patients had an embolic source. In their study, Gass et al. [8] found a potential embolic source in 11 of 14 (79%) patients. In the present study, the corresponding finding was 4 of 13 (31%). The lower frequency of embolic strokes may partially be explained by the use of the TOAST criteria. Two of the 4 patients with SUE had a potential embolic source. One had severe carotid atherosclerosis as well as severe small artery disease (case 14). The other one had hypertension and hypercholesterolemia, no carotid atherosclerosis and two minor MRI lesions. He complained of palpitation episodes, but extensive registration revealed no cardiac dysrhythmia. However, we could also argue that small vessel disease is an equal risk factor. One of the 6 patients with solitary DWI lesions had both evidence of LAA and SAO, but only 1 had a probable cardioembolic source. The remaining 4 were considered to have probable SAO. We have determined the subtypes of ischemic strokes to the best of our judgment, and our results demonstrate a heterogeneous etiology.

### *Disability and Prognoses*

Quantifying the abnormalities underlying functional disability of the hand is challenging [21], and no sophisticated methods were used in this study. However, as defined initially, fair or good hand function was documented on follow-up in all cases except in one who died from cardiac arrest (case 14). Another patient (case 13) had recovered well at 3-month follow-up, but died unexpectedly from unknown cause 6 months after her stroke. Good improvement of hand function is in accordance with the findings of Peters et al. [11]. All lesions were small, and neuroplasticity, shift of hand control from damaged to intact areas of the primary motor cortex, may explain the good motor recovery [21]. Binkofski et al. [22] and later Abela et al. [23] showed that the lesion load onto the primary motor cortex affects the rate of recovery, but also that concomitant injury of somatosensory areas causes an impaired motor skill recovery outcome. This was not the case in the present study. The 2 cases who were excluded

due to persistent sensory loss of the affected hand had a good recovery outcome. No deaths, but one new disabling stroke and two myocardial infarcts were reported in the study of Peters et al. [11], and the authors concluded with a ‘rather benign course’. They had a mean follow-up time of 25 months, quite the same as in the present study (30 months). In our cohort, no new strokes were reported, but 2 patients died (15%). With evidence of both small and large artery disease in the majority of the patients, and the fact that embolic sources are identified in several patients, isolated hand paresis should not be considered a benign condition.

## Conclusion

The findings of the present study are largely in accordance with previous findings. The incidence of isolated hand paresis is rather low. Hand improvement is expected in general to be fair to good. Despite good to excellent outcome 2 years after the stroke in the majority of patients, isolated hand paresis should not be considered a benign condition. Long-term outcome depends on risk factors and stroke mechanisms, which were found to be heterogeneous in this study.

## Acknowledgement

We want to thank our colleague Rolf Salvesen for reading the manuscript and providing good comments.

## Disclosure Statement

The authors declare that there are no conflicts of interest.

## References

- 1 Lampl Y, Gilad R, Eshel Y, Sarova-Pinhas I: Strokes mimicking peripheral nerve lesions. *Clin Neurol Neurosurg* 1995;97:203–207.
- 2 Yousry TA, Schmidt UD, Alkadhi H, Schmidt D, Peraud A, Buettner A, Winkler P: Localization of the motor hand area to a knob on the precentral gyrus. A new landmark. *Brain* 1997;120:141–157.
- 3 Ugur HC, Kahilogullari G, Coscarella E, Unlu A, Tekdemir I, Morcos JJ, Elhan A, Baskaya MK: Arterial vascularization of primary motor cortex (precentral gyrus). *Surg Neurol* 2005;64(suppl 2):S48–S52.
- 4 Caulo M, Briganti C, Mattei PA, Perfetti B, Ferretti A, Romani GL, Tartaro A, Colosimo C: New morphologic variants of the hand motor cortex as seen with MR imaging in a large study population. *Am J Neuroradiol* 2007;28:1480–1485.
- 5 Takahashi N, Kawamura M, Araki S: Isolated hand palsy due to cortical infarction: localization of the motor hand area. *Neurology* 2002;58:1412–1414.
- 6 Sudo K, Kishimoto R, Tajima Y, Matsumoto A, Tashiro K: A paralysed thumb. *Lancet* 2004;363:1364.
- 7 Hall J, Flint AC: ‘Hand knob’ infarction. *J Neurol Neurosurg Psychiatry* 2008;79:406.
- 8 Gass A, Szabo K, Behrens S, Rossmannith C, Hennerici M: A diffusion-weighted MRI study of acute distal arm paresis. *Neurology* 2001;57:1589–1594.
- 9 Castaldo J, Rodgers J, Rae-Grant A, Barbour P, Jenny D: Diagnosis and neuroimaging of acute stroke producing distal arm monoparesis. *J Stroke Cerebrovasc Dis* 2003;12:253–258.
- 10 Celebisoy M, Ozdemirkiran T, Tokucoglu F, Kaplangi DN, Arici S: Isolated hand palsy due to cortical infarction: localization of the motor hand area. *Neurologist* 2007;13:376–379.
- 11 Peters N, Müller-Schunk S, Freilinger T, Düring M, Pfefferkorn T, Dichgans M: Ischemic stroke of the cortical ‘hand knob’ area: stroke mechanisms and prognosis. *J Neurol* 2009;256:1146–1151.
- 12 Pikula A, Stefanidou M, Romero JR, Kase CS: Pure motor upper limb weakness and infarction in the precentral gyrus: mechanisms of stroke. *J Vasc Interv Neurol* 2011;4:10–13.



- 13 Bamford JM, Warlow CP: Evolution and testing of the lacunar hypothesis. *Stroke* 1988;19:1074–1082.
- 14 Adams HP Jr, Bendixen BH, Kappelle LJ, Biller J, Love BB, Gordon DL, Marsh EE 3rd: Classification of subtype of acute ischemic stroke. Definitions for use in a multicenter clinical trial. TOAST. Trial of Org 10172 in Acute Stroke Treatment. *Stroke* 1993;24:35–41.
- 15 Population and area in urban settlements, by municipality 1 January 2012. Statistics Norway. [http://www.ssb.no/english/subjects/02/01/10/befteet\\_en/](http://www.ssb.no/english/subjects/02/01/10/befteet_en/) (accessed September 12, 2012).
- 16 The Norwegian Directorate of Health: national guidelines for treatment and rehabilitation of stroke, 2010. <http://www.helsedirektoratet.no/publikasjoner/nasjonalt-retningslinje-for-behandling-og-rehabilitering-ved-hjerneslag-fullversjon/Sider/default.aspx> (accessed September 12, 2012).
- 17 The European Stroke Organization (ESO) Executive Committee and the ESO Writing Committee: European Stroke Initiative Recommendations for Stroke Management – Update 2003. *Cerebrovasc Dis* 2003;16:311–337.
- 18 Rankin J: Cerebral vascular accidents in patients over the age of 60. *Scott Med J* 1957;2:200–215.
- 19 De Haan R, Horn J, Limburg M: A comparison of five stroke scales with measures of disability, handicap, and quality of life. *Stroke* 1993;24:1178–1181.
- 20 Wolf PA, Kannel WB: Epidemiology of stroke; in Mohr JP (ed): *Stroke: Pathophysiology, Diagnosis, and Management*, ed 5th. Philadelphia, Elsevier and Saunders, 2011, pp 198–218.
- 21 Wenzelburger R, Kopper F, Frenzel A, Stolze H, Klebe S, Brossmann A, Kuhtz-Buschbeck J, Gölge M, Illert M, Deuschl G: Hand coordination following capsular stroke. *Brain* 2005;128:64–74.
- 22 Binkofski F, Seitz RJ, Hackländer T, Pawelec D, Mau J, Freund HJ: Recovery of motor functions following hemiparetic stroke: a clinical and magnetic resonance-morphometric study. *Cerebrovasc Dis* 2001;11:273–281.
- 23 Abela E, Missimer J, Wiest R, Federspiel A, Hess C, Sturzenegger M, Weder B: Lesions to primary sensory and posterior parietal cortices impair recovery from hand paresis after stroke. *PLoS One* 2012;7:e31275.