

Reduction of Intraocular Pressure Spikes Due to Intravitreal Bevacizumab Injections by Scleral Indentation with Cotton Swab or Digital Ocular Massage: Innovative Techniques Compared

This article was published in the following Dove Press journal:
Clinical Ophthalmology

Raffaele Nuzzi
Simona Scalabrin
Alice Becco

Eye Clinic, Department of Surgical
Sciences, University of Turin, AOU Città
della Salute e della Scienza, Turin, Italy

Purpose: This study aims to evaluate the effectiveness of different decompressive injection techniques in reducing intraocular pressure (IOP) spikes, if compared to the injection without pressure applied on the eye, following the intravitreal injection of bevacizumab.

Patients and Methods: Two hundred patients with indication to intravitreal therapy were randomized into five arms: 40 received intravitreal injection without ocular decompression (arm A), 40 with pre-injection scleral indentation with cotton swab (arm B), 40 with pre-injection digital ocular massage (arm C), 40 with post-injection scleral indentation with cotton swab (arm D) and 40 with post-injection digital ocular massage (arm E). All patients underwent measurement of the IOP with Goldmann applanation tonometer 10 minutes before and 10 minutes after the injection. The primary endpoint of the study was variation of the post-injection IOP with the different techniques.

Results: An increase in post-injection IOP was observed in all the arms, if compared to pre-injection values. The greatest increase was observed in arm A with a mean IOP rise of 17.60 mmHg. All other techniques showed lower mean IOP increases: arm B 10.76 mmHg, arm C 9.35 mmHg, arm D 8.8 mmHg, arm E 3.4 mmHg. The post-injection IOP differences of innovative techniques compared to the technique without ocular decompression were all statistically significant (p -value <0.01). If compared to arm A (35%), a reduction in IOP spike ≥ 40 mmHg frequency was also observed. The status of phakia/pseudophakia, a previous diagnosis of glaucoma and the underlying pathology for which indication was given to inject bevacizumab did not significantly alter the post-injection IOP in any of the protocols.

Conclusion: The introduction of new injection protocols, such as injections performed before or after decompressive treatments, could be a safe and effective approach to control post-injection IOP increase.

Keywords: bevacizumab injection, injection technique, intraocular pressure spike, digital ocular massage, scleral indentation, applanation tonometry

Correspondence: Raffaele Nuzzi
Eye Clinic of University of Turin, Turin,
Italy
Tel +39 0116337225
Fax +39 0116335481
Email prof.nuzzi_raffaele@hotmail.it

Introduction

In ophthalmological clinical practice intravitreal injections of anti vascular endothelial growth factor (anti-VEGF) drugs, such as bevacizumab, are used in the treatment of different pathologies, including exudative age-related macular degeneration (AMD), diabetic macular edema (DME) and retinal vein occlusion. Given the

widespread use of intravitreal injections, it is essential to ensure patient safety and minimization of adverse effects.

Many reports have shown changes in intraocular pressure (IOP) following anti-VEGF injections.^{1,2} The increase in IOP can be configured as transient spikes (in most cases) or as a sustained increase in IOP.² In the short term, IOP increase is mainly caused by intraocular volume increase, it resolves within about 30 minutes^{3–5} and is generally well tolerated by healthy eyes, which therefore do not require special precautions;⁶ the glaucomatous eyes are generally more sensitive to pressure spikes,⁷ which could cause a visual deterioration. Sustained IOP rise is less frequent, and has a variable frequency (between 3 and 15% of patients subjected to multiple intravitreal injection),^{5,8–12} but causes a maintained increase in IOP that requires medical or surgical treatment to obtain the control of the IOP. The pathophysiology underlying this sustained IOP rise has not yet been elucidated, but some hypotheses show that it could be associated to trabecular meshwork damage caused by many pressure spikes that occur after multiple intravitreal injections,^{2,11} to microparticle obstruction of the trabecular meshwork, and to the intraocular inflammation.¹¹ The patients at higher risk of developing sustained IOP rise are those who need multiple anti-VEGF injections.^{13,14} Considering that subsequent acute IOP rises are not rarely associated to irreversible optic nerve injury, especially in case of repeated injections, it is essential to monitor the post-injection IOP in patients undergoing intravitreal anti-VEGF injection and to research possible techniques able to reduce the risk of immediate and late increase in IOP, especially in high risk subjects.

Various attempts have been made in order to obtain adequate post anti-VEGF injection IOP. A Report by the American Academy of Ophthalmology⁵ showed that pre-treatment with glaucoma medications, anterior chamber tap, vitreous reflux, longer intervals between injections could be associated with lower IOP elevations after injection, but clinical significance and associated risks of these interventions are not well known.

Although IOP-lowering medication is recommended for prevention of IOP spikes after cataract surgery, with topical application of a combination of dorzolamide/timolol and brinzolamide in high-risk patients,¹⁵ studies on their use for prophylaxis prior to intravitreal injections are not conclusive.

Many drugs have been evaluated for prophylaxis in different application protocols, especially the

associations dorzolamide-timolol and brinzolamide-timolol. Although in some studies IOP lowering medications before intravitreal injection resulted in effective IOP control after injection,^{16–19} in other cases they did not determine statistically significant reductions in post-injection IOP rise and therefore their application in prophylaxis is not currently recommended, even if this approach may warrant further investigations.^{20,21}

An option quite frequently performed is anterior chamber (AC) paracentesis, a cost-effective procedure to immediately reduce pathological IOP rise,²² but with several potential complications including pain, traumatic injuries of the iris, iris incarceration, hyphema, severe inflammation, infection, persistent leakage with ocular hypotension, retinal hemorrhages due to rapid decrease of IOP, endophthalmitis and lens injuries.^{23,24}

The decompressive treatments have shown good results without being invasive. Historically the Honan intraocular pressure reducer (HIPR), or Honan's balloon, has been employed to soften the eyeball prior to ophthalmic surgery; it determines a compression of vitreous volume; the reduction of intraocular volume causes vitreous deturgescence and it consequently determines a decrease in IOP. Techniques based on this principle may have useful applications if performed in intravitreal injection protocols. A study for the prevention of IOP rise following injections showed that measurements taken on separate occasions after a 30 mmHg decompression of the eye with a mercury bag for 15 minutes before the injection showed a mean IOP of only 20.6 mmHg after the injection (against 44.5 mmHg without ocular decompression) confirming that decompression of the eye significantly reduced the rise in IOP following intravitreal injection (p -value <0.001), also reducing the discomfort of the injection reported by patients.²⁵ However, this treatment is no longer used, probably due to the difficult application in daily clinical practice. A small non-randomized study showed that eyes receiving pre-IVI (intravitreal injection), intermittent digital massage for 5 minutes had significantly lower IOP immediately following and 10 minutes after injection compared to eyes that did not receive ocular massage.²⁶ Also ocular decompression with cotton swab during anesthetic preparation prior to an intravitreal injection produces a significantly lower IOP spike after the injection than only instillation of anesthetic in the form of gel.^{27,28}

As reported above, the effect of ocular decompression on post injection IOP is well established by the literature,

however no study has ever compared the various decompressive techniques to reduce IOP spikes and their IOP reduction.

The objective of our study was to verify the effectiveness of different decompressive techniques in reducing the post-injection IOP after bevacizumab intravitreal injection compared to the injection technique without pressure applied on the eye. We have decided to test a faster technique with continuous pressure applied (scleral indentation with cotton swab for 1 minute, preceding or following injection) and a longer one with intermittent application of pressure (ocular digital massage applied for 5 minutes before or after the injection), each one compared to the protocol without pressure applied on the globe. The ultimate aim was to identify the best injection protocol that could substitute the standard one, in order to guarantee better control in post- injection IOP.

Patients and Methods

A monocentric prospective non-pharmacological interventional study was conducted at University Eye Clinic, A.O. U. Città della Salute e della Scienza di Torino. The study was approved by the Ethics Committee (CS2/966). A written informed consent was taken from all the participants of the study. Our study adheres to CONSORT guidelines.

Inclusion criteria for this study were:

1. Age between 18 and 99 years old.
2. Indication for intravitreal injection of anti-VEGF drug (bevacizumab).
3. Absence of contraindications to the execution of intravitreal injection (systemic or local conditions that make the injection treatment not indicated).
4. Possibility of expressing informed consent to participate in the study

Exclusion criteria were presence of local or systemic contraindications to the execution of intravitreal injection, prior intravitreal injection in the previous month or previous vitrectomy performed on the eye being studied, presence of blepharitis, meibomitis, conjunctivitis or any other state of inflammation/infection of the eyelids or globe, prior history of endophthalmitis following intravitreal injection, and prior intravitreal steroid injection in the previous 6 months.

A total of 200 patients were enrolled and underwent preoperative ophthalmologic evaluation, with anamnestic

data collection. They were randomized to the different study arms (40 eyes injected for each study arm), which differ in the injection protocol used.

Arm A was injected by intravitreal injection without ocular decompression, which is the standard technique in our center, and consists of these steps:

1. Periocular and palpebral skin disinfection with 5% povidone-iodine solution;
2. Topical anesthetic and 5% povidone-iodine instillation in the eye to be injected, which is maintained open with a standard style sterile speculum placed between the lids in order to allow the injection; we do not instillate mydriatic eye drops in order to avoid risk of precipitation of angle-closure glaucoma in susceptible individuals.
3. Intravitreal injection of 0.05 mL of bevacizumab; in our center the syringes containing the drug are routinely prepared by the hospital pharmacy and then checked by the treating physician, so the established dose of bevacizumab in the syringe and its preparation are presumed to be accurate and precise, although the number of human errors remains unknown.²⁹ The injection site is located inferotemporally, at 3.5 mm (patient with pseudophakia) or at 4 mm (patient with phakia) from the limbus. A sterile calliper was used to mark the distance from the limbus.
4. Application of gentle pressure using a sterile cotton swab in the injection site for 5 seconds as the needle was withdrawn to avoid vitreous reflux.
5. Instillation of povidone-iodine 0.5%, ofloxacin and netilmicin-dexamethasone.

Arm B was injected by pre-injection scleral indentation technique: intravitreal injection was performed according to the standard protocol, but adding pre-injection scleral indentation, that consists of the application of a slight continuous pressure using a cotton swab, such as to induce a minimum folding of the cotton swab rod and to create a visible circular indentation of the globe in the area of swab application, directly on the injection site just before performing the intravitreal injection; the pressure was applied for 1 minute.

Arm C was injected by pre-injection digital ocular massage technique: intravitreal injection was performed according to the standard protocol, but preceded by digital ocular massage; the decompression was performed just before the

periocular and palpebral skin disinfection. Pressure was supposed to be steady and firm and has been applied to the undersurface of the globe through the upper lid in an intermittent way, using two fingers, in the patterns of 3 seconds of pressure with one finger, 1 second of rest, 3 seconds of pressure with the other finger, for a total duration of 5 minutes; pressure was applied on the globe with enough force but not so much as to cause discomfort or pain.

Arm D was injected by post-injection scleral indentation technique: intravitreal injection was performed according to the standard protocol, with addition of post-intravitreal injection scleral indentation; the continuous pressure with cotton swab was applied just after the injection was performed, before the removal of the lid speculum, with a duration of 1 minute. The strength of pressure was the same applied in sclera indentation with cotton swab in Arm B.

Arm E was injected by post-injection digital ocular massage technique: intravitreal injection was performed according to the standard protocol, and has been followed by digital ocular massage. The digital massage was performed just after the injection, following the removal of the lid speculum, with a duration of 5 minutes. The technique of the intermittent ocular digital massage was the same applied in Arm C.

No eyes received pressure-lowering medication or AC paracentesis before or after the injection.

All the injections were performed by the same treating physician.

All the pre- or post-injection treatments of ocular decompression by cotton swab indentation or digital ocular massage were performed by the same physician, and their duration was timed precisely by a nurse with a chronometer watch.

All subjects underwent Goldmann applanation tonometry in a sitting position 10 minutes before and 10 minutes after the intravitreal injection of bevacizumab [Table 1]. The first and second IOP measurements were performed by the same operator and the second measurement was masked to the type of massage.

The primary endpoint of the study was variation of IOP following the different injection techniques. Secondary endpoints were the evaluation of the percentage of post-intravitreal injection IOP spikes with IOP ≥ 40 mmHg in study arms and the correlation with phakia/pseudophakia status, previous diagnosis of glaucoma, ophthalmic pathology for which indication was given to intravitreal injection. The percentage of adverse events was also evaluated.

Trial Registration

The study was approved by the Intercompany Ethics Committee of A.O.U. Città della Salute e della Scienza (Turin), on 19 December 2018 with a reference number #CS2/966. The study was recorded on ISRCTN registry (trial registration number ISRCTN14424997) on 24 July 2019.

Results

Through the ANOVA test it was verified that the different arms of the study were homogeneous at the start, so that they can be compared without incurring errors. The f-ratio value was 1.79947, the *p*-value was 0.13048: this confirmed that there were no statistically significant differences in pre-injection IOP within the various groups, which are therefore homogeneous and comparable. Table 2 shows the characteristics of the enrolled subjects in each arm.

Table 1 Different Injection Techniques

Arm	10 Minutes Before IVI	Pre-IVI	IVI	Post-IVI	10 Minutes After IVI
A	IOP measurement with Goldamm applanation tonometer	No decompression	Intravitreal injection of 0.05 mL of bevacizumab	No decompression	IOP measurement with Goldamm applanation tonometer
B		Scleral indentation		No decompression	
C		Digital ocular massage		No decompression	
D		No decompression		Scleral indentation	
E		No decompression		Digital ocular massage	

Abbreviations: IOP, intraocular pressure; IVI, intravitreal injection.

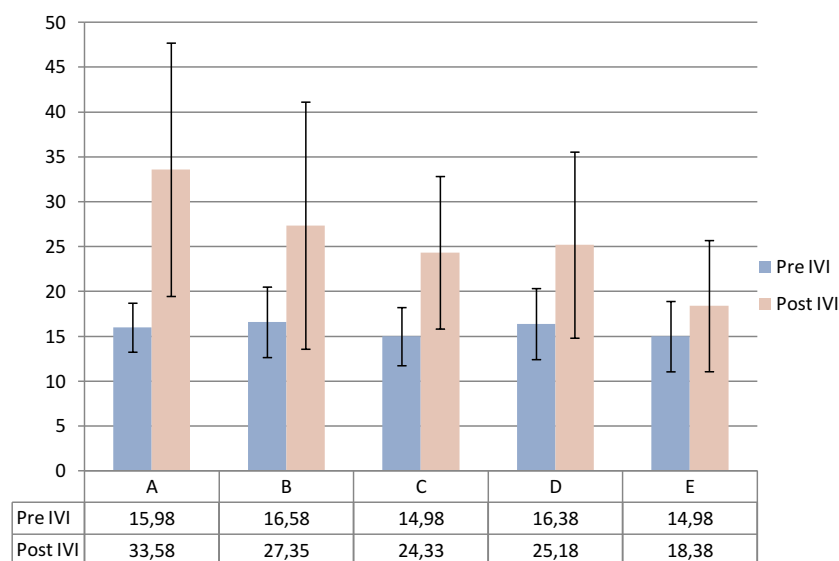
Table 2 Characteristics of the Enrolled Patients in Each Arm

	Age (Average)	Sex		Diagnosis			Glaucoma		Phakic	
		Male	Female	AMD	DME	CRVO	Yes	No	Yes	No
Arm A	75.5	20 (50%)	20 (50%)	27 (68%)	10 (25%)	3 (7%)	6 (15%)	34 (85%)	22 (55%)	18 (45%)
Arm B	73.5	17 (43%)	23 (57%)	25 (63%)	11 (27%)	4 (10%)	9 (22%)	31 (78%)	24 (60%)	16 (40%)
Arm C	75.5	19 (48%)	21 (52%)	31 (77%)	5 (13%)	4 (10%)	2 (5%)	38 (95%)	26 (65%)	14 (35%)
Arm D	74.5	15 (40%)	25 (60%)	27 (68%)	8 (20%)	5 (12%)	4 (10%)	36 (90%)	24 (60%)	16 (40%)
Arm E	70	24 (58%)	16 (42%)	21 (53%)	14 (35%)	5 (12%)	2 (5%)	38 (95%)	25 (60%)	15 (40%)

Abbreviations: AMD, age-related macular degeneration; DME, diabetic macular edema; CRVO, central retinal venous occlusion.

In all groups an IOP rise following the injection of bevacizumab was observed. This increase was statistically significant in all groups: mean IOP (SD) pre-injection in arm A (without ocular decompression techniques) was 15.98 (2.73) mmHg, mean IOP (SD) post-injection was 33.58 (14.12) mmHg, with a mean increase of 17.60 mmHg (p -value <0.0001). The mean IOP (SD) measured in arm B (pre-injection scleral indentation) before intravitreal injection was 16.58 (3.93) mmHg and post-injection of 27.35 (13.77), with a mean increase equal to 10.77 mmHg (p -value <0.0001). Within the arm C (pre-injection digital ocular massage) the pre-injection mean IOP (SD) was

14.98 (3.24) mmHg, while the post-injection mean IOP (SD) was 24.33 (8.50) mmHg, with a mean IOP increase of 9.35 mmHg (p -value <0.0001). The mean pre-injection (SD) IOP in the D arm (post-injection scleral indentation) was 16.38 (3.96) mmHg, while the average post-injection (SD) IOP was 25.18 (10.31) mmHg, with a mean IOP increase of 8.8 mmHg (p -value <0.0001). In the arm E (post-injection digital ocular massage) mean pre-injection (SD) IOP was equal to 14.98 (3.92) mmHg while the post-injection one was 18.38 (7.31) mmHg, with a mean IOP increase of 3.4 mmHg (p -value = 0.0114) (Figure 1).



Arm A	Arm B	Arm C	Arm D	Arm E
+17.60 mmHg	+10.77 mmHg	+9.35 mmHg	+8.8 mmHg	+3.4 mmHg
(95% CI 13.07-22.13)	(95% CI 6.25-15.27)	(95% CI 6.47-12.21)	(95% CI 5.32-12.28)	(95% CI 0.79-6.01)
P<0,0001	P<0,0001	P<0,0001	P<0,0001	P<0,0001

Figure 1 In all groups a statistically significant IOP rise following the injection of bevacizumab was observed. All the innovative techniques showed a significantly lower increase in post-intravitreal injection IOP if compared to the increase in IOP recorded with the injection technique without pressure applied on the globe.

Abbreviations: IOP, intraocular pressure; P, p-values; CI, confidence interval.

Through the Student's *t*-test the injection technique without ocular decompression was compared with the innovative techniques, evaluating the post-intravitreal injection final pressure difference. All the innovative techniques showed a significantly lower increase in post-intravitreal injection IOP compared to the increase in IOP recorded with the injection technique without pressure applied on the globe.

In the analysis of secondary endpoint, concerning the percentage of IOP post-intravitreal injection spikes ≥ 40 mmHg, it was observed that in arm A IOP ≥ 40 mmHg was recorded in 35% of cases (14 patients), in arm B in 27.5% of cases (11 patients), in arm C in 5% of cases (2 patients), in arm D in 12.5% of cases (5 patients), while in arm E there were no IOP spikes ≥ 40 mmHg at 10 minutes injection (Figure 2).

No statistically significant differences in IOP increase emerged between the patients with phakic eyes and those with pseudophakic eyes in arms A, C, D and E, while in arm B (pre-injection scleral indentation with cotton swab) IOP reduction was greater in the pseudophakia group (p -value = 0.0113). In all the study arms, a previous diagnosis of glaucoma showed no statistically significant effect on post-injection IOP if compared to post-injection IOP measured in subjects without glaucoma diagnosis. Even analyzing variations of post-injection IOP in relation to the different pathology for which intravitreal injection had been indicated, no statistically significant differences were identified among patients with AMD, DME or CRVO in any of the study arms.

No patient had any complications or adverse effects after the injection. In addition, these techniques proved to be comfortable for our patients, with none complaining of pain or discomfort during their application.

Discussion

Analyzing these results, it is evident that the highest post-injection mean IOP rise was evident in the technique without ocular decompression (mean increase equal to 17.60 mmHg); all the other innovative techniques showed statistically lower mean IOP rises compared to the classic technique. The technique that achieved the best post-injection IOP control was digital ocular massage for 5 minutes after injection.

In all injection protocols we also observed a lower frequency of IOP spike ≥ 40 mmHg.

The status of phakia/pseudophakia, a previous diagnosis of glaucoma and the underlying pathology for which indication was given to inject bevacizumab did not significantly alter post-injection IOP in any of the protocols, and therefore in our study they appear as less relevant conditions in the choice of the best injection protocol. Anyway, it is possible that this study was not sufficiently powered to demonstrate a statistically significant difference between groups.

Being interested in the control of IOP following the intravitreal therapy, we did not check the IOP just before the injection in Arm B and C, so we do not know the immediate effect of decompressive treatment when

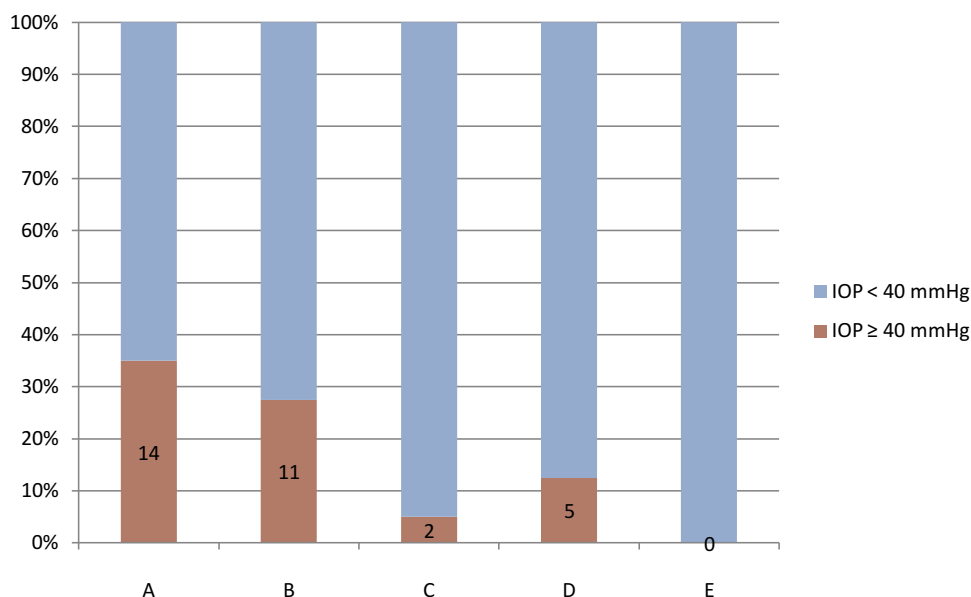


Figure 2 Without decompressive techniques, post-injection IOP ≥ 40 mmHg was recorded in 35% of cases, while in arm B in 27.5% of cases, in arm C in 5% of cases, and in arm D in 12.5% of cases. In arm E there were no IOP spikes ≥ 40 mmHg at 10 minutes injection.

Abbreviation: IOP, intraocular pressure.

performed before the injection; we suppose a decrease in IOP immediately after scleral indentation and digital massage, just before the injection was performed; in this way, an increase in IOP induced by the injection is more tolerated because less critical values of post-injection IOP are reached.

In order to better interpret the differences which emerged between the different techniques, it is important to note the possible influence of the different duration and pattern of pressure applied (continuous or intermittent) with cotton swabs and digital massage.

The main limitation of our study was the impossibility of standardization of the forces applied on the globe. The ocular decompression techniques were all performed by the same physician, in order to reduce variability in IOP among the enrolled patients caused by difference in pressure applied during sclera indentation with cotton swab or digital ocular massage. In scleral indentation, the pressure applied is that inducing a minimum folding of the cotton swab rod and creating a visible circular indentation of the globe in the area of swab application, while pressure applied during digital massage should be enough to compress the eye but not so much as to cause discomfort or pain. In fact insufficient pressure would negate the purpose of decompression while excessive force could lead to complications. Small differences can be possible and repeating the techniques with another operator may be difficult. To combat these problems various calibrated massage devices have been introduced recently. However, cost effectiveness is an important issue, and scleral indentation with cotton swab and digital massage has an advantage of causing no financial burden to patients or institutions.³⁰

In our study while one could argue that we do indeed increase IOP temporarily for 1 to 5 minutes during decompressive procedures, however this is of considerably less duration than IOP spikes which would normally occur after intravitreal injections.³⁻⁵ This improves safety in patients who undergo IVI, especially in those with glaucoma, who are more susceptible to optic nerve damage from repeated IOP spikes, and in those who receive several intravitreal injections, with high risk of sustained long-term IOP elevation.

Regarding safety of the innovative technique, especially when the globe is digitally manipulated after the injection, no adverse effect was reported in our study.

It is important to highlight that the digital ocular massage is an innovative technique if performed after intravitreal injections, but it is not a new treatment after ocular surgery at all. In fact, it is reported in the literature as a way to control IOP after trabeculectomy in cases of underfiltering blebs.³⁰

Potential complications of ocular massage reported in the literature include corneal ectasia, corneal abrasion, dehiscence of keratoplasty wound, shallow/flat anterior chamber, hyphema, iris incarceration in sclerostomy, cataract formation, endophthalmitis, sub-retinal hemorrhage, hypotony, and rupture of Bruch's membrane.³¹⁻³⁵ However, in our study no adverse effects emerged for any of the patients in each arm. In order to limit risk of infection, patients with signs of ocular inflammation/infection were excluded and all the participants received the standard antimicrobial prophylaxis of our centre just after the injection with instillation of povidone-iodine 0.5%, ofloxacin and netilmicin-dexamethasone.

We avoid vitreous reflux after injection using the cotton tip gently applied on the site of injection as the needle was withdrawn, with good efficacy. Moreover, in our experience the ocular massage performed after the injection has not resulted in an increasing reflux nor vitreous incarcerations. Although this is a risk, a study showed that the use of the HIPR after the injection did not cause increasing of vitreous reflux if compared with the non-HIPR group, while reducing post-injection IOP.³⁶

Currently an accepted and relatively frequently performed option for controlling IOP rise after IVI is AC paracentesis. This approach, as discussed before, has several reported potential complications, including endophthalmitis. Additionally, when AC paracentesis is performed, it is impossible to control IOP decrease. So, it could decrease too quickly or too much, with risk of ocular decompression retinopathy, a complication of rapid lowering of IOP resulting in haemorrhages in multiple retinal layers.³⁷ In contrast, an ocular digital massage is a closed globe strategy that potentially allows a modulation of the IOP decrease: if performed by an experienced operator, it could also be possible to feel with fingers the ocular hypertension and, if necessary, to apply the required pressure, being able to stop in case of emerging excessive hypotension. So, ocular manipulation seems to be less invasive and safer than AC paracentesis to control post-IVI hypertonia.

Therefore, even with some issues of concern which merit further attention with future studies, the innovative techniques tested in our study have demonstrated good safety and efficacy profiles, while limiting the serious risks associated to subsequent IOP spikes in patients undergoing multiple intravitreal injections.

Conclusions

Considering that nowadays intravitreal injections represent a very important therapeutic procedure and are performed

very frequently in the treatment of various ocular pathologies, it is essential to guarantee patients safety. The injection technique without ocular decompression, commonly used to perform these injections, is relatively safe, but in a considerable percentage of cases it causes IOP spikes, often ≥ 40 mmHg; although these spikes may be transient, they could damage various eye structures and should, therefore, be avoided. The introduction of new injection protocols, such as injections performed before or after scleral indentation with cotton swab or digital ocular massage, could determine an important reduction in the frequency of these IOP spikes. Although some patients are expected to be more at risk than others of persistent IOP increase and optic nerve damage, everyone could be damaged by repeated IOP spikes,⁶ the simplicity of performing these innovative techniques allows their application in daily practice for every patient who undergoes intravitreal injections, making them an excellent solution to obtain a safer intravitreal injection protocol, burdened with less adverse effects in the short and long term.

Abbreviations

AMD, age-related macular degeneration; CRVO, central retinal venous occlusion; DME, diabetic macular edema; HIPR, Honan intraocular pressure reducer; IOP, intraocular pressure; IVI, intravitreal injection; SD, standard deviation; VEGF, vascular endothelial growth factor.

Data Sharing Statement

The data sets generated and analyzed during the study are available on request from the corresponding author.

Ethics Approval and Informed Consent

This trial was conducted in accordance with the Declaration of Helsinki.

Informed written consent was obtained from all study individuals. The study was approved by the Intercompany Ethics Committee of A.O.U. Città della Salute e della Scienza (Turin), on 19 December 2018 with a reference number #CS2/966.

Consent for Publication

Consent for the publication of identifying images or other personal or clinical details of participants that compromise anonymity is not applicable.

Author Contributions

All authors made substantial contributions to conception and design, acquisition of data, or analysis and interpretation of data; took part in drafting the article or revising it critically for important intellectual content; gave final approval of the version to be published; and agree to be accountable for all aspects of the work.

Disclosure

The authors declare that they have no competing interests.

References

1. Abedi G, Adelman RA, Salim S. Incidence and management of elevated intraocular pressure with antivascular endothelial growth factor agents. *Semin Ophthalmol.* 2013;28(3):126–130. doi:10.3109/08820538.2013.771195
2. Aref AA. Management of immediate and sustained intraocular pressure rise associated with intravitreal antivascular endothelial growth factor injection therapy. *Curr Opin Ophthalmol.* 2012;23:105–110. doi:10.1097/ICU.0b013e32834ff41d
3. Gismondi M, Salati C, Salvat ML, et al. Short-term effect of intravitreal injection of ranibizumab (lucentis) on intraocular pressure. *J Glaucoma.* 2009;18:658–661. doi:10.1097/IJG.0b013e31819c4893
4. Benz MS, Albin TA, Holz ER, et al. Short-term course of intraocular pressure after intravitreal injection of triamcinolone acetonide. *Ophthalmology.* 2006;113(7):1174–1178. doi:10.1016/j.ophtha.2005.10.061
5. Hoguet A, Chen PP, Junk AK, et al. The effect of anti-vascular endothelial growth factor agents on intraocular pressure and glaucoma: a report by the American Academy of Ophthalmology. *Ophthalmology.* 2019;126(4):611–622. doi:10.1016/j.ophtha.2018.11.019
6. Tranos P, Bhar G, Little B. Postoperative intraocular pressure spikes: the need to treat. *Eye (Lond).* 2004;18:673–679. doi:10.1038/sj.eye.6701319
7. Savage JA, Thomas JV, Belcher CD3rd, Simmons RJ. Extracapsular cataract extraction and posterior chamber intraocular lens implantation in glaucomatous eyes. *Ophthalmology.* 1985;92:1506–1516. doi:10.1016/S0161-6420(85)33828-9
8. Adelman RA, Zheng Q, Mayer HR. Persistent ocular hypertension following intravitreal bevacizumab and ranibizumab injections. *J Ocul Pharmacol Ther.* 2010;26:105–110. doi:10.1089/jop.2009.0076
9. Bakri SJ, McCannel CA, Edwards AO, Moshfeghi DM. Persistent ocular hypertension following intravitreal ranibizumab. *Graefes Arch Clin Exp Ophthalmol.* 2008;246:955–958. doi:10.1007/s00417-008-0819-2
10. Good TJ, Kimura AE, Mandava N, Kahook MY. Sustained elevation of intraocular pressure after intravitreal injections of anti-VEGF agents. *Br J Ophthalmol.* 2011;95:1111–1114. doi:10.1136/bjo.2010.180729
11. Dedania VS, Bakri SJ. Sustained elevation of intraocular pressure after intravitreal anti-VEGF agents. What is the evidence? *Retina.* 2015;35:841–858.
12. Reis GSM, Grigg J, Chua B, et al. Incidence of intraocular pressure elevation following intravitreal ranibizumab (lucentis) for age-related macular degeneration. *J Curr Glaucoma Pract.* 2017;11(1):3–7. doi:10.5005/jp-journals-10008-1213
13. Hoang QV, Tsuang AJ, Gelman R, et al. Clinical predictors of sustained intraocular pressure elevation due to intravitreal anti-vascular endothelial growth factor therapy. *Retina.* 2013;33:179–187. doi:10.1097/IAE.0b013e318261a6f7

14. Yannuzzi NA, Patel SN, Bhavsar KV, Sugiguchi F, Freund KB. Predictors of sustained intra-ocular pressure elevation in eyes receiving intravitreal anti-vascular endothelial growth factor therapy. *Am J Ophthalmol*. 2014;158(2):319–327. doi:10.1016/j.ajo.2014.04.029
15. Grzybowski A, Kanclerz P. Early postoperative intraocular pressure elevation following cataract surgery. *Curr Opin Ophthalmol*. 2019;30(1):56–62. doi:10.1097/ICU.0000000000000545
16. Kim GN, Han YS, Chung IY, Seo SW, Park JM, Yoo JM. Effect of dorzolamide/timolol or brinzolamide/timolol prophylaxis on intravitreal anti-VEGF injection-induced intraocular hypertension. *Semin Ophthalmol*. 2013;28(2):61–67. doi:10.3109/08820538.2012.754479
17. El Chehab H, Le Corre A, Agard E, Ract-Madoux G, Coste O, Dot C. Effect of topical pressure-lowering medication on prevention of intraocular pressure spikes after intravitreal injection. *Eur J Ophthalmol*. 2013;23(3):277–283. doi:10.5301/ejo.5000159
18. Theoulakis PE, Lepidas J, Petropoulos IK, Livieratou A, Brinkmann CK, Katsimpris JM. Effect of brimonidine/timolol fixed combination on preventing the short-term intraocular pressure increase after intravitreal injection of ranibizumab. *Klin Monbl Augenheilkd*. 2010;227(4):280–284. doi:10.1055/s-0029-1245201
19. Ozcaliskan S, Ozturk F, Yilmazbas P, Beyazyildiz O. Effect of dorzolamide-timolol fixed combination prophylaxis on intraocular pressure spikes after intravitreal bevacizumab injection. *Int J Ophthalmol*. 2015;8(3):496–500.
20. Frenkel MPC, Haji SA, Frenkel REP. Effect of prophylactic intraocular pressure-lowering medication on intraocular pressure spikes after intravitreal injections. *Arch Ophthalmol*. 2010;128(12):1523–1527. doi:10.1001/archophthol.2010.297
21. Myers L, Almeida D, Abramoff M. *Intravitreal Injection Technique. A Primer for Ophthalmology Residents and Fellows*. Iowa City: VAMC; 2015.
22. Koss MJ, Bolz M, Augustin AJ, et al. Safety, efficacy and protective aspects of an add-on paracentesis during intravitreal injections. *Klin Monbl Augenheilkd*. 2019. doi:10.1055/a-0972-9747
23. Saxena S, Lai TY, Koizumi H, et al. Anterior chamber paracentesis during intravitreal injections in observational trials: effectiveness and safety and effects. *Int J Retina Vitreous*. 2019;6(5):8. doi:10.1186/s40942-019-0157-z
24. Meyer CH, Rodrigues EB, Michels S, et al. Incidence of damage to the crystalline lens during intravitreal injections. *J Ocul Pharmacol Ther*. 2010;26:491–495. doi:10.1089/jop.2010.0045
25. Morlet N, Young S. Prevention of intraocular pressure rise following intravitreal injection. *Br J Ophthalmol*. 1993;77:572–573. doi:10.1136/bjo.77.9.572
26. Lee J, Hwang H, Park YS, Lee YJ, Lee BR. Preoperative ocular massage to lower the immediate intraocular pressure spike following intravitreal triamcinolone acetate injection. *Invest Ophthalmol Vis Sci*. 2005;46:1454.
27. Gregori NZ, Weiss MJ, Goldhardt R, et al. Ocular decompression with cotton swabs lowers intraocular pressure elevation following intravitreal injection. *J Glaucoma*. 2014;23(8):508–512. doi:10.1097/IJG.0b013e318294865c
28. Qureshi NA, Mansoor H, Ahmad S, Zafar S, Asif M. Reducing intraocular-pressure spike after intravitreal-bevacizumab injection with ocular decompression using a sterile cotton swab soaked in proparacaine 0,5%: a quasi-experimental study. *Taiwan J Ophthalmol*. 2016;6(2):75–78. doi:10.1016/j.tjo.2015.12.003
29. Meyer CH, Liu Z, Brinkmann C, Rodrigues EB, Helb HM. Accuracy, precision and repeatability in preparing the intravitreal dose with a 1.0-cc syringe. *Acta Ophthalmol*. 2012;90:e165–e166. doi:10.1111/j.1755-3768.2010.02072.x
30. Ali M, Akhtar F. Ocular digital massage after trabeculectomy. *J Coll Phys Surg Pak*. 2011;21(11):676–679.
31. Segrest DR, Ellis PP. Iris incarceration associated with digital ocular massage. *Ophthalmic Surg*. 1981;12:349–351.
32. Miller GR, Kurstin J. Ruptured filtering bleb after ocular massage. *Arch Ophthalmol*. 1966;76:363. doi:10.1001/archophth.1966.03850010365011
33. Baldassare RD, Brunette I, Desjardins DC, Amyot M. Corneal ectasia secondary to excessive ocular massage following trabeculectomy with 5-fluorouracil. *Can J Ophthalmol*. 1996;31:252–254.
34. Tang J, Salzman IJ, Sable MD. Traumatic cataract formation after vigorous ocular massage. *J Cataract Refract Surg*. 2003;1641-2:25.
35. Ruderman JM, Jampol LM, Krueger DM. Visual loss caused by sub-retinal hemorrhage and rupture of Bruch's membrane after digital ocular massage. *Am J Ophthalmol*. 1988;106:493–494. doi:10.1016/0002-9394(88)90894-X
36. Kim KS, Jee D. Effect of the Honan intraocular pressure reducer on intraocular pressure increase following intravitreal injection using the tunneled scleral technique. *Jpn J Ophthalmol*. 2011;55(6):632–637. doi:10.1007/s10384-011-0088-1
37. Prince J, Fleischman D. Immediate manifestation of ocular decompression retinopathy following anterior chamber paracentesis. *Case Rep Ophthalmol*. 2019;10(2):287–291. doi:10.1159/000501846

Clinical Ophthalmology

Publish your work in this journal

Clinical Ophthalmology is an international, peer-reviewed journal covering all subspecialties within ophthalmology. Key topics include: Optometry; Visual science; Pharmacology and drug therapy in eye diseases; Basic Sciences; Primary and Secondary eye care; Patient Safety and Quality of Care Improvements. This journal is indexed on PubMed

Submit your manuscript here: <https://www.dovepress.com/clinical-ophthalmology-journal>

Dovepress

Central and CAS, and is the official journal of The Society of Clinical Ophthalmology (SCO). The manuscript management system is completely online and includes a very quick and fair peer-review system, which is all easy to use. Visit <http://www.dovepress.com/testimonials.php> to read real quotes from published authors.