

## Endoscopic Resection of Peroneus Quartus

Tun Hing Lui, M.B.B.S.(HK), F.R.C.S.(Edin), F.H.K.A.M., F.H.K.C.O.S., and  
Ho Ming Li, M.B.Ch.B.



**Abstract:** The peroneus quartus is the most common supernumerary muscle of the foot and ankle. It can be symptomatic and associated with splits or tears in the peroneus brevis, subluxation or dislocation of the peroneal tendon, tendinous calcification, chronic peroneal compartment syndrome, and painful hypertrophy of the retrotrochlear eminence. The purpose of this Technical Note was to describe the details of endoscopic resection of the peroneus quartus. This technique has the advantages of better cosmetic results, less pain, less surgical trauma, and the possibility of dealing with associated pathologies endoscopically.

The superior peroneal tunnel has the superior peroneal retinaculum forming its roof. The retro-malleolar groove of the fibula and the lower part of the posterior intermuscular septum of the leg form the osseous and soft-tissue components of the floor of the tunnel.<sup>1</sup> Besides the peroneal longus and brevis tendons, peroneus brevis muscle fibers are the most frequent additional contents inside the tunnel, followed by the peroneus quartus.<sup>1</sup> The peroneus quartus is the most frequent aberrant muscle around the foot and ankle, with a reported incidence between 6.6% and 22%.<sup>2-4</sup> The frequent occurrence of this muscle in humans is suggestive of a progressive evolutionary change to evert the foot to assume a bipedal gait.<sup>5,6</sup> If present, the peroneus quartus passes as a slender tendon through the tunnel, posteromedial to the peroneus brevis tendon.<sup>1</sup> Sometimes, fleshy muscle fibers of this muscle accompany the tendon.<sup>1</sup> The peroneus

quartus muscle fibers most commonly arise from the peroneus brevis, and its tendon inserts into the retrotrochlear eminence of the calcaneus.<sup>4,7</sup> Other reported origins are the lower part of the lateral surface of the fibula and the posterior intermuscular septum.<sup>5,6</sup> Other reported insertion sites include the cuboid, fifth metatarsal base, peroneus longus tendon, peroneus brevis tendon, and peroneal tubercle.<sup>7</sup> Associated pathologies are splits or tears in the peroneus brevis; subluxation or dislocation of the peroneal tendon with a thin, lax superior peroneal retinaculum; tendinous calcification; chronic peroneal compartment syndrome; and painful hypertrophy of the retrotrochlear eminence.<sup>4-6,8</sup> A flat or convex distal fibula and the presence of pes cavus are other contributing factors to peroneal tendinopathy.<sup>4</sup> The presenting symptoms include chronic lateral ankle pain, clicking or snapping, peroneal tendon instability, or lateral ankle instability.<sup>2,3,5,6,9,10</sup> Besides the associated pathology, the peroneus quartus is of note because of its potential use to reconstruct the retromalleolar groove and to act as a strap to stabilize the peroneal tendons in case of recurrent peroneal tendon dislocation.<sup>4,10</sup>

Surgical excision is a favorable treatment option for the symptomatic peroneus quartus muscle.<sup>2,3</sup> Peroneal tenodesis has been suggested to detect the presence of the muscle and assess the associated pathology.<sup>9</sup> Endoscopic resection of the peroneus quartus has also been reported.<sup>6,11,12</sup> The purpose of this Technical Note was to describe the details of endoscopic resection of the peroneus quartus. This endoscopic approach is indicated for the symptomatic peroneus quartus muscle. It is contraindicated if there is another cause of the lateral ankle pain or if reconstructive surgery using the peroneus quartus tendon is planned (Table 1).

From the Department of Orthopaedics and Traumatology, North District Hospital, Sheung Shui; and Department of Orthopaedics and Traumatology, Kwong Wah Hospital, Yau Ma Tei, China.

The authors report that they have no conflicts of interest in the authorship and publication of this article. Full ICMJE author disclosure forms are available for this article online, as [supplementary material](#).

Received August 3, 2019; accepted August 28, 2019.

Address correspondence to Tun Hing Lui, M.B.B.S.(HK), F.R.C.S.(Edin), F.H.K.A.M., F.H.K.C.O.S., Department of Orthopaedics and Traumatology, North District Hospital, 9 Po Kin Road, Sheung Shui, NT, Hong Kong SAR, China. E-mail: [luithderek@yahoo.co.uk](mailto:luithderek@yahoo.co.uk)

© 2019 by the Arthroscopy Association of North America. Published by Elsevier. This is an open access article under the CC BY-NC-ND license (<http://creativecommons.org/licenses/by-nc-nd/4.0/>).

2212-6287/19955

<https://doi.org/10.1016/j.eats.2019.08.007>

**Table 1.** Indication and Contraindications of Endoscopic Resection of Peroneus Quartus

Indication
Symptomatic peroneus quartus muscle
Contraindications
There is another cause of the lateral ankle pain.
Reconstructive surgery using the peroneus quartus tendon is planned.

## Technique

### Preoperative Planning and Patient Positioning

The patient may complain of retrofibular pain or peroneal tendon subluxation or dislocation. The presence of the peroneus quartus muscle is confirmed by magnetic resonance imaging.

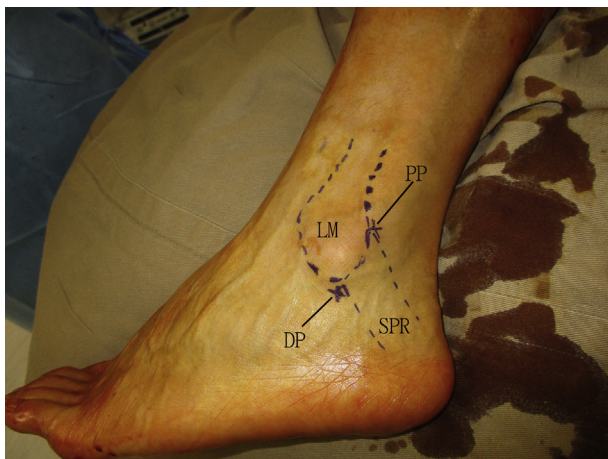The patient is placed in the lateral position. A thigh tourniquet is applied to provide a bloodless operative field. A 2.7-mm, 30° arthroscope (Henke Sass Wolf, Tuttlingen, Germany) is used for this procedure. Fluid inflow is by gravity, and no arthro-pump is used.

### Portal Placement

This procedure is performed via the proximal and distal portals used for peroneal tendoscopy. The distal portal is close to the lateral malleolar tip, and the proximal portal is 2 to 3 cm proximal to the distal portal. These portals roughly span the superior peroneal retinaculum (Fig 1). Three-millimeter incisions are made at the portal sites.

### Identification and Dissection of Peroneus Quartus

The distal portal is the viewing portal, and the proximal portal is the working portal. The peroneal tendons are examined for any pathology via an arthroscopic



**Fig 1.** Endoscopic resection of peroneus quartus of left ankle. The patient is in the lateral position. This procedure is performed via the proximal portal (PP) and distal portal (DP) used for peroneal tendoscopy. The DP is close to the lateral malleolar tip, and the PP is 2 to 3 cm proximal to the DP. These portals roughly span the superior peroneal retinaculum (SPR). (LM, lateral malleolus.)

probe (Acufex; Smith & Nephew, Andover, MA). Thereafter, the posterior part of the peroneal tendon sheath is released by an arthroscopic shaver (Dyonics; Smith & Nephew) to expose the peroneus quartus muscle (Fig 2). The tendon sheath is released proximally to expose the origin of the muscle.

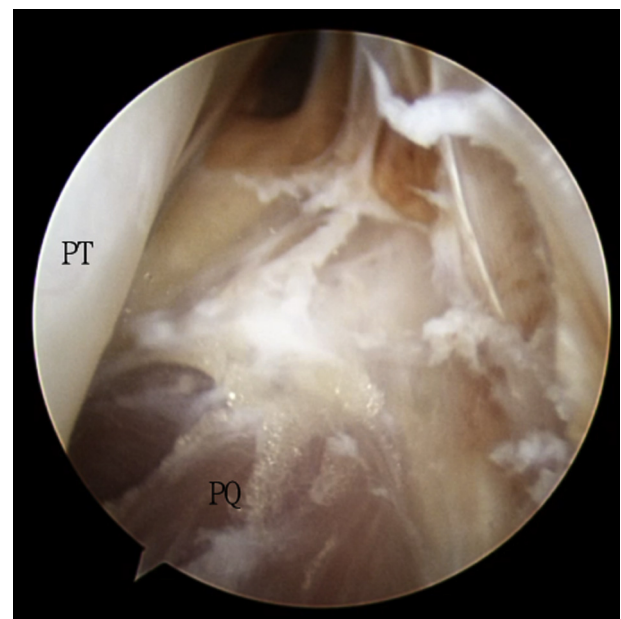
The arthroscope is switched to the proximal portal and inserted distally to the level of the peroneal tubercle. The arthroscope is then withdrawn gradually until the peroneal quartus muscle is seen. The peroneal tendon sheath is released distally to the calcaneal insertion of the peroneus quartus muscle by means of the arthroscopic shaver and SuperCut scissors (Stille, Lombard, IL) (Fig 3).

### Retraction of Peroneal Tendons

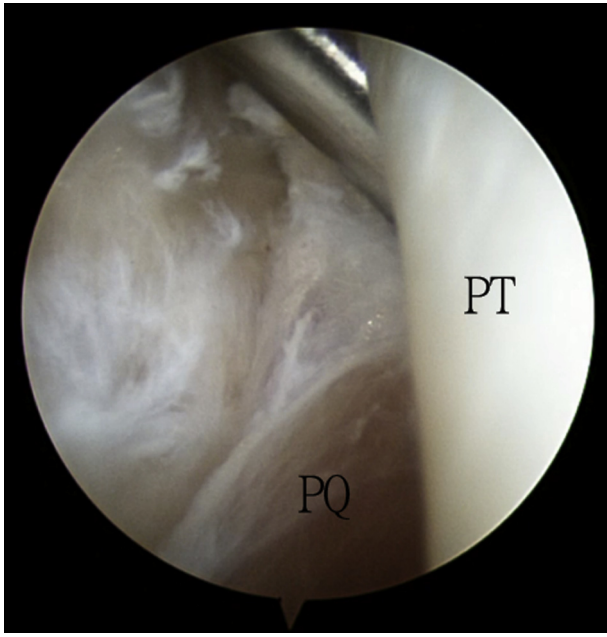
The distal portal is the viewing portal. In the case of peroneus longus and brevis tendons that are able to be subluxated, the tendons are displaced anteriorly and splinted by a percutaneous 1.6-mm K-wire (Zimmer, Warsaw, IN) (Fig 4). This increases the distance between the tendons and the peroneus quartus muscle and reduces the risk of iatrogenic tendon injury during resection of the peroneus quartus muscle.

### Resection of Peroneus Quartus

The distal portal is the viewing portal. The proximal half of the peroneus quartus muscle is resected with the shaver via the proximal portal (Fig 5). Thereafter, the arthroscope is switched to the proximal portal, and the remaining peroneus quartus muscle and tendon are

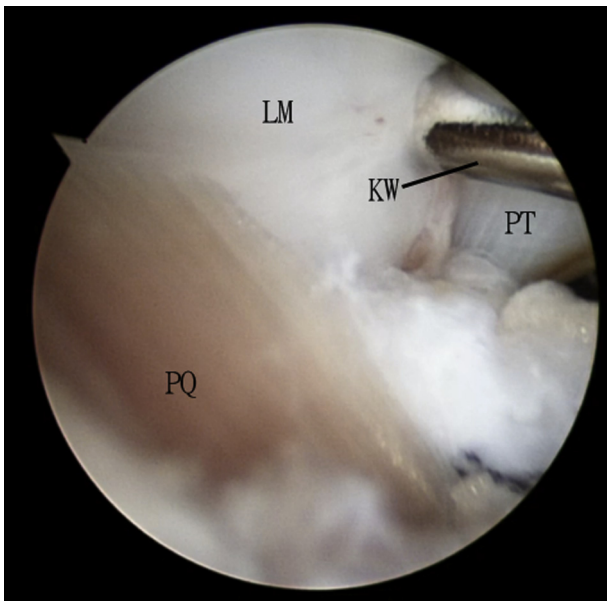


**Fig 2.** Endoscopic resection of peroneus quartus (PQ) of left ankle. The patient is in the lateral position. The distal portal is the viewing portal. The PQ muscle is exposed after the posterior part of the peroneal tendon (PT) sheath is released.

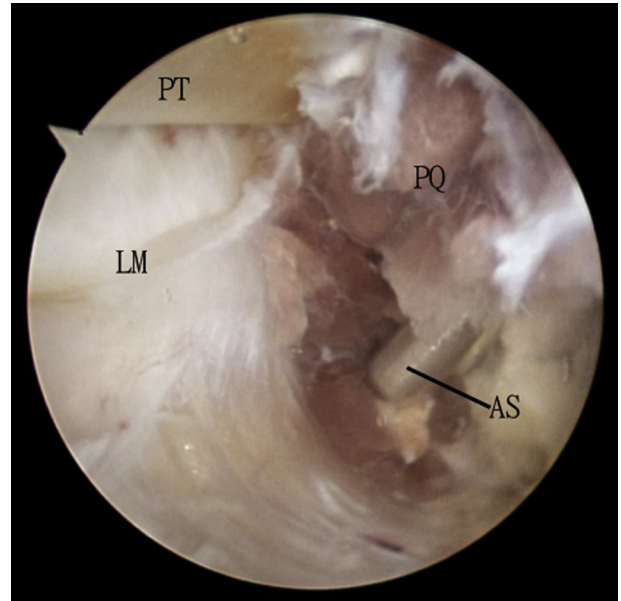


**Fig 3.** Endoscopic resection of peroneus quartus (PQ) of left ankle. The patient is in the lateral position. The proximal portal is the viewing portal, and the distal portal is the working portal. The exposed PQ muscle is identified and traced distally. (PT, peroneal tendons.)

resected with the shaver via the distal portal ([Fig 6](#), [Table 2](#), [Video 1](#)). If instability of the peroneal tendons is noted, endoscopic reconstruction of the superior peroneal retinaculum can be performed via the same portals.<sup>13,14</sup>

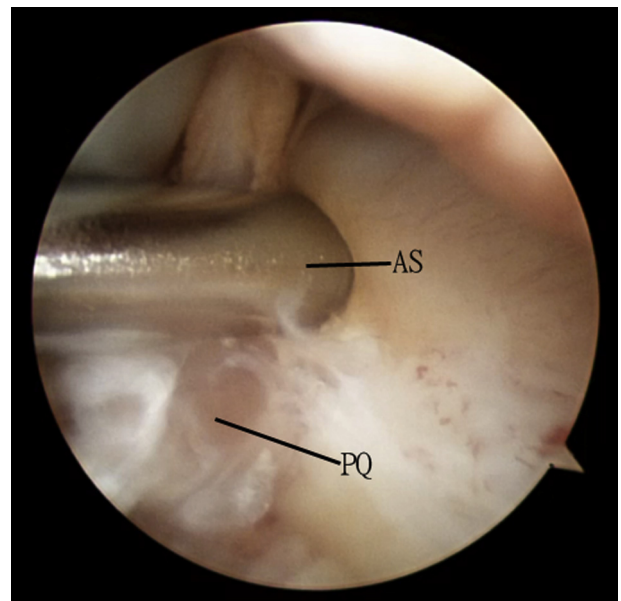


**Fig 4.** Endoscopic resection of peroneus quartus (PQ) of left ankle. The patient is in the lateral position. The distal portal is the viewing portal. The peroneal tendons (PT) are displaced anteriorly and splinted with a K-wire (KW) inserted into the lateral malleolus (LM).



**Fig 5.** Endoscopic resection of peroneus quartus (PQ) of left ankle. The patient is in the lateral position. The distal portal is the viewing portal, and the proximal portal is the working portal. The PQ muscle is resected with an arthroscopic shaver (AS). (LM, lateral malleolus; PT, peroneal tendons.)

Postoperatively, free mobilization is allowed if retinaculum reconstruction is not performed. If retinaculum reconstruction is performed, the ankle is immobilized in a short leg cast for 3 weeks. Thereafter, the patient is instructed to perform ankle dorsiflexion



**Fig 6.** Endoscopic resection of peroneus quartus (PQ) of left ankle. The patient is in the lateral position. The proximal portal is the viewing portal, and the distal portal is the working portal. The PQ muscle is resected with an arthroscopic shaver (AS).



**Table 2.** Pearls and Pitfalls of Endoscopic Resection of Peroneus Quartus

<b>Pearls</b>
Preoperative magnetic resonance imaging is useful to study the spatial relation between the peroneus quartus muscle and the surrounding normal structures.
K-wire splintage of the anteriorly displaced peroneal tendons can increase the working space and reduce the risk of injury to the peroneal tendons.
<b>Pitfalls</b>
The release of the tendon sheath should be performed posterior to the peroneal tendons to avoid iatrogenic injury to the superior peroneal retinaculum resulting in peroneal tendon instability.
Percutaneous insertion of the K-wire bears the risk of injury to the sural nerve.

exercises in an Aircast (DJO, Vista, CA). Circumduction of the foot should be avoided for 3 months.<sup>14</sup>

### Discussion

In the illustrated case, the peroneus quartus is separated from the peroneal tendons by a fibrous septum. This needs to be incised open before the muscle is exposed. The endoscopic release also has the effect of a fasciotomy of the peroneal compartment, which may have the beneficial effect of reducing the raised peroneal compartment pressure associated with the peroneus quartus.<sup>8</sup>

In this case, the peroneal tendons can be subluxated to increase the working space, and the endoscopic procedure can be performed purely within the superior peroneal tunnel. In cases in which the visual field is obscured by the crowding effect of the peroneus quartus or low-lying muscle fibers in the proximal portion of the superior peroneal tunnel, an extra-sheath peroneal tendoscopy can be performed.<sup>12</sup> The muscle is debulked before the surgeon can gain access to the superior peroneal tunnel.

The described endoscopic approach has the advantages of better cosmetic results, less pain, less surgical trauma, and the possibility of dealing with associated pathologies (e.g., peroneal tendon tear or instability) endoscopically.<sup>6,9,13-16</sup> The potential risks of this

**Table 3.** Advantages and Risks of Endoscopic Resection of Peroneus Quartus

<b>Advantages</b>
Better cosmetic results
Less pain
Less surgical trauma
Possibility of dealing with associated pathologies (e.g., peroneal tendon tear or instability) endoscopically
<b>Risks</b>
Injury to peroneal tendons
Injury to superior peroneal retinaculum
Injury to sural nerve

technique include injury to the peroneal tendons, superior peroneal retinaculum, and sural nerve (Table 3). This technique is not technically demanding and can be attempted by the average foot and ankle arthroscopist.

### References

- Athavale SA, Swathi Vangara SV. Anatomy of the superior peroneal tunnel. *J Bone Joint Surg Am* 2011;93:564-571.
- Chang SH, Matsumoto T, Okajima K, Naito M, Hirose J, Tanaka T. Heterotopic ossification of the peroneus longus tendon in the retromalleolar portion with the peroneus quartus muscle: A case report. *Case Rep Orthop* 2018;2018:7978369.
- Trono M, Tueche S, Quintart C, Libotte M, Baillon J. Peroneus quartus muscle: A case report and review of the literature. *Foot Ankle Int* 1999;20:659-662.
- Zammit J, Singh D. The peroneus quartus muscle. Anatomy and clinical relevance. *J Bone Joint Surg Br* 2003;85-B:1134-1137.
- Athavale SA, Gupta V, Kotgirwar S, Singh V. The peroneus quartus muscle: Clinical correlation with evolutionary importance. *Anat Sci Int* 2012;87:106-110.
- Vega J, Golano P, Dalmau A, Viladot R. Tendoscopic treatment of intrasheath subluxation of the peroneal tendons. *Foot Ankle Int* 2011;32:1147-1151.
- Cecava ND, Campbell SE. Peroneus brevis tendon variant insertion on the calcaneus. *J Radiol Case Rep* 2015;9:22-29.
- Wenning M, Heitner AH, Ulrich M, Paul J, Rist HJ. M. peroneus quartus causing chronic peroneal compartment syndrome in a runner treated by endoscopic fasciotomy: A case report. *J Foot Ankle Surg* 2019;58:653-656.
- Opdam KT, van Dijk PA, Stufkens SA, van Dijk CN. The peroneus quartus muscle in a locking phenomenon of the ankle: A case report. *J Foot Ankle Surg* 2017;56:108-111.
- Bilgili MG, Kaynak G, Botanlioglu H, et al. Peroneus quartus: Prevalance and clinical importance. *Arch Orthop Trauma Surg* 2014;134:481-487.
- Kassim MM, Rosenfeld P. Tendoscopic debridement of peroneus quartus muscle for chronic lateral ankle pain: A case report. *Foot Ankle Int* 2012;33:1024-1026.
- Lui TH. Tendoscopic resection of low-lying muscle belly of peroneus brevis or quartus. *Foot Ankle Int* 2012;33:912-914.
- Lui TH. Endoscopic peroneal retinaculum reconstruction. *Knee Surg Sports Traumatol Arthrosc* 2006;14:478-481.
- Hau WWS, Lui TH. Endoscopic superior peroneal retinaculum reconstruction. *Arthrosc Tech* 2018;7:e45-e51.
- Lui TH. Endoscopic management of recalcitrant retrofibular pain without peroneal tendon subluxation or dislocation. *Arch Orthop Trauma Surg* 2012;132:357-361.
- de Leeuw PAJ, van Dijk CN, Golano P. A 3-portal endoscopic groove deepening technique for recurrent peroneal tendon dislocation. *Tech Foot Ankle Surg* 2008;7:250-256.