

Metastases of head and neck squamous cell carcinoma to soft tissue of fingertips

A 55-year-old male, diagnosed case of squamous cell carcinoma of the pyriform sinus stage T4N1M0, who completed concurrent chemoradiotherapy 5 months back, presented with painful firm, globular swelling of the tips of the left thumb and fourth finger [Figure 1]. On evaluation, there was no lesion identified at the primary site. Computed tomography of the thorax showed multiple lung metastases. Biopsy of the finger swelling showed deposits of squamous cell carcinoma [Figure 2]. However, after the biopsy, the patient had profuse bleeding from the biopsy site that was managed temporarily with adrenaline packs. The patient was started on palliative chemotherapy with paclitaxel and carboplatin following which his bleeding subsided and after 2 cycles the swellings showed reduction in the size.

Acrometastases arising from head and neck primaries, especially to the soft tissues of digits are very rare. The most common primary organs involved are lung, breast, and kidney. Caution has to be taken while performing biopsies as these soft-tissue metastases have a high bleeding tendency.

Financial support and sponsorship

Nil.

Conflicts of interest

There are no conflicts of interest.

Nishitha Shetty, Sameer M. S¹, Hilda Fernandes², Dinesh Shet

Departments of Medical Oncology, ¹Medicine and ²Pathology, Father Muller Medical College Hospital, Mangalore, Karnataka, India

Address for correspondence:

Dr. Nishitha Shetty,
Department of Medical Oncology, Father Muller Medical College
Hospital, Kankanady, Mangalore, Karnataka, India.
E-mail: drnishithashetty@gmail.com

This is an open access article distributed under the terms of the Creative Commons Attribution-NonCommercial-ShareAlike 3.0 License, which allows others to remix, tweak, and build upon the work non-commercially, as long as the author is credited and the new creations are licensed under the identical terms.

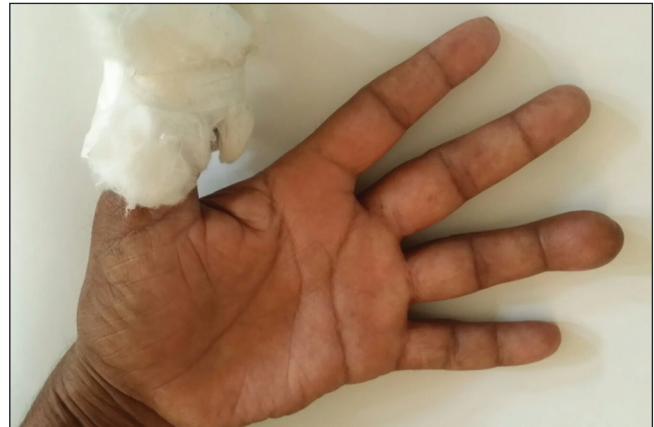

Figure 1: Globular swelling of the fingertips with adrenaline pack at biopsy site

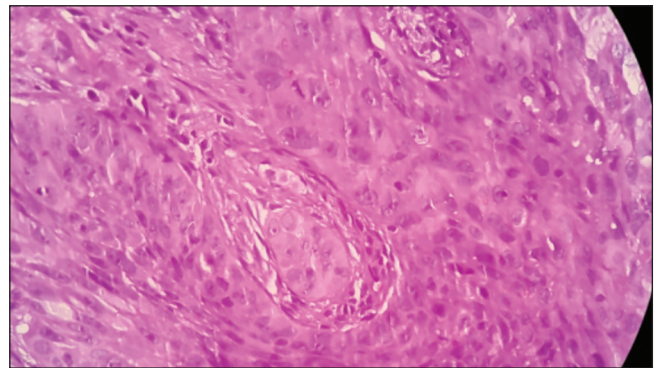


Figure 2: Biopsy showing squamous cell carcinoma

Access this article online

Quick Response Code:



Website:

www.ijmpo.org

DOI:

10.4103/0971-5851.180140

How to cite this article: Shetty N, Sameer MS, Fernandes H, Shet D. Metastases of head and neck squamous cell carcinoma to soft tissue of fingertips. *Indian J Med Paediatr Oncol* 2016;37:122.