

Voiding dysfunction after repair of giant trigonal vesicovaginal or urethrovesicovaginal fistulae: A need for long-term follow-up

Mayank Mohan Agarwal, Sathishkumar Mothilal Raamy, Ravimohan Mavuduru, Arup K. Mandal, Shrawan K. Singh

Department of Urology, Postgraduate Institute of Medical Education and Research, Chandigarh, India

ABSTRACT

Introduction: Urodynamic findings of lower urinary tract of women presenting with voiding dysfunction after successful repair of complex trigonal vesicovaginal fistulas at our institute are presented.

Materials and Methods: In this retrospective case series, women presenting with voiding dysfunction after successful repair of obstetric fistulae were evaluated. In addition of standard clinical evaluation with history and clinical examination, all underwent kidney-ureter-bladder ultrasonography, renal function test, urine culture, and multichannel urodynamics. The latter consisted of free uroflowmetry, filling and voiding cystometry.

Results: Five women (median age 35 years; range 30–45) presented with difficulty in voiding after the successful repair; two presented within 1 year and 3 after 10 years. The latter three presented with bilateral hydronephrosis; one of these had chronic kidney disease (CKD) grade IV at presentation. Urodynamics (UDS) of all patients revealed poor detrusor compliance (median 11 ml/cm H₂O; range 5–22), high-end filling detrusor pressures (median 41 cm H₂O; range 11–46) and no detrusor overactivity. All patients attempted voiding with abdominal straining; with little contribution of detrusor contraction (median 6 cm H₂O; range 0–9). Two patients could not void during the study, one with Tanagho reconstruction and another with CKD.

Conclusion: Even after successful repair, patients with complex trigonal or urethra-vesicovaginal fistulae warrant indefinite long-term follow-up for voiding dysfunction in view of possibility of developing poorly compliant bladder.

Key words: Detrusor compliance, giant vesicovaginal fistula, neurogenic bladder

INTRODUCTION

Obstetric fistulae are typically trigonal vesicovaginal fistulae (VVF) and urethrovesicovaginal (UVVF) fistulae; whereas, gynaecological fistulae are typically supratrigonal VVF, uterovesical or ureterovaginal fistulae. Obstetric fistulae are typically more complex

to repair, often technically challenging, in view of location, proximity to crucial structures (e.g., bladder neck, continence mechanism, ureteral orifices), local scarring, and status of local tissue for interposition. The success rate in terms of fistula closure ranges from 81% to 88% in obstetric fistulae.^[1,2] Even after successful closure of these complex fistulae (in one or more attempts), there are certain complications which tend to persist, for example, urethral urinary incontinence, gynecostria, and bladder dysfunction.^[3] Studies on bladder dysfunction in this setting are scarce. We present urodynamic evidence of bladder dysfunction in our case series of five women.

MATERIALS AND METHODS

In this retrospective case series, women presenting with voiding dysfunction after repair of obstetric fistulae were evaluated. In addition of standard clinical evaluation with history and clinical examination, all underwent ultrasonography, renal function test, urine culture, and multichannel urodynamics. The latter consisted of filling

For correspondence: Dr. Shrawan Kumar Singh, Department of Urology, Level II, B- Block, Nehru Hospital, Postgraduate Institute of Medical Education and Research, Sector 12, Chandigarh – 160 012, India.

Email: shrawansingh2002@yahoo.com

Access this article online

Quick Response Code: 	Website: www.indianjurol.com
	DOI: 10.4103/0970-1591.105751

cystometry and voiding pressure-flow analysis using “Solar Silver” digital urodynamic apparatus (Medical Measurement Systems, Enschede, the Netherlands). Performance and interpretation of urodynamics was in accordance with Good Urodynamics Practice guidelines of International Continence Society.^[4] Sterile normal saline (0.9%, w/v) was used as the filling medium and infused at physiological filling rate (¼th of body weight). Filling was stopped after sensation of “strong desire” when the patient felt she could no longer delay micturition (marked as maximum cystometric capacity; MCC). Filling detrusor compliance (DC) was calculated using the formula $DC = MCC/end\ filling\ Pdet$. Urine production during UDS was taken into consideration in calculation of actual MCC.

RESULTS

Total 63 women had undergone abdominal/vaginal repair of complex trigonal VVF or UVVF during 1992 to 2011. Of these four failed in first attempt, three of whom were salvaged with repeat repair; one patient underwent continent cutaneous urinary diversion. Five women (median age 35 years; range 30–45) who had undergone successful repair(s) of large (>3 cm) or multiple trigonal or urethrovesicovaginal fistula [Figure 1a] presented with difficulty in voiding, straining at micturition, frequency, urgency, and nocturia. The presentation was within 1 year in two and more than 10 years in three. The details are presented in Table 1. The latter three women had bilateral hydronephrosis [Figure 1b] with thick-walled bladder; one of these (patient A) had developed renal failure at presentation (creatinine 4.5 mg/dl). None of these women had any disease process or previous pelvic/spinal surgery, urinary tract tuberculosis or pelvic radiation to confound for the LUT symptomatology.

Median cystometric capacity was 276 ml (range 201–333 ml); end filling detrusor pressure 31 cm H₂O (11–46 cm H₂O), and detrusor compliance 14.2 ml/cm H₂O (5–28 ml/cm H₂O). None of them had evidence of detrusor overactivity. Low compliance was deemed to be due to loss of elasticity in view of persistence of high PdetEndfill despite stopping flow for at least 1 minute. Two of them could not void during the study and the others (patient B, D and E) voided most of bladder fluid with abdominal straining [Figure 2a]. None of them had any active rise in detrusor pressure during filling phase. Patient A was found to have a moderate capacity bladder with grade V vesicoureteral reflux with capacious upper tracts (estimated to have ~200 ml capacity). Therefore, her corrected MCC was 276 ml and compliance 16 ml/cm H₂O [Figure 2b].

DISCUSSION

All the five patients had some features in common; all fistulae resulted from prolonged labor, were large trigonal,

or urethrovesicovaginal. All patients developed clinical symptoms of obstructive voiding with straining, urodynamics showed poor compliance, absence of DO, and straining pattern of voiding.

Complex VVF repair are very demanding from surgical point of view. Obstetric fistulas are very large and etiology very different from other fistulas.^[5] These result from the pressure exerted by the presenting part of the fetus during

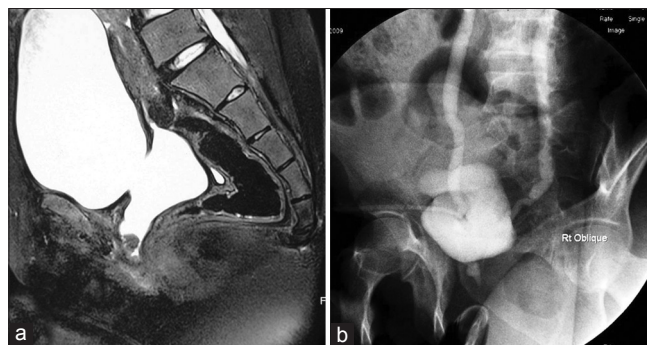


Figure 1: (a) Patient E: MRI (preoperative)—large trigonal fistula extending till bladder neck with moderate capacity bladder (b) Patient B: VCUG (after fistula repair)—bilateral reflux with partially open bladder neck and non-relaxing external sphincter

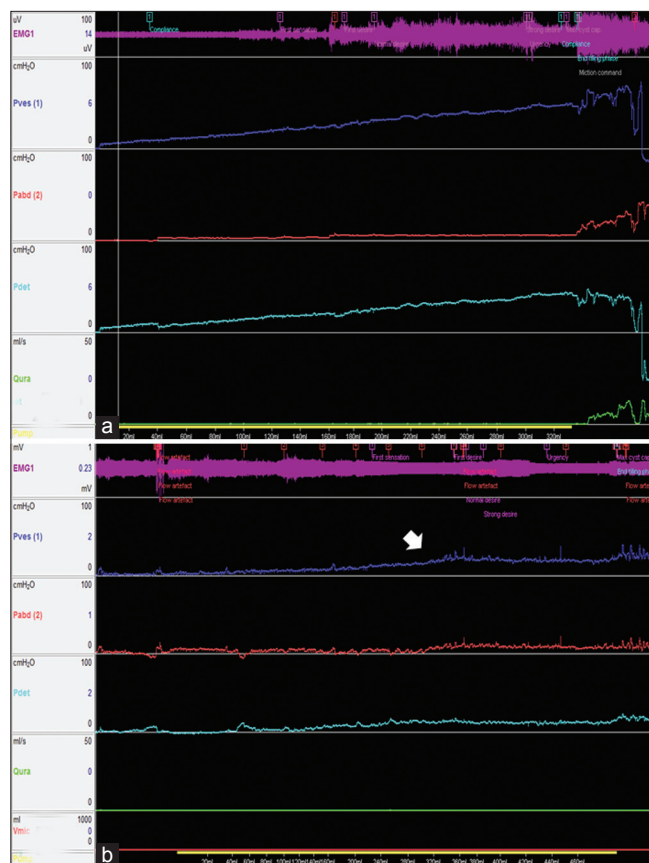


Figure 2: (a) Patient B: UDS—poor compliance; voiding solely with abdominal straining against a non-relaxing pelvic floor (EMG) (b) Patient AU DS—Pdet showing plateau-pattern half-way during filling (block-arrow) corresponding with high-grade reflux giving pseudo-impression of compliance improvement

Table 1: Clinical and urodynamic characteristics of the patients

	Patient A	Patient B	Patient C	Patient D	Patient E
Age (years)	34	36	45	30	30
Extent of genitourinary fistula	Multiple trigonal and supratrigonal	Large trigonal with LUO involvement	Complete loss of urethra, distal trigone	Large trigonal extending to bladder neck	Large trigonal extending to bladder neck
Year of surgery	1994	1996	1998	2008	2008
Surgery	Anatomical repair	Anatomical repair with left ureteral reimplantation	Tanagho urethral reconstruction	3 vaginal repairs	Abdomino-vaginal repair
Urodynamics at presentation with voiding dysfunction					
Filling					
FS	225	130	75	51	121
FD	350	180	130	136	161
ND	367	200	190	173	198
SD	387	300	210	225	304
MCC	276*	333	210	241	308
DO	-	-	-	-	-
Pdet. endfill	17	44	46	11	38
Compliance	16*	8	5	22	8
Voiding					
Pdetmax	23	44	46	20	42
PdetQmax	Did not void	40	Did not void	17	18
Active	6	0	0	9	6
Contraction					
Qmax	Did not void	11	Did not void	6	11
PVR	Did not void	22	Did not void	0	22
Abdominal straining	++	++	++	+	++

FS = First sensation, FD = First desire, ND = normal desire, SD = Strong desire, MCC = Maximum cystometric capacity, DO = Detrusor overactivity, Pdet = Detrusor pressure, Qmax = Maximum flow rate, PVR = Post void residual urine *This patient had grade V bilateral vesicoureteral reflux with estimated capacity of bilateral kidneys/ureters approximately 200 ml. Therefore, the MCC mentioned in the table are approximations after subtracting from measured MCC [i.e., 476 ml; Figure 1a]

a labor that sometimes lasts for several days. The level at which fetal descent is arrested determines the site of injury in the lower urinary tract.^[5] As the pressure reduces blood supply to the soft tissues of the pelvis, extensive vascular injury leads to tissue necrosis, and then to the formation of an often large fistula, with scarring and reduced vascularity in the tissues adjacent to the defect.^[5] Anatomical repair of large vesicovaginal fistulas cause problems of gynaecostria and incontinence.^[3] Treatment of acquired gynaecostria is difficult and requires major surgery again.

As depicted from the current series, the index scenario may lead to compromise in both storage as well as voiding phase of lower urinary tract, often threatening the upper tracts. This situation has not been well-elucidated in the literature. Two major defects that may contribute to storage phase dysfunction following fistula repair are (A) the intrinsic sphincter mechanism damage at the vesicourethral junction, and (B) changes in bladder function consisting of loss of capacity, contractility, sensation of filling, and reduction in size and compliance because of chronic

exposure to an unprotected environment.^[3] Sphincter injury due to necrosis of the urethra from prolonged pressure against the pubis may result in permanent denervation of the pudendal innervation of the urethra and/or soft tissue loss with reduction in muscle mass of the urethral sphincter similar to that seen in postmenopausal women, postradiation ischemic changes, or following extensive surgery.^[3] Moreover, partial denervation of bladder resulting from mobilization of bladder base often required in the giant fistula repair may contribute to diminished afferent input and loss of compliance akin to lower motor neuron LUT dysfunction.^[6,7] These factors must all be considered to adequately evaluate and treat urinary incontinence following obstetric fistula repair.

Voiding phase dysfunction akin to lower motor neuron type neurogenic, bladder may be explained also by denervation of bladder as well as bladder outlet, that is, an outlet which fails to relax and a bladder which fails to send sensory inputs to brain and to have coordinated contraction.^[7] In addition, urethral reconstruction using bladder tissue (as in one of our

patient) may also contribute to failure of urethral relaxation. However, we could not directly demonstrate urethral function in the current series, since we had not performed urethral pressure profilometry in any of the patients.

There have been studies explaining the urodynamic features after radical pelvic surgery. The studies have shown both filling phase and voiding phase abnormalities in the form of increased volume at first sensation and decreased compliance.^[6] Many patients needed abdominal straining to initiate voiding and maintain that. In our series all patients had abdominal straining. Detrusor overactivity which is believed to be unmasked by repair did not occur in any of the patients.

Conducting proper urodynamic evaluation in patients with giant vesicovaginal fistulae are difficult for obvious reasons. Since, there is a potential of development of voiding dysfunction after successful repair, these women need to be followed-up periodically for long-term with bladder diary, uroflowmetry, and measurement of post-void residual urine. The clinician should keep a low threshold for comprehensive urodynamic evaluation when suspecting voiding dysfunction with the aim to preserve upper tract function and appropriate rehabilitation of lower urinary tract.

CONCLUSION

Even after successful repair, patients with complex trigonal or urethra-vesicovaginal fistulae warrant potentially indefinite

long-term follow-up for voiding dysfunction in view of possibility of developing poor compliant and non-functional bladder with its attendant sequelae.

REFERENCES

1. Arrowsmith D. Genitourinary reconstruction in obstetric fistulas. *J Urol* 1994;152:403-6.
2. Elkins TE. Surgery for the obstetric vesicovaginal fistula: A review of 100 operations in 82 patients. *Am J Obstet Gynecol* 1994;170:1108-18.
3. Gutman RE, Dodson JL, Motswin JL. Complications of treatment of obstetric fistula in the developing world: Gynatresia, urinary incontinence, and urinary diversion. *Int J Gynecol Obstet* 2007;99:S57-64.
4. Schafer W, Abrams P, Liao L, Mattiasson A, Pesce F, Spangberg A, *et al.* Good urodynamic practices: Uroflowmetry, filling cystometry and pressure-flow studies. *Neurourol Urodyn* 2002;21:261-74.
5. Arrowsmith SD, Briggs ND, *et al.* Obstetric vesicovaginal fistula in the developing world. *Obstetrical and Gynaecological survey* 2007;60.
6. Jackson KS, Naik R. Pelvic floor dysfunction and radical hysterectomy. *Int J Gynecol Cancer* 2006;16:354-63.
7. Wein AJ, Dmochowski RR. Neuromuscular Dysfunction of the Lower Urinary Tract. In: Wein AJ, Kavoussi LR, Novick AC, *et al.* editors. *Campbell-Walsh Urology*. Vol. 3, 10th ed. Philadelphia: Elsevier-Saunders; 2012. p. 1909-46.

How to cite this article: Agarwal MM, Raamya SM, Mavuduru R, Mandal AK, Singh SK. Voiding dysfunction after repair of giant trigonal vesicovaginal or urethrovesicovaginal fistulae: A need for long-term follow-up. *Indian J Urol* 2012;28:405-8.

Source of Support: Nil, **Conflict of Interest:** None declared.

Author Help: Reference checking facility

The manuscript system (www.journalonweb.com) allows the authors to check and verify the accuracy and style of references. The tool checks the references with PubMed as per a predefined style. Authors are encouraged to use this facility, before submitting articles to the journal.

- The style as well as bibliographic elements should be 100% accurate, to help get the references verified from the system. Even a single spelling error or addition of issue number/month of publication will lead to an error when verifying the reference.
- Example of a correct style
Sheahan P, O'leary G, Lee G, Fitzgibbon J. Cystic cervical metastases: Incidence and diagnosis using fine needle aspiration biopsy. *Otolaryngol Head Neck Surg* 2002;127:294-8.
- Only the references from journals indexed in PubMed will be checked.
- Enter each reference in new line, without a serial number.
- Add up to a maximum of 15 references at a time.
- If the reference is correct for its bibliographic elements and punctuations, it will be shown as CORRECT and a link to the correct article in PubMed will be given.
- If any of the bibliographic elements are missing, incorrect or extra (such as issue number), it will be shown as INCORRECT and link to possible articles in PubMed will be given.