

Treatment algorithm in Vancouver B2 periprosthetic hip fractures: osteosynthesis vs revision arthroplasty

David González-Martín^{1,2}, José Luis Pais-Brito^{1,2},
Sergio González-Casamayor¹, Ayron Guerra-Ferraz¹, Jorge Ojeda-Jiménez^{1,2}
and Mario Herrera-Pérez^{1,2}

¹Orthopedic Surgery and Traumatology Service, Hospital Universitario de Canarias, Tenerife, Spain

²Universidad de La Laguna, Tenerife, Spain

Correspondence
should be addressed
to J L Pais-Brito

Email
paisbrito@gmail.com

- There is currently a debate on whether all Vancouver B2 periprosthetic hip fractures should be revised.
- The aim of our work was to establish a decision-making algorithm that helps to decide whether open reduction and internal fixation (ORIF) or revision arthroplasty (RA) should be performed in these patients.
- Relative indications in favour of ORIF are low-medium functional demand (Parker mobility score (PMS) <5), high anaesthetic risk (American Society of Anesthesiologists score (ASA) ≥ 3), many comorbidities (Charlson Comorbidity Index (CCI) ≥ 5), 1 zone fractured (VB2.1), anatomical reconstruction possible, and no prior loosening (hip pain).
- Relative indications in favour of RA are high functional demand (PMS ≥ 6), low anaesthetic risk (ASA < 3), few comorbidities (CCI < 5), fracture ≥ 2 zones (VB2.2), comminuted fractures, and prior loosening (hip pain).
- In cemented stems, those fractures with fully intact cement–bone interface, no stem subsidence into the cementiser, cement mantle anatomically reducible, and some partial stem-cement attachment can be safely treated with ORIF.

Keywords

- ▶ Vancouver B2 periprosthetic hip fracture
- ▶ osteosynthesis
- ▶ revisión arthroplasty

EFORT Open Reviews
(2022) 7, 533–541

Introduction

Periprosthetic hip fracture (PPHF) is a potentially devastating complication following total hip arthroplasty (THA), with high first-year mortality (15–20%) when occurring in frail elderly patients (1, 2, 3).

PPHFs are commonly classified according to the Vancouver system (2), which takes into account the fracture location, the stability of the implant, and the quality of the surrounding bone when deciding on the treatment of choice, without considering the patient's previous mobility level, the anaesthetic risk, comorbidities or fracture pattern. It subdivides PPHF into three types (2): A, B, and C. Type A fractures affect the greater (A_G) or lesser (A_L) trochanter. Type B are diaphyseal fractures around the prosthesis or immediately distal to it. There are three subtypes: B1 (stable stem), B2 (unstable or loose stem with good surrounding bone stock quality), and B3 (unstable or loose stem with inadequate surrounding bone stock). Type C fractures are distal to the stem (2). Although most orthopaedic surgeons use the Vancouver system as a reference, it is rarely used as a closed treatment algorithm (3, 4).

According to the authors of the Vancouver classification, (2) type A fractures can be treated either non-surgically or surgically, depending on the stability of the fracture; for type B1, the recommended treatment is open reduction and internal fixation (ORIF); for type B2, they recommend prosthetic replacement using a longer stem; type B3 fractures generally require replacement with more complex reconstructions and an implant. The recommended treatment for type C is the ORIF technique.

In VB2 PPHFs, the arthroplasty stability is compromised, and there is adequate bone stock. In general, long-stem revision arthroplasty, alone or supplemented by plate and/or allograft strut fixation, is widely considered the most effective solution (5, 6, 7).

Recently, there has been a debate on the need to follow these recommendations in all patients. Various authors have argued that, in certain circumstances, VB2 PPHF could be successfully treated using the ORIF technique (3, 8, 9, 10). For this reason, in some studies, ORIF has been compared to revision arthroplasty (RA) for this type of fracture, and equivalent if not better results have been obtained (8, 11, 12, 13, 14, 15, 16, 17).

In a recent metanalysis, Lewis *et al.* (10) state that RA has a similar revision rate to ORIF in VB2 PPHF. Fewer dislocations were seen in the ORIF group; however, there was no difference between other complications. They conclude that their results challenge the customary practice that all arthroplasty in VB2 must be revised and open the door for more nuanced decision-making. While RA is likely to remain the mainstay of treatment, ORIF should be considered in patients where RA is not ideal. Furthermore, the results show that if ORIF is performed, the outcomes are not disastrous as convention would have us believe and may offer a benefit over RA, although further research will help identify patients who may benefit from ORIF over RA (10).

The main objectives of this work are to provide an updated narrative review on this topic and attempt to design a decision-making algorithm for VB2 PPHF.

Multidisciplinary approach

It has been shown in the literature that the collaboration of the orthogeriatric department is very important for improving the management of older patients with hip fractures (18, 19, 20). Through our work and algorithm, we wish to highlight how important a multidisciplinary approach is between orthopaedic surgeons, orthogeriatricians, and anaesthesiologists. This approach has, on many occasions, enabled us to comprehensively assess patients and evaluate the pros and cons of the procedure to be performed.

Management algorithms

Even though several classifications and algorithms exist to guide PPHF treatment, the surgeon needs to understand that the treatment of PPHF needs to be individualized taking into account different parameters (patient comorbidities, implant stability, patient function levels, and availability of relevant resources and expertise) (7). Decision-making

requires experience and time; regularly multidisciplinary input should also be employed. The need to establish specific clinical pathways for fragility fractures, similar to those for other common fracture types, has recently become apparent (21).

Given the increasing need for decision-making algorithms or clinical scores in clinical practice, we have analysed separately each factor described in the literature that has been considered or recommended for the therapeutic decision, ORIF (Fig. 1) or RA (Fig. 2) in VB2 PPHF. Far from proposing a closed decision algorithm, all the factors that the authors consider in their daily clinical practice to decide between both techniques are presented. Finally, this paper proposes for the first time a treatment algorithm for deciding between ORIF or RA in VB2 PPHF.

Comorbidities/anaesthetic risk

The presence of multiple comorbidities and high anaesthetic risk are common points in all available literature when proposing ORIF vs RA (3, 4, 15, 22, 23, 24, 25, 26, 27).

Pavone *et al.* (22) discuss that patients who have a PPHF with surgical criteria, whatever the Vancouver classification, but who have significant comorbidities (American Society of Anesthesiologists score (ASA) ≥ 3) and a low functional demand before the fracture are assigned ORIF treatment instead of being given a RA. According to this criterion, of eight VB2 PPHF patients, two were treated via ORIF, as they both had a poor medical condition and low functional demand before the fracture (22). Pavlou *et al.* (24) suggest that elderly patients deemed unsuitable for prolonged procedures may selectively be considered for palliative fixation of a VB2/B3 PPHF.

A recent international consensus favours RA in VB2/B3 PPHF (28), but there are reported exceptions – the frail, elderly, low-demand individual, with osteopenia, who is unfit for prolonged surgery (25, 26). Spina *et al.* (4) state that the choice of surgical treatment (ORIF vs RA)

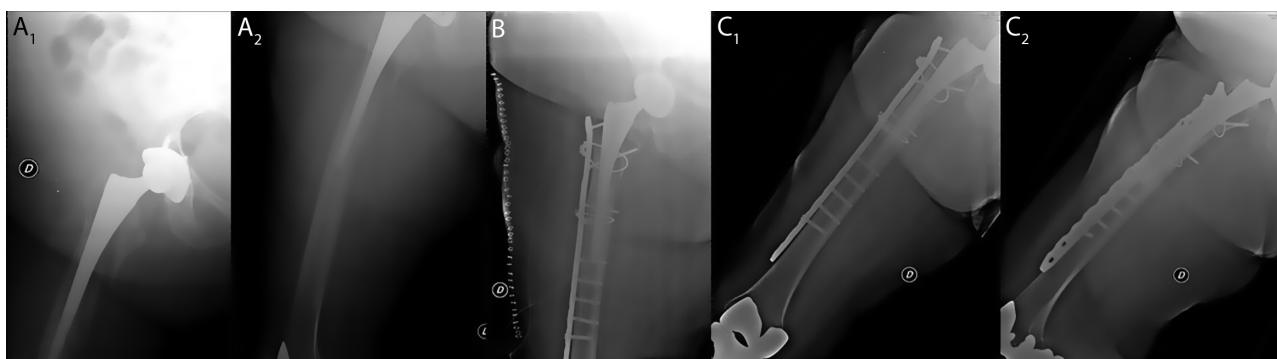


Figure 1
 VB2 PPHF treated via ORIF. (A) VB2 PPHF; (B) postoperative control X-ray; (C) 1 year follow-up X-ray.

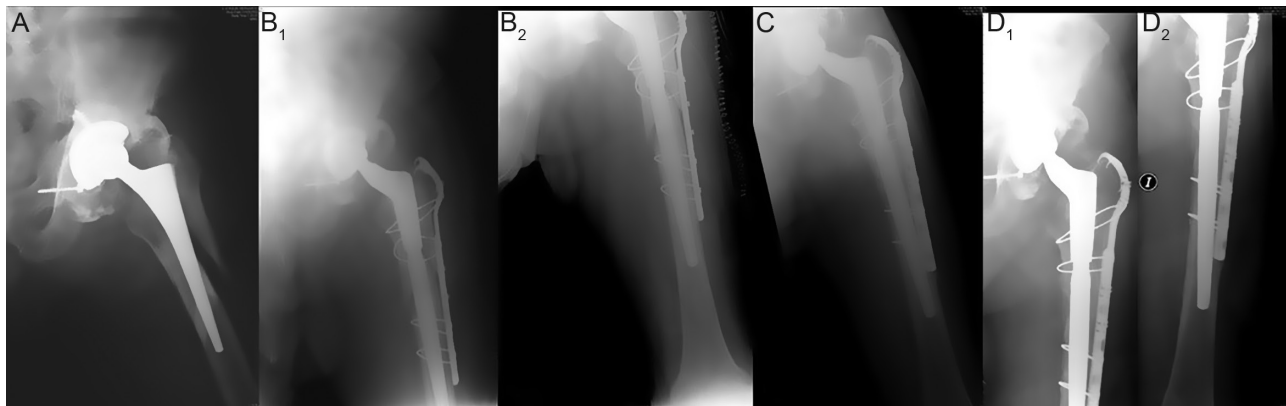


Figure 2 VB2 PPHF treated via RA. (A) VB2 PPHF; (B) postoperative control X-ray; (C) 1 year follow-up X-ray; (D) 2 years follow-up X-ray.

was affected by the clinical–anamnestic characteristics of the patient (ability in pre-fracture deambulation and comorbidity).

The authors of this narrative review also approach the patient in a comprehensive manner (3, 29) and consider that functional and medical assessment of the patient are the most important factors, and in many cases, this may be more relevant than the fracture pattern or whether the implant is loose or not. To make a better decision for the patient, the Charlson Comorbidity Index (CCI) was used (30), taking $CCI \geq 5$ as the cut-off point, which is the one established by its authors as the one associated with the highest mortality (3, 30). There were a higher proportion of patients with $ASA \geq 3$ and $CCI \geq 5$ in the ORIF group compared to the RA group, a statistically significant difference (3).

Functional status/previous mobility

As previously mentioned, the patient's previous functional status and previous mobility are other factors that most authors take into account when deciding between ORIF and RA in VB2 PPHF. Some refer to it as low functional demand (3, 22, 31), others poor general medical condition (32, 33), while others refer to the ability in pre-fracture deambulation (4).

Slullitel *et al.* (27) chose low functional demand as one of their criteria to indicate ORIF for VB2 PPHF, defined as a Parker mobility score <5 (34) or a Lawton scale for instrumental activities of daily living ≤ 6 (35).

Age

Age is a factor that in many cases may not determine the functionality and medical situation of the patient. In daily clinical practice, young patients with multiple pathologies, and sometimes elderly patients who maintain regular exercise routines can be found. Mainly the indication for ORIF in VB2 PPHF is for the elderly people but setting an

age limit may not be correct due to the large variability between patients. Revision hip surgery in octogenarians has demonstrated a very high complication rate (36, 37). Some authors set the cut-off at 65 years (27, 38). However, most publications recommend ORIF in elderly patients with low functional demand (15, 16, 23, 29), without setting a cut-off point.

Fracture pattern

Baum *et al.* (14) state that the Vancouver classification did not distinguish between fracture patterns and, although they do not analyse these, they did remark that this element could be important as fractures with a single fragment could be anatomically reduced and fixed using ORIF (14). Similarly, Moazen *et al.* (5) report that in patients with multiple fragments, or comminuted fractures, where osteosynthesis becomes very complicated, if the patient can withstand more aggressive surgery, such as RA, this would be a more suitable option, as it is sufficient to bring the fragments closer together without the need for anatomical reduction (5). Spina *et al.* (16) argue that the nature of the fracture is important to choose the surgical treatment.

Flury *et al.* (39) show that ORIF might be a valuable alternative to RA in VB2 PPHF, irrespective of the stem's design. Park *et al.* (33) in their work on PPHF conclude that their customized treatment, which considers the stability of the femoral stem and the configuration of the fracture, showed favourable overall results, despite differing substantially from the Vancouver classification system. Several VB2 PPHFs patterns have been described: burst (40), clamshell (41), reverse clamshell (42), and spiral (43). We have previously proposed a subclassification of VB2 PPHF according to the fracture pattern (44). Using the Gruen system (45), the proximal femur was divided into three zones (Fig. 3). The lateral zone (Gruen $1 \pm 2 \pm 3$), medial zone (Gruen $5 \pm 6 \pm 7$), and distal zone (Gruen $4 \pm 3 \pm 5$) were analysed and it was determined whether

each of the three zones was fractured. We concluded that V-B2 PPHF treated via ORIF affecting only one zone (medial, lateral, or distal) have a lower risk of complication than those affecting two or more zones. We propose a subclassification of Vancouver B2 type fractures: B2.1 (1 fractured zone) (Fig. 3 - panels A1, B1, C1) and B2.2 (≥ 2 fractured zones) (Fig. 3 - panels A2, B2, C2)

Spina *et al.* (4) state that in the presence of a straight uncemented stem and a fracture around the stem that modifies the relationship between the prosthetic stem and the metaphyseal femoral bone, but does not exceed the apex, the fixation of the stem into the diaphyseal canal may not be completely lost. This is because the straight stem has a higher fixation in the diaphyseal part of the femur (46).

The difference in fracture patterns between cemented and uncemented stems has recently been described. Fenelon *et al.* (47) conclude that fracture patterns differ according to femoral stem fixation. A simple ‘sickle-like’ oblique fracture pattern was more commonly seen in uncemented stems while cemented tapered stems resulted in a comminuted ‘axe splitting’ pattern. However, it does not establish the comparison of results between ORIF and RA.

On the other hand, Spina *et al.* (4) suggest that the recommended treatment should still be RA with a longer stem, but also that ORIF with a plate can be a viable

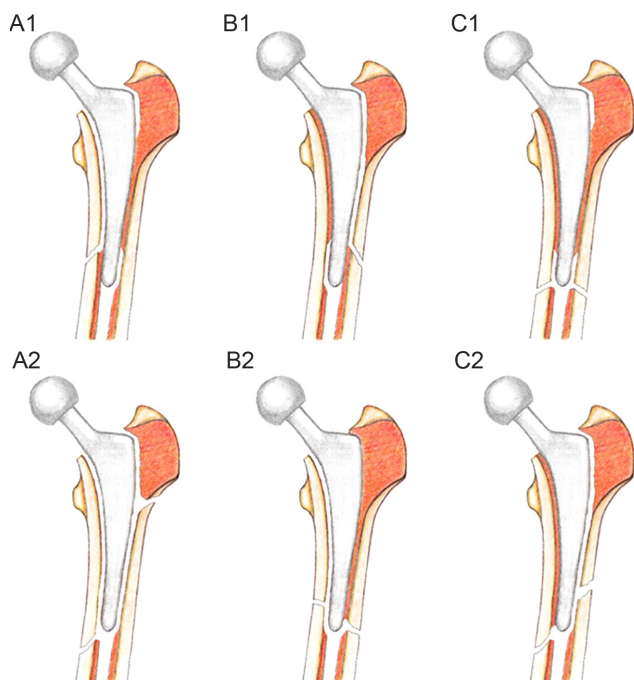


Figure 3 Fracture patterns according to the 3 radiographic zones (medial, lateral and distal). (A1) Medial zone fracture; (B1) Lateral zone fracture; (C1) Distal zone fracture; (A2) 3-zone fracture; (B2) Medial and distal fracture; (C2) Lateral and distal fracture. Reprinted from (44) with permission from Elsevier.

alternative when the fracture does not exceed the apex of the uncemented straight stem and when the fracture causes the detachment of the stem from the cement–bone (c-b) complex.

Lastly, in patients with multiple bone fragments or comminuted fractures, where ORIF becomes very complicated, if the patient can withstand more aggressive surgery, such as RA, this would be a more suitable option, as it is sufficient to bring the fragments closer together without the need for anatomical reduction (5, 27, 44).

Anatomical reduction

Joestl *et al.* (15) suggest that it is essential to emphasize that anatomical reduction of the femoral shaft should be achieved to ensure stem stability to the bone and consequently avoid secondary migration of the prosthesis.

Several authors agree that ORIF is a valid treatment option for VB2 PPHF. However, they also agree that an anatomical reduction is mandatory (4, 27, 44).

Type of stem

Although it would be very interesting to know which type of stem is associated with better outcomes with osteosynthesis, there is poor available evidence.

Flury *et al.* (39) did not take into account the type of stem. De Boer *et al.* (46), in a paper examining stem grasp in THA, demonstrated that compared to straight stem design, an anatomically designed stem has a significantly higher metaphyseal femoral canal fill (46). González-Martín *et al.* (3), described that all implant complications in the ORIF group (39 patients) occurred in straight uncemented stems, and they found no implant complications in anatomic or cemented stems; however, the difference was not statistically significant.

Prior loosening

Ninan *et al.* (48), in their work on PPHF, introduced the concept of ‘happy hips’ and ‘unhappy hips’, referring to patients who had not presented documented preoperative loosening problems in the ipsilateral hip and those who had, respectively. They concluded that patients with ‘happy hips’ before the fracture can be treated by ORIF alone unless the fracture itself compromises the fixation of the arthroplasty (48). This is an important factor that should be considered when making the definitive surgical decision, and whether or not the patient presented pain and clinical loosening before the fracture may be considered a factor against ORIF, as it may biologically hinder the potential viability and consolidation of VB2 PPHF.

Surgeon experience

PPHF is becoming increasingly common due to the ageing population and the increasing number of hip replacements

(29). As these fractures become more common, they are increasingly treated by trauma surgeons and not arthroplasty surgeons. It could explain the reason why they seem to be increasingly fixed instead of revised, but there must be a very broad geographic distribution across the world. There is no clear evidence on this issue. Most authors state that the surgeon's experience with the technique to be performed (ORIF/RA) is important (3, 15, 16, 32). Baum *et al.* (14) state that if an arthroplasty surgeon was on call, RA was performed by a dedicated senior consultant arthroplasty surgeon. If a trauma surgeon was on call, ORIF with LCP was performed by a dedicated trauma surgeon immediately or in the later course.

In some centers, these fractures could be treated by trauma surgeons which are very capable of reductions restoring stability. However, they are also capable of revision when needed. However, in other centers, there may be sub-specialization and ORIF may be performed by trauma surgeons and RA by arthroplasty surgeons.

In our daily clinical practice, if in the preoperative X-ray, the stem is separated from all the fragments (totally loose), then RA is performed by arthroplasty surgeons. If the radiograph shows that some of the fracture fragments (medial or lateral) that seem fixed to the stem, then ORIF is planned by arthroplasty surgeons, which are very capable of reductions restoring stability. In this case, with the patient in lateral decubitus, if it is necessary to change the decision to RA, the femur is approached laterally, without approaching the joint, reaching the fracture site, and exposing it by anterior retraction of the vastus lateralis muscle. Under direct vision of the path of the fracture site, the stem can be visualized. At this point, the assistant is asked to make rotational movements of the leg and with this manoeuvre, the surgeon verifies if the implant is attached to at least one of the fragments (they move together). If so, the osteosynthesis with plate is chosen. If in the rotation movements the implant moves independently of all the fragments during the rotation movements, we understand that the whole stem is loose and we proceed to the RA in the same surgical act.

If in the preoperative multidisciplinary assessment the patient is not a candidate for RA, it is scheduled in the trauma or orthopedic operating theatre, the stability of the arthroplasty is not tested in the operating theatre as this will not change the therapeutic decision. An attempt is made to fix the fracture as well as possible and not to expose the patient to a greater risk of bleeding, surgical time, etc. (10)

Type of osteosynthesis

There is no consensus on the best type of osteosynthesis. However, Patsiogiannis *et al.* in a recent review on PPHF state that the use of bridging locking plates is nowadays

the most popularized technique of fixation (7). They act as extramedullary bridging splints creating a fixed-angle construct ideal for fixation of osteopenic/porotic bone (7). Bridge plating, in principle, creates a mechanical environment of relative stability, which leads to early callus formation. Modern periprosthetic femoral plates also offer anatomical designs (pre-contoured plates), which match the anatomy of the femur; variable interlocking options facilitating screw fixation around the stem; extensions capturing the greater trochanteric region; multidirectional screw placement to avoid obstacles and/or aim to available bone stock, as well as the incorporation of wires/cables through the plate (inlay cerclages) (7).

Most of these plating systems can also be applied using minimally invasive techniques (such as minimally invasive plate osteosynthesis (MIPO)) and indirect reduction, minimizing the soft tissue damage and preserving the blood supply around the fracture area (7). The 'plate working length' (length of the middle part of the plate which is unprotected by screws or inlay cables and is overlying the fracture area) influences the cyclic fatigue performance and the strain of the plate and affects the overall stiffness of the construct (7). The recommended effective working length of a plate should measure two to three times the width of the femur at the level of the fracture, and not less than the fracture extent, protecting the plate from stress concentration and early fatigue failure and to promote callus formation (7).

The use of the longest possible plate decreases the pull-out forces on the screws, improves the active lever arm of each screw, and protects from secondary stress risers and fractures of the femur (7). Bicortical fixation is biomechanically more stable, but if not possible, a combination of cerclage wires/cables with unicortical locking screws should be used (49). The rationale of using long plates to span the whole femur to protect from further future injuries is also advocated (50).

In VB2 PPHFs, the arthroplasty stability is compromised, and there is adequate bone stock. In general, long-stem revision arthroplasty alone or supplemented by plate and/or allograft strut fixation represents the consensus (5, 6, 7). However, although the use of strut allograft has been recommended, very few authors use it in their daily clinical practice in patients with VB2 PPHF (3, 27, 50), showing nevertheless good clinical results (3, 27, 50).

Cemented stems

Quah *et al.* proposed a treatment algorithm for cemented arthroplasties, stating that a good bone stock, the possibility of achieving an anatomical reduction, and the integrity of the cement mantle, rather than the stability of the arthroplasty alone, are the most important determinants for making the final decision (51).

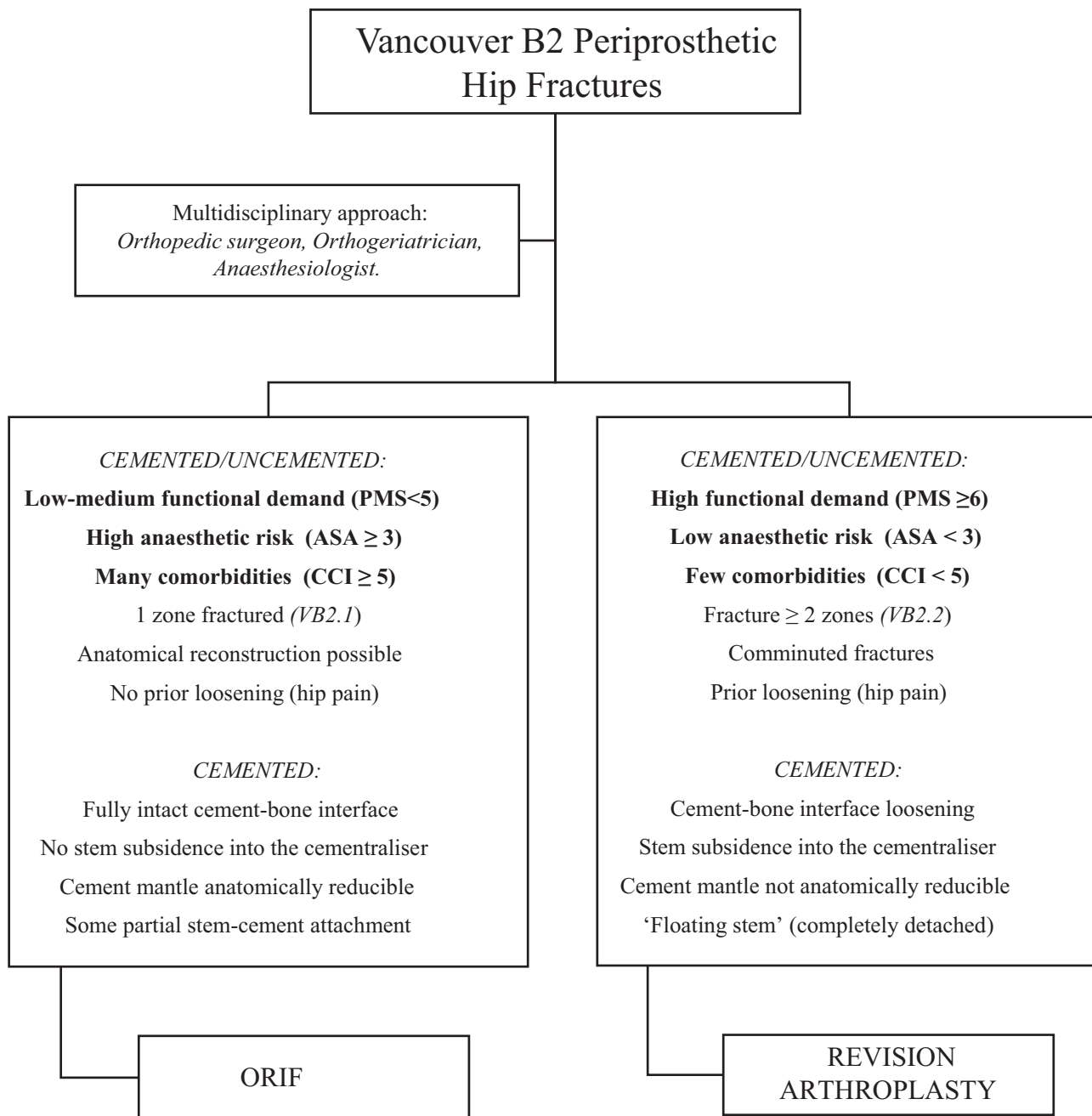


Figure 4

VB2 PPHF treatment algorithm (relative indications in favour of ORIF or RA). Bold type indicates most important factors; PMS, Parker mobility score; ASA, American Society of Anesthesiologists score; CCI, Charlson Comorbidity Index

Solomon *et al.* (12) and Spina *et al.* (4) discuss that cemented VB2 PPHF could theoretically regain stability in their original cement mantle, provided that the c-b interface is maintained, with the fracture disrupting only the stem-cement (s-c) interface, and stable anatomical reduction is achieved at the time of surgery. These authors postulated that VB2 PPHF around cemented collarless polished tapered

(CCPT) stems, which are loose at the s-c interface only and can be anatomically reduced, can be successfully managed by ORIF alone, without revision of the stem.

Powell-Bowns *et al.* (52), in the same way, in their article on Vancouver B PPHF involving the Exeter cemented stem, state that by definition, all CCPT stems are loose at the implant–cement interface with no bond between the

highly polished stem and the cement. If the c-b interface is well fixed, and the fracture and cement mantle are anatomically reducible, fractures are potentially amenable to fixation as opposed to stem revision. The indications for RA vs ORIF were symptomatic/progressive c-b interface loosening, unreconstructible secondary to comminution, stem subsided into centraliser (likely irreducible), and irreducible intraoperatively. Likewise, in another study on cemented PPHF (43), the fracture was considered suitable for fixation in the absence of symptomatic c-b interface loosening, unreconstructible comminution, or stem subsidence into the cementaliser.

Finally, Slullitel *et al.* (27), similar to the principles defined by Richards *et al.* (31), define their criteria to indicate ORIF in cemented VB2 PPHF consisted of the following: well-cemented (Barrack A or B) (53) polished femoral prosthesis, a fully intact cement-bone interface without signs of previous loosening and, evidence of some partial stem-cement attachment, with no evidence of ‘floating stem’ (i.e. not completely detached from the mantle).

The proposed algorithm (Fig. 4) is intended to summarise the available evidence (Table 1), which must be weighed up to make the best therapeutic decision. We propose several factors to help orthopaedic surgeons decide on the best treatment. However, given the vast heterogeneity of patients, we do not believe that it is possible to establish a closed algorithm, as there are no studies with a high level of evidence.

There is consensus that the most relevant factors when recommending ORIF or RA are the first three proposed: functional demand, anaesthetic risk, and comorbidities (3, 4, 22, 23, 24, 25, 26, 27, 31, 32, 33). ORIF should be recommended in cases where there is low-medium functional demand, high anaesthetic risk, and many comorbidities.

If the patient is a candidate for revision arthroplasty, the rest of the factors should be assessed. It is true that there are types of fractures that cannot be synthesised, mainly due to comminution. In these cases, the risks of revision arthroplasty surgery must be explained to the patient and his or her family, and a joint decision must be made.

Table 1 Evidence-based algorithm (Oxford Centre for Evidence-Based Medicine (54)).

	Level of evidence	
	Evidence	References
Functional status/previous mobility	3b	3, 4, 22, 27, 31, 32, 33
Comorbidities/anaesthetic risk	3b	3, 4, 15, 22, 23, 24, 25, 26, 27
Fracture pattern	3b	4, 44
Anatomical reduction	4	14, 15, 16
Prior loosening	4	4, 15, 27, 44
Surgeon experience	3b	48
Cemented stems	3b	3, 14, 15, 16, 32
		4, 12, 27, 43, 49, 50

3b, case-control studies; 4, case-series.

In this regard, the surgeon’s experience is very important (15, 16), since they must be the one who, after assessing all the factors (previous functionality, comorbidities, anaesthetic risk, fracture pattern, implant stability, and bone stock), determines, preferably with the help of their team, the best decision for the patient.

Conclusions

We propose a comprehensive treatment algorithm in VB2 PPHF to help in the decision-making process. The proposed algorithm is a valid addition to clinical practice because it summarizes the available scientific evidence. It helps to decide whether open reduction and internal fixation or revision arthroplasty should be performed in these patients. There is currently no available evidence to make a closed treatment algorithm, so all factors included must be weighed up to make the best therapeutic decision.

ICMJE Conflict of Interest Statement

Each author certifies that he has no commercial associations (e.g. consultancies, stock ownership, equity interest, patent/licensing arrangements, etc.) that might pose a conflict of interest in connection with the submitted article.

Funding Statement

This work did not receive any specific grant from any funding agency in the public, commercial, or not-for-profit sector.

Ethical Review Committee Statement

We have the favorable certificate from the ethics committee of our local ethics committee with the code: CHUC_2020_31.

Acknowledgements

The authors thank Daniel Martin, for the English correction of this manuscript.

References

- Lindahl H, Oden A, Garellick G & Malchau H. The excess mortality due to periprosthetic femur fracture. A study from the Swedish National Hip Arthroplasty Register. *Bone* 2007 **40** 1294–1298. (<https://doi.org/10.1016/j.bone.2007.01.003>)
- Duncan CP & Masri BA. Fractures of the femur after hip replacement. *Instructional Course Lectures* 1995 **44** 293–304.
- González-Martín D, Pais-Brito JL, González-Casamayor S, Guerra-Ferraz A, Martín-Vélez P & Herrera-Pérez M. Periprosthetic hip fractures with a loose stem: open reduction and internal fixation versus stem revision. *Journal of Arthroplasty* 2021 **36** 3318–3325. (<https://doi.org/10.1016/j.arth.2021.05.003>)
- Spina M & Scalvi A. Vancouver B2 periprosthetic femoral fractures: a comparative study of stem revision versus internal fixation with plate. *European Journal of Orthopaedic Surgery and Traumatology* 2018 **28** 1133–1142. (<https://doi.org/10.1007/s00590-018-2181-3>)

- 5. Moazen M, Mak JH, Etchels LW, Jin Z, Wilcox RK, Jones AC & Tsiridis E.** Periprosthetic femoral fracture – a biomechanical comparison between Vancouver type B1 and B2 fixation methods. *Journal of Arthroplasty* 2014 **29** 495–500. (<https://doi.org/10.1016/j.arth.2013.08.010>)
- 6. Haasper C, Enayatollahi MA & Gehrke T.** Treatment of Vancouver type B2 periprosthetic femoral fractures. *International Orthopaedics* 2015 **39** 1989–1993. (<https://doi.org/10.1007/s00264-015-2959-4>)
- 7. Patsiogiannis N, Kanakaris NK & Giannoudis PV.** Periprosthetic hip fractures: an update into their management and clinical outcomes. *EFORT Open Reviews* 2021 **6** 75–92. (<https://doi.org/10.1302/2058-5241.6.200050>)
- 8. Stoffel K, Blauth M, Joeris A, Blumenthal A & Rometsch E.** Fracture fixation versus revision arthroplasty in Vancouver type B2 and B3 periprosthetic femoral fractures: a systematic review. *Archives of Orthopaedic and Trauma Surgery* 2020 **140** 1381–1394. (<https://doi.org/10.1007/s00402-020-03332-7>)
- 9. Haider T, Hanna P, Mohamadi A, Merchan N, McNichol M, Wixted JJ, Appleton PT, Nazarian A, von Keudell AG & Rodriguez EK.** Revision arthroplasty versus open reduction and internal fixation of Vancouver type-B2 and B3 periprosthetic femoral fractures. *JBJS Reviews* 2021 **9** e21.00008. (<https://doi.org/10.2106/JBJS.RVW.21.00008>)
- 10. Lewis DP, Tarrant SM, Cornford L & Balogh ZJ.** The management of Vancouver B2 periprosthetic femoral fractures, revision total hip arthroplasty vs open reduction and internal fixation: a systematic review and meta-analysis. *Journal of Orthopaedic Trauma* 2022 **36** 7–16. (<https://doi.org/10.1097/BOT.0000000000002148>)
- 11. Lunebourg A, Mouhsine E, Cherix S, Ollivier M, Chevalley F & Wettstein M.** Treatment of type B periprosthetic femur fractures with curved non-locking plate with eccentric holes: retrospective study of 43 patients with minimum 1-year follow-up. *Orthopaedics and Traumatology, Surgery and Research* 2015 **101** 277–282. (<https://doi.org/10.1016/j.otsr.2015.01.015>)
- 12. Solomon LB, Hussencocus SM, Carbone TA, Callary SA & Howie DW.** Is internal fixation alone advantageous in selected B2 periprosthetic fractures? *ANZ Journal of Surgery* 2015 **85** 169–173. (<https://doi.org/10.1111/ans.12884>)
- 13. Lindahl H, Garellick G, Regnér H, Herberts P & Malchau H.** Three hundred and twenty-one periprosthetic femoral fractures. *Journal of Bone and Joint Surgery: American Volume* 2006 **88** 1215–1222. (<https://doi.org/10.2106/JBJS.E.00457>)
- 14. Baum C, Leimbacher M, Kriechling P, Platz A & Cadosch D.** Treatment of periprosthetic femoral fractures Vancouver type B2: revision arthroplasty versus open reduction and internal fixation with locking compression plate. *Geriatric Orthopaedic Surgery and Rehabilitation* 2019 **10** 2151459319876859. (<https://doi.org/10.1177/2151459319876859>)
- 15. Joestl J, Hofbauer M, Lang N, Tiefenboeck T & Hajdu S.** Locking compression plate versus revision-prosthesis for Vancouver type B2 periprosthetic femoral fractures after total hip arthroplasty. *Injury* 2016 **47** 939–943. (<https://doi.org/10.1016/j.injury.2016.01.036>)
- 16. Spina M, Rocca G, Canella A & Scalvi A.** Causes of failure in periprosthetic fractures of the hip at 1- to 14-year follow-up. *Injury* 2014 **45** (Supplement 6) S85–S92. (<https://doi.org/10.1016/j.injury.2014.10.029>)
- 17. Zuurmond RG, van Wijhe W, van Raay JJ & Bulstra SK.** High incidence of complications and poor clinical outcome in the operative treatment of periprosthetic femoral fractures: an analysis of 71 cases. *Injury* 2010 **41** 629–633. (<https://doi.org/10.1016/j.injury.2010.01.102>)
- 18. Baroni M, Serra R, Boccardi V, Ercolani S, Zengarini E, Casucci P, Valecchi R, Rinonapoli G, Caraffa A, Mecocci P, et al.** The orthogeriatric comanagement improves clinical outcomes of hip fracture in older adults. *Osteoporosis International* 2019 **30** 907–916. (<https://doi.org/10.1007/s00198-019-04858-2>)
- 19. Folbert EC, Hegeman JH, Vermeer M, Regtuijt EM, van der Velde D, Ten Duis HJ & Slaets JP.** Improved 1-year mortality in elderly patients with a hip fracture following integrated orthogeriatric treatment. *Osteoporosis International* 2017 **28** 269–277. (<https://doi.org/10.1007/s00198-016-3711-7>)
- 20. Gosch M, Hoffmann-Weltin Y, Roth T, Blauth M, Nicholas JA & Kammerlander C.** Orthogeriatric co-management improves the outcome of long-term care residents with fragility fractures. *Archives of Orthopaedic and Trauma Surgery* 2016 **136** 1403–1409. (<https://doi.org/10.1007/s00402-016-2543-4>)
- 21. Haddad FS.** Periprosthetic fractures: more challenges ahead. *Bone and Joint Journal* 2020 **102-B** 547–549. (<https://doi.org/10.1302/0301-620X.102B5.BJJ-2020-0427>)
- 22. Pavone V, de Cristo C, Di Stefano A, Costarella L, Testa G & Sessa G.** Periprosthetic femoral fractures after total hip arthroplasty: an algorithm of treatment. *Injury* 2019 **50** (Supplement 2) S45–S51. (<https://doi.org/10.1016/j.injury.2019.01.044>)
- 23. Martinov S, D’ulisse S, Haumont E, Schioppa D, Reynders P & Illés T.** Comparative study of Vancouver type B2 periprosthetic fractures treated by internal fixation versus stem revision. *Archives of Orthopaedic and Trauma Surgery* 2021 In press. (<https://doi.org/10.1007/s00402-021-03953-6>)
- 24. Pavlou G, Panteliadis P, Macdonald D, Timperley JA, Gie G, Bancroft G & Tsiridis E.** A review of 202 periprosthetic fractures—stem revision and allograft improves outcome for type B fractures. *Hip International* 2011 **21** 21–29. (<https://doi.org/10.5301/hip.2011.6301>)
- 25. Finlayson G, Tucker A, Black ND, McDonald S, Molloy M & Wilson D.** Outcomes and predictors of mortality following periprosthetic proximal femoral fractures. *Injury* 2019 **50** 438–443. (<https://doi.org/10.1016/j.injury.2018.10.032>)
- 26. Parvizi J & Vegari DN.** Periprosthetic proximal femur fractures: current concepts. *Journal of Orthopaedic Trauma* 2011 **25** (Supplement 2) S77–S81. (<https://doi.org/10.1097/BOT.0b013e31821b8c3b>)
- 27. Slullitel PA, Garcia-Barreiro GG, Oñativia JI, Zanotti G, Comba F, Piccaluga F & Buttaro MA.** Selected Vancouver B2 periprosthetic femoral fractures around cemented polished femoral components can be safely treated with osteosynthesis. *Bone and Joint Journal* 2021 **103-B** 1222–1230. (<https://doi.org/10.1302/0301-620X.103B7.BJJ-2020-1809.R1>)
- 28. Bates BD, Walmsley DW, Vicente MR, Kuzyk PR, Nauth A, Waddell JP, McKee MD & Schemitsch EH.** An international, cross-sectional survey of the management of Vancouver type B1 periprosthetic femoral fractures around total hip arthroplasties. *Injury* 2018 **49** 364–369. (<https://doi.org/10.1016/j.injury.2017.10.034>)
- 29. González-Martín D, González-Casamayor S, Herrera-Pérez M, Guerra-Ferraz A, Ojeda-Jiménez J & Pais-Brito JL.** Is stem revision necessary for Vancouver B2 periprosthetic hip fractures? Analysis of osteosynthesis results from 39 cases. *Journal of Clinical Medicine* 2021 **10** 5288. (<https://doi.org/10.3390/jcm10225288>)
- 30. Charlson ME, Pompei P, Ales KL & MacKenzie CR.** A new method of classifying prognostic comorbidity in longitudinal studies: development and validation. *Journal of Chronic Diseases* 1987 **40** 373–383. ([https://doi.org/10.1016/0021-9681\(87\)90171-8](https://doi.org/10.1016/0021-9681(87)90171-8))
- 31. Richards CJ, Duncan CP & Crawford RW.** Cement-in-cement femoral revision for the treatment of highly selected Vancouver B2 periprosthetic fractures. *Journal of Arthroplasty* 2011 **26** 335–337. (<https://doi.org/10.1016/j.arth.2010.03.014>)

- 32. Niikura T, Lee SY, Sakai Y, Nishida K, Kuroda R & Kurosaka M.** Treatment results of a periprosthetic femoral fracture case series: treatment method for Vancouver type b2 fractures can be customized. *Clinics in Orthopedic Surgery* 2014 **6** 138–145. (<https://doi.org/10.4055/cios.2014.6.2.138>)
- 33. Park SK, Kim YG & Kim SY.** Treatment of periprosthetic femoral fractures in hip arthroplasty. *Clinics in Orthopedic Surgery* 2011 **3** 101–106. (<https://doi.org/10.4055/cios.2011.3.2.101>)
- 34. Parker MJ & Palmer CR.** A new mobility score for predicting mortality after hip fracture. *Journal of Bone and Joint Surgery: British Volume* 1993 **75** 797–798. (<https://doi.org/10.1302/0301-620X.75B5.8376443>)
- 35. Lawton MP & Brody EM.** Assessment of older people: self-maintaining and instrumental activities of daily living. *Gerontologist* 1969 **9** 179–186. (https://doi.org/10.1093/geront/9.3_Part_1.179)
- 36. Koenig K, Huddleston JI 3rd, Huddleston H, Maloney WJ & Goodman SB.** Advanced age and comorbidity increase the risk for adverse events after revision total hip arthroplasty. *Journal of Arthroplasty* 2012 **27** 1402.e1–1407.e1. (<https://doi.org/10.1016/j.arth.2011.11.013>)
- 37. Mahomed NN, Barrett JA, Katz JN, Phillips CB, Losina E, Lew RA, Guadagnoli E, Harris WH, Poss R & Baron JA.** Rates and outcomes of primary and revision total hip replacement in the United States medicare population. *Journal of Bone and Joint Surgery: American Volume* 2003 **85** 27–32. (<https://doi.org/10.2106/00004623-200301000-00005>)
- 38. Moreta J, Uriarte I, Ormazá A, Mosquera J, Iza K, Aguirre U, Legarreta MJ & Martínez-De Los Mozos JL.** Outcomes of Vancouver B2 and B3 periprosthetic femoral fractures after total hip arthroplasty in elderly patients. *Hip International* 2019 **29** 184–190. (<https://doi.org/10.1177/1120700018772163>)
- 39. Flury A, Hasler J, Pagenstert G, Dimitriou D, Helmy N & Finsterwald M.** Open reduction and internal fixation might be a valuable alternative to stem revision in Vancouver B2 periprosthetic femoral fractures, irrespective of the stem's design. *Archives of Orthopaedic and Trauma Surgery* 2021 **141** 871–878. (<https://doi.org/10.1007/s00402-020-03568-3>)
- 40. Phillips J, Boulton C, Moran C & Manktelow A.** Periprosthetic fractures around Exeter stems: a new injury? *Bone and Joint Journal* 2012 **94-B** (Supplement XXV) 187.
- 41. Capello WN, D'Antonio JA & Naughton M.** Periprosthetic fractures around a cementless hydroxyapatite-coated implant: a new fracture pattern is described. *Clinical Orthopaedics and Related Research* 2014 **472** 604–610. (<https://doi.org/10.1007/s11999-013-3137-x>)
- 42. Karam J, Campbell P, Desai S & Hunter M.** Periprosthetic proximal femoral fractures in cemented and uncemented stems according to Vancouver classification: observation of a new fracture pattern. *Journal of Orthopaedic Surgery and Research* 2020 **15** 100. (<https://doi.org/10.1186/s13018-020-01619-4>)
- 43. Grammatopoulos G, Pandit H, Kambouroglou G, Deakin M, Gundle R, McLardy-Smith P, Taylor A & Murray D.** A unique peri-prosthetic fracture pattern in well fixed femoral stems with polished, tapered, collarless design of total hip replacement. *Injury* 2011 **42** 1271–1276. (<https://doi.org/10.1016/j.injury.2011.01.008>)
- 44. González-Martín D, Pais-Brito JL, González-Casamayor S, Guerra-Ferraz A, Ojeda-Jiménez J & Herrera-Pérez M.** New sub-classification of Vancouver B2 periprosthetic hip fractures according to fracture pattern. *Injury* 2021 **53** 1218–1224. (<https://doi.org/10.1016/j.injury.2021.10.026>)
- 45. Gruen TA, McNeice GM & Amstutz HC.** 'Modes of failure' of cemented stem-type femoral components: a radiographic analysis of loosening. *Clinical Orthopaedics and Related Research* 1979 **141** 17–27. (<https://doi.org/10.1097/00003086-197906000-00002>)
- 46. de Boer FA & Sariali E.** Comparison of anatomic vs. straight femoral stem design in total hip replacement – femoral canal fill in vivo. *Hip International* 2017 **27** 241–244. (<https://doi.org/10.5301/hipint.5000439>)
- 47. Fenelon C, Murphy EP, Baig MN, Kearns SR, Murphy CG & Curtin W.** Breaking bad: a comparative descriptive analysis of periprosthetic fractures around cemented and uncemented femoral stems. *Journal of Arthroplasty* 2019 **34** 1783–1786. (<https://doi.org/10.1016/j.arth.2019.03.051>)
- 48. Ninan TM, Costa ML & Krikler SJ.** Classification of femoral periprosthetic fractures. *Injury* 2007 **38** 661–668. (<https://doi.org/10.1016/j.injury.2007.02.053>)
- 49. Graham SM, Mak JH, Moazen M, Leonidou A, Jones AC, Wilcox RK & Tsidis E.** Periprosthetic femoral fracture fixation: a biomechanical comparison between proximal locking screws and cables. *Journal of Orthopaedic Science* 2015 **20** 875–880. (<https://doi.org/10.1007/s00776-015-0735-3>)
- 50. Moloney GB, Westrick ER, Siska PA & Tarkin IS.** Treatment of periprosthetic femur fractures around a well-fixed hip arthroplasty implant: span the whole bone. *Archives of Orthopaedic and Trauma Surgery* 2014 **134** 9–14. (<https://doi.org/10.1007/s00402-013-1883-6>)
- 51. Quah C, Porteous M & Stephen A.** Principles of managing Vancouver type B periprosthetic fractures around cemented polished tapered femoral stems. *European Journal of Orthopaedic Surgery and Traumatology* 2017 **27** 477–482. (<https://doi.org/10.1007/s00590-016-1883-7>)
- 52. Powell-Bowns MFR, Oag E, Ng N, Pandit H, Moran M, Patton JT, Clement ND & Scott CEH.** Vancouver B periprosthetic fractures involving the Exeter cemented stem. *Bone and Joint Journal* 2021 **103-B** 309–320. (<https://doi.org/10.1302/0301-620X.103B2.BJJ-2020-0695.R1>)
- 53. Barrack RL, Mulroy RD Jr & Harris WH.** Improved cementing techniques and femoral component loosening in young patients with hip arthroplasty. A 12-year radiographic review. *Journal of Bone and Joint Surgery: British Volume* 1992 **74** 385–389. (<https://doi.org/10.1302/0301-620X.74B3.1587883>)
- 54. OCEBM Levels of Evidence Working Group.** *Levels of evidence* (March 2009). Oxford Centre for Evidence-Based Medicine, 2009. (available at: <http://www.cebm.net/index.aspx?o=1025>)