



Multiloop method for traction during colorectal endoscopic submucosal dissection

Gota Sudo, MD,^{1,2} Tokuma Tanuma, MD, PhD,¹ Yuichiro Suzuki, MD,¹ Hiroshi Nakase, MD, PhD²

Colorectal endoscopic submucosal dissection (ESD) is one of the most challenging procedures. Traction methods for colorectal ESD have been devised to simplify the procedure and reduce the risks of adverse events.¹⁻⁵ However, several problems remain, especially in terms of versatility and convenience. Therefore, we have devised a multiloop (M-loop) method, which is a traction method using silk thread and clips.

First, we tie 3-0 silk thread to a 2.5-mL syringe (both commonly available in clinical practice) and make a loop.

After repeating the same steps and cutting the remaining silk thread, we create the M-loop (Fig. 1A and B). The number of loops may be adjusted for each case. For example, we use 2 loops in the colon and 3 loops in the rectum.

After this, with the clip half-opened, the loop at the end is attached to the base of the clip (Fig. 2). Thereafter, the clip is housed in the delivery catheter, inserted into the working channel of the endoscope, and deployed into the colorectal tract in the same manner as a standard clip




Figure 1. A, 3-0 silk thread is tied to a 2.5-mL syringe to make a loop. B, After same step is repeated and remaining silk thread is cut, M-loop is created.




Figure 2. A loop located at the end is attached to the bottom of half-opened clip.

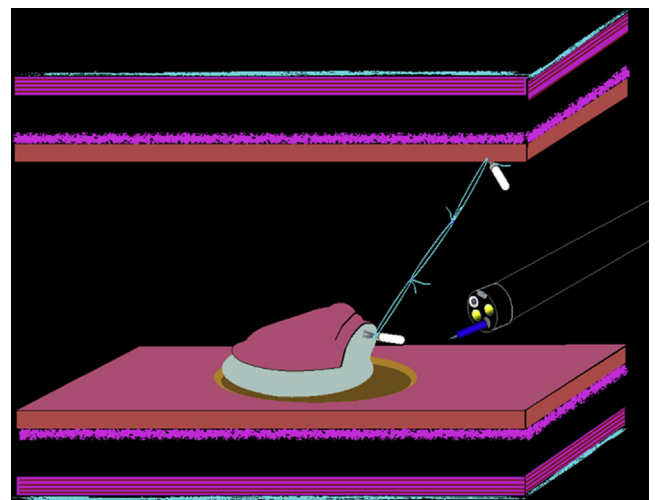


Figure 3. Schema of colorectal endoscopic submucosal dissection with use of M-loop method.

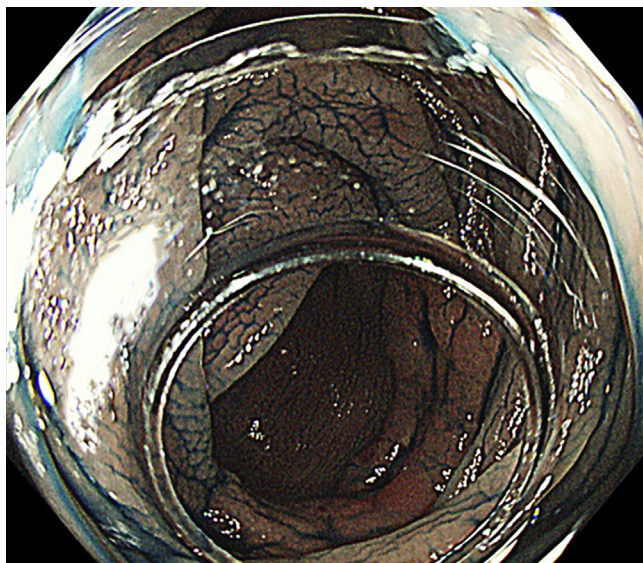


Figure 4. Laterally spreading tumor of nongranular type in the transverse colon.



Figure 6. Second M-loop is attached, as is the first M-loop.

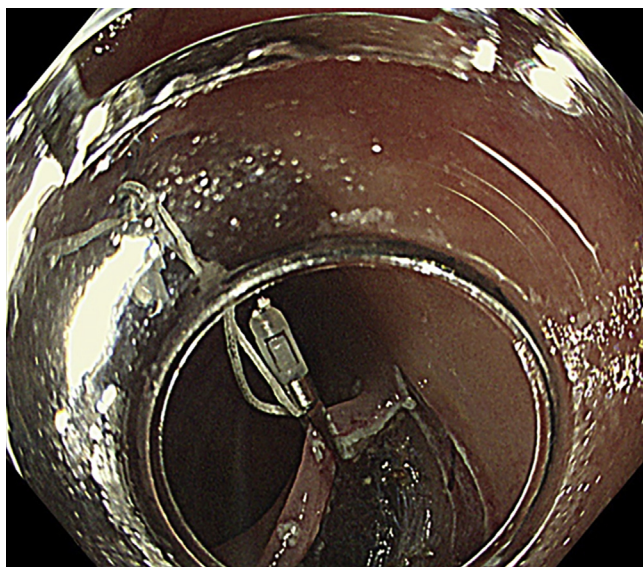


Figure 5. First M-loop is attached to the anal side of the cut edge of laterally spreading tumor.

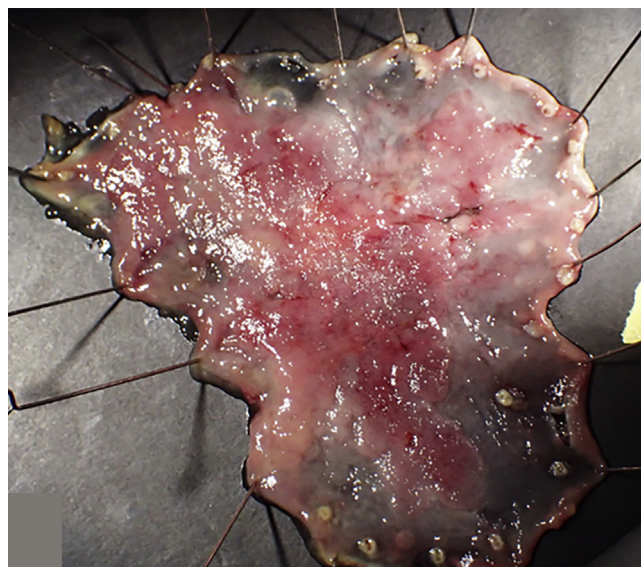


Figure 7. Resected specimen after endoscopic submucosal dissection by use of M-loop method.

operation. The clip is attached on the anal side of the specimen. The loop at the other end is attached by clip to the opposite side of the specimen. The scheme of the M-loop method is shown in [Figure 3](#).

A 74-year-old man was referred to our center for a 50-mm laterally spreading tumor of nongranular type in the transverse colon ([Fig. 4](#)) and underwent colorectal ESD by the use of a Hook Knife (KD-625QR; Olympus, Tokyo, Japan) and the M-loop method ([Video 1](#), available online at www.VideoGIE.org). After mucosal incision, the first M-loop was attached to the anal side of the cut edge of the lesion ([Fig. 5](#)). Next, we used a second M-loop to achieve better visualization ([Fig. 6](#)). We obtained a good

visual field during submucosal dissection and achieved en-bloc resection without any adverse events ([Fig. 7](#)). We cut the M-loop with the Hook Knife and collected the specimen. Histopathologic analysis showed tubular adenocarcinoma, slight submucosal invasion with lateral and vertical margin free.

With the M-loop method, we can secure a sufficient visual field during submucosal dissection. Compared with other traction methods, the M-loop method is simple and cost efficient. We can perform it at any institution, and it does not require any new device. With use of the M-loops, we can adjust both the length and the strength of traction by changing the number of loops. Also, we

can alter the direction of traction depending on circumstances by adding or cutting off the M-loop. It is hard to alter the direction of traction when the single-loop method is used because there would be no loop for clipping after we cut it off. By contrast, the M-loop method with 2 loops (or 3 loops) is easier because at least 1 loop for traction remains even after we cut it off.

When cutting the silk, the electrocautery settings are the same as during ESD. We can cut the silk thread with either incision or coagulation. Thus, the M-loop method can contribute to further popularization of colorectal ESD.

DISCLOSURE

All authors disclosed no financial relationships relevant to this publication.

ACKNOWLEDGMENTS

The authors thank Dr Akio Katanuma, Dr Taku Harada, Dr Hidetaka Hamamoto, Dr Hironori Aoki, and Dr Yuki Murakami of the Center for Gastroenterology, Teine Keijinkai Hospital, Sapporo, Japan, for their kind support of this article.

Abbreviations: ESD, endoscopic submucosal dissection; M-loop, multiloop.

REFERENCES

1. Sakamoto N, Osada T, Shibuya T, et al. The facilitation of a new traction device (S-O clip) assisting endoscopic submucosal dissection for superficial colorectal neoplasms. *Endoscopy* 2008;40:E94-5.
2. Yamasaki Y, Takeuchi Y, Hanaoka N, et al. A novel traction method using an endoclip attached to a nylon string during colonic endoscopic submucosal dissection. *Endoscopy* 2015;47:E238-9.
3. Mori H, Rahman A, Kobara H, et al. Novel and effective countertraction using a ring-shaped thread for safer gastric and colorectal endoscopic submucosal dissection. *Gastrointest Endosc* 2016;84:735-6.
4. Matsuzaki I, Isobe S, Hirose K, et al. Magnetic anchor-guided endoscopic submucosal dissection for colonic tumor. *VideoGIE* 2017;2:74-5.
5. Nomura T, Kamei A, Sugimoto S, et al. Colorectal endoscopic submucosal dissection using the "dental floss with rubber band method." *Endoscopy* 2018;50:E78-80.

Center for Gastroenterology, Teine Keijinkai Hospital (1), Department of Gastroenterology and Hepatology, Sapporo Medical University School of Medicine (2), Sapporo, Japan.

Copyright © 2018 American Society for Gastrointestinal Endoscopy. Published by Elsevier Inc. This is an open access article under the CC BY-NC-ND license (<http://creativecommons.org/licenses/by-nc-nd/4.0/>).

<https://doi.org/10.1016/j.vgje.2018.10.002>