



Non-communicating hydrocephalus from pork tapeworm obstructing the foramina of Monro and its endoscopic management; a case report from Europe



F. Hamre, MD, MSc^a, G. Rodríguez-Boto, MD, PhD, MSc^{a,b}, E. Tejerina, MD, PhD^c, E. Muñoz, MD^d, A. Zamarrón, MD^a, R. Gutiérrez-González, MD, PhD, MSc^{a,b,*}

^a Department of Neurosurgery, Puerta de Hierro University Hospital, Joaquín Rodrigo 2, 28222, Madrid, Spain

^b Department of Surgery, Faculty of Medicine, Autonomous University of Madrid, Arzobispo Morcillo 4, 28029, Madrid, Spain

^c Department of Pathological Anatomy Puerta de Hierro University Hospital, Joaquín Rodrigo 2, 28222, Madrid, Spain

^d Department of Infectious Diseases, Puerta de Hierro University Hospital, Joaquín Rodrigo 2, 28222, Madrid, Spain

ARTICLE INFO

Keywords:

Case report
Endoscopic third ventriculostomy
Hydrocephalus
Neurocysticercosis
Ventriculoperitoneal shunt

ABSTRACT

Introduction: *Taenia solium* is the main causative agent of neurocysticercosis. The tapeworm can manifest inside the ventricles, usually in the form of intracranial hypertension. We present a case of hydrocephalus as a result of a neurocysticercosis lesion obstructing both foramina of Monro.

Research question: A comprehensive review of the management is provided, as well as video footage (an invaluable resource to compare, critique and learn with other institutions).

Material and methods: A 23-year-old female from Honduras presented with a 7-day complaint of headache. On exam, she was hyperreflexic, but otherwise normal. Magnetic resonance imaging (MRI) revealed a non-specific lesion at the level of the foramina of Monro, with associated hydrocephalus. Additional testing was normal.

Results: The patient underwent an endoscopic ventriculostomy with partial excision of the lesion and subsequent implantation of a ventriculoperitoneal shunt. On postoperative MRI, hydrocephalus resolved and pathological analysis identified the parasite as *Taenia solium*. Albendazole was administered for 14 days.

Discussion and conclusion: Neurocysticercosis should be considered in patients presenting with hydrocephalus, especially those from endemic areas. The long-term prognosis of ventricular neurocysticercosis might be favourable, provided that adequate care is given timely. Endoscopic surgery seems to be effective for the removal of parasitic lesions. However, studies comparing open versus endoscopic surgery are lacking. The majority of cases in the literature correspond to America and Asia. This case shows that neurocysticercosis is also present in Europe, and that a high index of suspicion is necessary.

1. Introduction

Neurocysticercosis is an infection of the pork tapeworm *Taenia solium* acquired by accidental ingestion of *T. solium* eggs (Couldwell and Apuzzo, 1992; Vedantam et al., 2016; Couldwell et al., 1995). It represents the most common cause of intracranial cystic lesions worldwide and its incidence is increasing in developed countries as a result of increasing immigration from endemic areas (Couldwell et al., 1995). The most common intracranial manifestation involves the brain parenchyma and the subarachnoid space in the convexity, followed by the subarachnoid cisterns (Marcin Sierra et al., 2017). Most cases are asymptomatic, but when they do manifest clinically, they do so in the form of

seizures (Couldwell and Apuzzo, 1992; Marcin Sierra et al., 2017). Intraventricular cysticercosis has traditionally been thought of as a rare occurrence, but some series suggest that it can be seen in 15 to 54% of patients with neurocysticercosis (Couldwell et al., 1995; Marcin Sierra et al., 2017). The most common intraventricular location is the fourth ventricle, although in some series, this trend is reversed, with more patients harbouring cysts at the level of the third ventricle (Kaif et al., 2019). Intraventricular presentation classically implies a worse prognosis than its intraparenchymal counterpart. These lesions are very dangerous, as they can produce acute hydrocephalus and sudden death (Neal, 1995). The mainstay of treatment involves surgical excision of the cyst and restoration of cerebrospinal fluid (CSF) flow (Couldwell and Apuzzo,

* Corresponding author. Department of Neurosurgery, Puerta de Hierro University Hospital, Joaquín Rodrigo 2, 28222, Madrid, Spain.

E-mail address: raquel.gutierrez@uam.es (R. Gutiérrez-González).

<https://doi.org/10.1016/j.bas.2022.100866>

Received 14 December 2021; Received in revised form 9 January 2022; Accepted 16 January 2022

Available online 20 January 2022

2772-5294/© 2022 The Authors. Published by Elsevier B.V. on behalf of EUROSPINE, the Spine Society of Europe, EANS, the European Association of Neurosurgical

Societies. This is an open access article under the CC BY-NC-ND license (<http://creativecommons.org/licenses/by-nc-nd/4.0/>).

1992; Kaif et al., 2019).

We present a case of third ventricular neurocysticercosis that coursed with severe ventriculitis and hydrocephalus, and that was approached with neuroendoscopy. We also review subsequent treatment and management. All the cases reported correspond to either the Asian or American continent. This case proves that a high index of suspicion is required even in Europe. Finally, video footage is also included, an invaluable resource for learning and comparing surgical technique with other institutions.

2. Case description

A 23-year-old woman with no significant medical history, originally from Honduras, but having lived in Spain for the previous two years, presented with a 7-day complaint of intense headache, predominantly frontal, with associated nausea. She denied having had visual nor gait symptoms. She mentioned having had recent weight gain, but without associated dysthermia, polyuria nor mood changes. On exam, she was hyper-reflexic, with everything else being normal, including a fundoscopic examination.

Initial imaging with computed tomography (CT) was performed, revealing significant dilation of the lateral ventricles, with associated periventricular hypodensity and transependymal reabsorption, with the third and fourth ventricles having normal morphology (Fig. 1A). Contrast administration did not detect any abnormal enhancement nor lesions that could justify the expanded ventricular size. A complementary study with magnetic resonance imaging (MRI) confirmed clear signs of active hydrocephalus and ventriculitis (Fig. 1B–C) and the presence of a pseudonodular lesion in the third ventricle (Fig. 1D–E; arrow). The lesion was intrinsically hypointense on T1, with some degree of enhancement post-contrast and hyperintensity, on T2 and FLAIR sequences.

Steroids were administered, with her symptoms improving. An extensive work-up in serum was performed, including serology, tumour

markers and enzyme assays. All of them were negative. A lumbar puncture was considered for CSF analysis, but given the high suspicion of intracranial hypertension, it was ruled out. The patient underwent elective surgery under general anaesthesia, consisting of an endoscopic ventriculoscopy. Upon opening the dura, an external ventricular catheter was first placed in order to measure intracranial pressure and collect CSF samples for cytology, biochemistry and culture. CSF outflow pressure was raised over 15 cm of H₂O. The catheter was then removed and a ventriculoscopy evidenced a yellowish lesion, obstructing the foramen of Monro on both sides (Fig. 2; Video). Subtotal resection was carried out and sent to the pathology lab for analysis. The remaining part of the lesion was inaccessible, occupying said foramen and impeding access to the third ventricle. Besides that, the lesion was prone to hemorrhage all throughout the procedure due to dense adherences to the surrounding ependyma, and rigorous haemostasis was carried out. Septostomy to communicate both lateral ventricles was also performed. Next, a ventriculo-peritoneal shunt was inserted, using Bactiseal® catheters and connecting them to a programmable valve with an anti-siphon device. Valve pressure was programmed at 120 cm of H₂O.

Supplementary video related to this article can be found at <https://doi.org/10.1016/j.bas.2022.100866>

Post-operatively, recovery was uneventful and patient's headaches improved. CSF cytology, biochemistry and culture were normal. Chagas, *Strongyloides* and *Taenia solium* serologies in serum were all negative, as well as the stool parasite exam. However, on gross pathological examination of the resected lesion, a larva joined to a vesicle with cilia on its surface, an intermediate nucleated layer and an internal parenchymal layer could be visualized. The parasite was identified as *Taenia solium* (Fig. 3). The patient subsequently completed therapy with albendazol for 14 days and was then discharged home without hydrocephalus but with mild symptoms related to forniceal damage.

Six weeks after the procedure the patient presented with distal catheter infection due to *Acinetobacter pittii* and *Acinetobacter baumannii*.

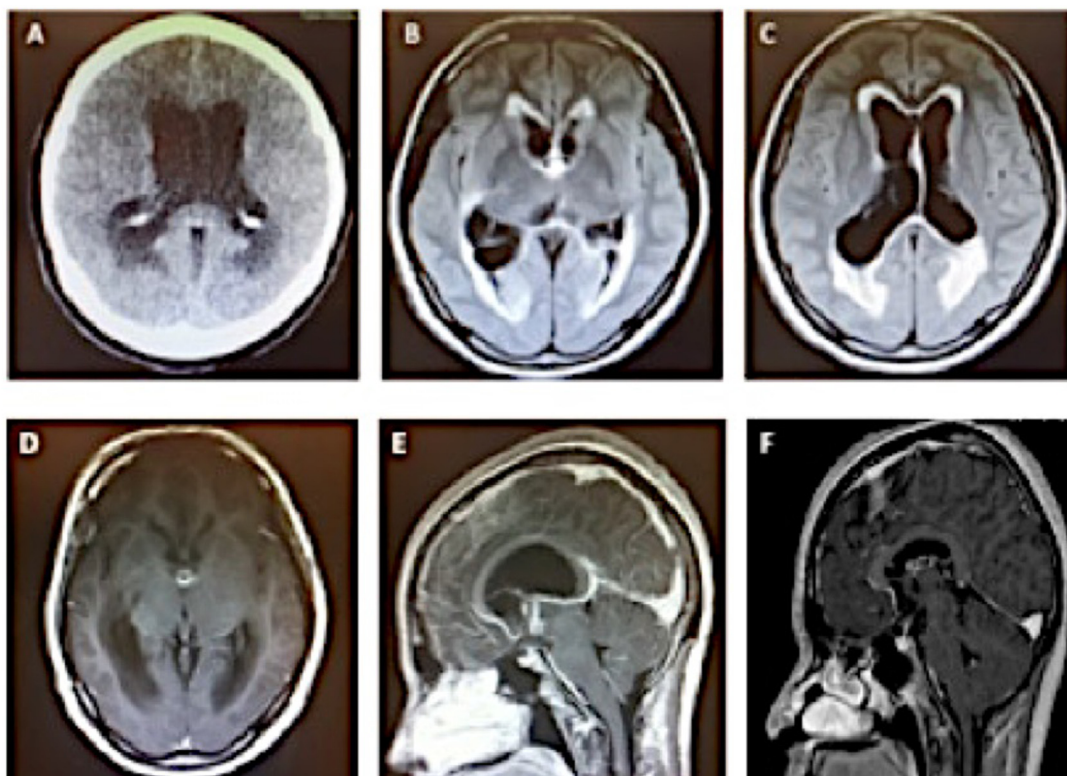


Fig. 1. (A) Axial CT, showing dilation of the lateral ventricles. (B, C) Axial MRI FLAIR sequences, showing hyperintense rim surrounding the ventricles, corresponding to ventriculitis. D,E. Axial T1 post-contrast (D) and sagittal T1 post-contrast (E) sequences, showing the same nodular lesion (arrow), preoperatively. (F) Sagittal T-1 post-contrast, postoperatively.

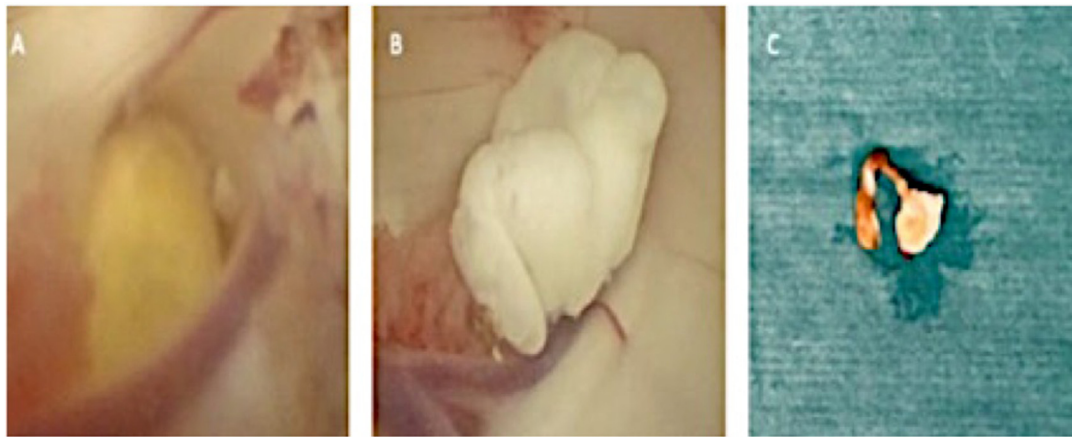

Fig. 2. (A) Endoscopic view of the right-sided foramen of Monro, pre-resection. (B) Endoscopic view of the right-sided foramen of Monro, during resection. (C) Macroscopic view of the parasite, after resection.

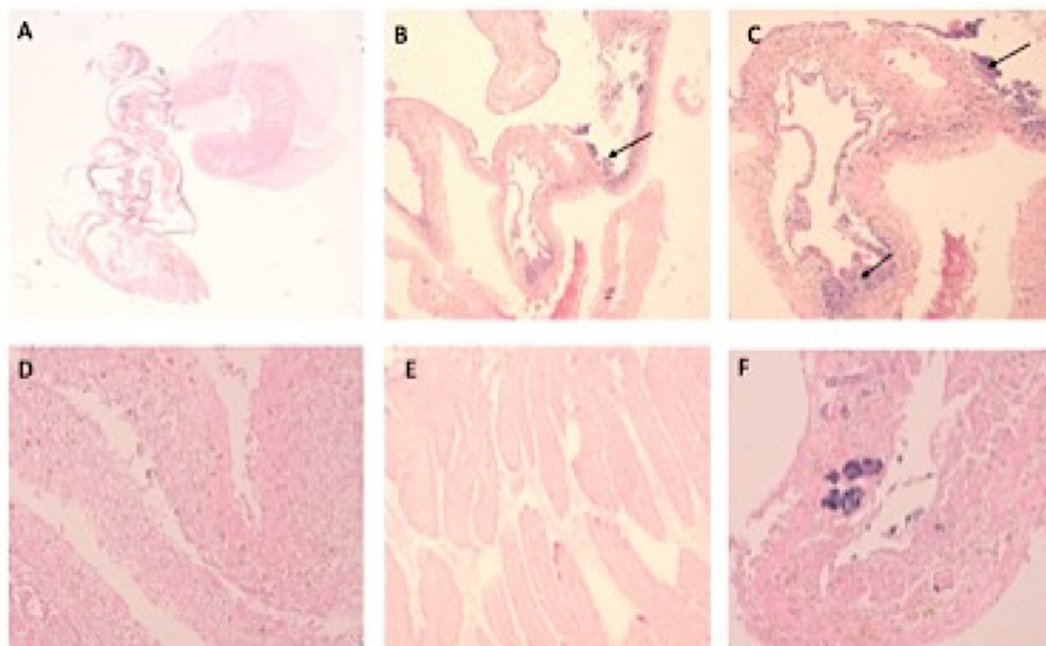


Fig. 3. A-F. Microscopic views of *Taenia solium* (hematoxylin and eosin staining) at increasing magnifications. (A) Global panoramic of the entire parasite; macro-micro, H-E. (B-D) Patient-parasite inflammatory interphase, with neutrophilic reaction (arrows); 20x (B,C), 40x (D), H-E. (E) High-power view of the parasite; 40x, H-E. (F) Parts of the parasite undergoing calcification (arrowhead); 40x, H-E.

She required shunt removal, external ventricular drainage placement and endovenous antibiotic therapy. The shunt was replaced since the patient did not tolerate catheter closure. One year later, the patient is asymptomatic and follow-up MRI does not show lesions (Fig. 1F).

3. Discussion

Neurocysticercosis is an infection of the Central Nervous System (CNS) by the larva of the pork tapeworm, *Taenia solium*. It is the most common parasitic infestation of the CNS. It also constitutes the most frequent cause of seizures in endemic areas (predominantly Central and South America, Asia, Africa and Eastern Europe), where intermediate host animals (pigs) are in close contact with humans and human feces, usually as a result of poor hygiene (Rapoport et al., 2014; Del Brutto, 2018). The disease is a major global cause of acquired epilepsy. While most cases of neurocysticercosis manifest with parenchymal and/or subarachnoid space involvement (the range of brain parenchymal

involvement in patients with neurocysticercosis ranges from 60 to 92%), intraventricular neurocysticercosis is less common (Couldwell and Apuzzo, 1992; Marcin Sierra et al., 2017). The predilection is for highly vascularized areas, such as the occipital horns at the level of the lateral ventricles and the fourth ventricle. Intraventricular cases may present with seizures, especially when they have concomitant parenchymal lesions (Cuetter and Andrews, 2002). Otherwise, symptoms of intracranial hypertension are more likely to appear in ventricular neurocysticercosis (Marcin Sierra et al., 2017; Cuetter and Andrews, 2002).

Patients with intraventricular cysticercal cysts can also present with features of raised intracranial pressure, as in the case hereby reported. CT or MRI usually show hydrocephalus. The cyst inside the ventricle poses diagnostic challenges from a radiological point of view; not only because it is difficult to identify the cyst (it has the same signal intensity as the surrounding CSF both on MRI and CT and it isn't distinguishable without contrast inside the ventricular chamber). This may explain the lack of lesions on the initial CT performed. One must also consider a broad

differential diagnosis of the lesion; the main differentials include colloid cysts, arachnoid cysts, hydatid cysts and ependymal cysts (Shah et al., 2016). In this patient's case, even neurosarcoidosis and germinoma were entertained as diagnostic options. In the case of neurocysticercosis, sometimes the scolex can be identified on imaging as a hyperintense dot within the cyst, which wasn't the case here. The intrinsic low signal on T1 sequences, together with the peripheral enhancement post-contrast and the high signal on T2 and FLAIR led us in fact to believe it was initially a colloid cyst. Traditionally, neurocysticercal cysts are intrinsically T1 hyperintense as cyst degenerates. However, they may present similar signal intensity to CSF in the vesicular stage (Couldwell et al., 1995). The location, size, radiologic characteristics, together with a normal follow-up study, were all compatible with a diagnosis of colloid cyst. However, given the patient's background, the epidemiologic context and the severe ependymitis, neurocysticercosis wasn't totally ruled out.

The best documented serological test for cysticercosis is the enzyme-linked immunoelectrotransfer blot (EITB) assay, which detects antibodies to *Taenia solium* in serum and CSF. Its sensitivity is around 98% for patients with two or more live parasites in the nervous system, thus people with more than one viable cyst or subarachnoid disease at the time of testing will have a positive serology. Enzyme-linked immunosorbent assay (ELISA) is also a useful tool to detect both antigens and antibodies. A negative serology in patients should lead to the investigation of alternative diagnoses. The sensitivity of antibody detection is, however, poorer in patients with calcified cysticerci (Marcin Sierra et al., 2017; Garcia et al., 2014). This serological and pathological dissociation, then, is unusual, but could be explained by the parasite being calcified (which was observed after surgery, with histopathological examination under the microscope) and/or the presence of a single lesion. Partial calcification and the intense ependymal inflammation observed in MRI point to an involucional cyst. In these cases (and whenever the parasite is still active), antibodies are more likely to be identified in CSF rather than serum (Marcin Sierra et al., 2017).

A group of international experts in cysticercosis published a consensus statement regarding the management of neurocysticercosis (Garcia et al., 2014). Surgical management for neurocysticercosis is recommended for extraparenchymal, intraventricular cysts and in hydrocephalus due to ependymitis caused by neurocysticercosis, amongst other indications (Rajshekhar, 2010). The patient fulfilled these two criteria. The procedure of choice at the present moment is the minimally invasive endoscopic removal of the cyst (Kaif et al., 2019; Rajshekhar, 2010; Zhenye et al., 2017; Nash et al., 2018). Because the pathophysiology of intraventricular neurocysticercosis is similar to other intraventricular conditions, it is believed that ventriculoscopy provides a safe and effective way of treating these lesions. While endoscopy avoids complications associated with a standard craniotomy, and is generally safe, it still carries some morbidity; the major complications from endoscopic surgery include intraventricular hemorrhage, forniceal damage, CSF leak, seizures and meningitis. These complications occur in less than 5% of patients (Rajshekhar, 2010; Bergsneider et al., 2000).

During the procedure, the cyst was densely adherent to the surrounding ependyma, which was expected, given the important associated ependymitis observed on FLAIR sequences of the preoperative MRI. This is why only partial resection was obtained, with remaining obstruction at the left-sided foramen of Monro. A shunt was placed and a septostomy was performed to communicate both lateral ventricles, with a view of relieving potential persistent hydrocephalus. Couldwell and Apuzzo (1992) describe their experience when treating endoscopically cases with significant ependymitis on preoperative imaging. They advocate for the implantation of a primary CSF diversion device; as the majority of patients will go on and develop persistent hydrocephalus (Couldwell and Apuzzo, 1992). Other authors, however, suggest that endoscopy alone facilitates safe excision while obviating the need for shunt placement, through internal CSF diversion at the time of cyst removal (Rapoport et al., 2014). Thus, it is noteworthy the disparity of the optimal treatment modalities reported in the literature.

A common concern that is often voiced is the consequence of rupture of a ventricular cysticercal cyst during its removal. Most experienced surgeons haven't reported significant incidents associated with intraoperative rupture of these lesions with this procedure. In contrast to hydatid cysts, the rupture of an intraventricular cysticercal cyst during surgery doesn't lead to either dissemination of the disease or an anaphylactic reaction (Rajshekhar, 2010).

When it comes to medical management of neurocysticercosis, and ventricular neurocysticercosis in particular, this topic is controversial. Although the American Academy of Neurology recommends a combination of albendazole and dexamethasone or prednisone as treatment for parenchymal neurocysticercosis (the rationale behind this being that it can decrease the number of active lesions and reduce the risk of long-term seizures), at the present moment there are no randomized clinical trials designed to prove efficacy of these drugs for extraparenchymal disease (Baird et al., 2013).

Data on the timing of initiation of antihelminthic drugs is also lacking, although it has been reported that surgical treatment before medical therapy is necessary, as complications derived from antiparasitic medical treatment (mainly acute hydrocephalus and raised intracranial pressure due to the inflammatory reaction after the death of the parasites) may be detrimental to the patient (Zhenye et al., 2017). In the case hereby reported, the patient was treated with albendazole for 2 weeks, with concurrent corticosteroid administration. Simultaneous use of corticosteroids in the perioperative period and during treatment with antiparasitic drugs is also suggested in the literature. However, it must be pointed out that the quality of evidence is low because of the lack of well-designed randomized, controlled trials, despite some data favouring post-resection antihelminthic therapy (Baird et al., 2013; Khade et al., 2013).

There are few studies reporting the outcomes of intraventricular neurocysticercosis patients undergoing ventriculoscopy. However, some have reported that total lesion excision is associated with longer progression free survival and improved quality of life (Zhenye et al., 2017). Indeed, the outcome following surgery for intraventricular neurocysticercal cysts is generally reported to be excellent with over 95% of patients making a good recovery. One study found that 75% of patients with neurocysticercosis who underwent surgery improved after a 3-year follow-up period (Rajshekhar, 2010).

By contrast, it has also been reported that neurocysticercosis-associated hydrocephalus is associated with the need for repeated shunt revisions, and that this may be due to the high protein or cell content in the CSF (Rajshekhar, 2010; Sotelo and Marin, 1987; Colli et al., 1986). This happens in as many as 68% of patients, with a mortality of 50% (Rajshekhar, 2010). Thus, in a series of 69 patients, 67 of 88 reoperations (76,1%) were carried out in the first postoperative year and 77 (87,5%) in the first and second postoperative years. Reoperations were due to shunt malfunction in 68% of cases, ventricular catheter occlusion in 32%, distal catheter occlusion in 12%, CSF fistula in 10%, shunt replacement in 6%, nonobstructive malfunction in 4%, catheter rupture in 1%, and catheter extrusion also in 1% (Colli et al., 1986). However, it has also been reported that placement of a ventriculoperitoneal shunt followed by a course of antihelminthic medication seems to promote shunt longevity (Kelley et al., 2002). Other causes of reoperation reported are meningitis in 17% and other infections in 14% (Kelley et al., 2002). The most commonly isolated microorganisms in the patients with meningitis were *S. aureus* and *S. epidermidis*. Of all the microorganisms, there was no isolation of *Acinetobacter* spp., as was the case hereby reported (Colli et al., 1986).

All in all, further long-term follow-up studies are needed in order to clearly elucidate how these patients do in the long-run. The majority of the cases out in the literature correspond to the American and Asian continent. This case shows that neurocysticercosis is also present in Europe, and that a high index of suspicion must be maintained especially in patients originating from endemic areas. Additionally to the text, video footage is provided, which is generally lacking in the literature, in order

to serve as a visual guide for the steps taken to surgically manage the lesion. It provides an invaluable resource, not only for showing what is done at our institution, but to compare, critique and learn together with other institutions.

4. Conclusions

A diagnosis of neurocysticercosis should be entertained in patients presenting with hydrocephalus, especially in patients originally from endemic areas. The involvement of the ventricular system goes beyond only the fourth ventricle, and can affect it in its entirety. The long-term prognosis of patients with ventricular neurocysticercosis might be favourable, provided that adequate care is given on time. Endoscopic surgery seems to be effective for the removal of cysticercal cysts inside the ventricular system. However, studies comparing open versus endoscopic surgery are lacking. The timing, dosage, duration and concomitant therapy of antiparasitic medication and corticosteroids must also be investigated further with high-quality studies.

Funding

No; no external funding was received.

Conflicts of interest

No conflicts of interest to disclose.

Availability of data and material

Yes; all the data was obtained from the hospital's electronic medical records.

Code availability

Not applicable.

Ethics approval

Not applicable; the article reports the description of an exceptional case, where no research, no intervention, or procedure away from clinical practice has been performed on the subject. Thus, no ethics approval has been applied, according to the institution's policy.

Consent for publication

Written informed consent was obtained from the patient for publication of this case report and any accompanying images. A copy of written consent is available for review by the Editor of the journal if necessary.

Authors' contributions

GG, FH and GRB have conceived the research and drafted the manuscript; ET, EM and AZ have made critical revision of the manuscript for important intellectual contribution. All authors have read and

approved the final manuscript and have agreed both to be personally accountable for the author's own contributions and to ensure that questions related to the accuracy or integrity of any part of the work.

References

- Baird, R.A., Wiebe, S., Zunt, J.R., Halperin, J.J., Gronseth, G., Roos, K.L., 2013. Evidence-based guideline: treatment of parenchymal neurocysticercosis: report of the guideline development subcommittee of the American Academy of Neurology. *Neurology* 80, 1424–1429. <https://doi.org/10.1212/WNL.0b013e31828c2f3e>.
- Bergsneider, M., Holly, L.T., Lee, J.H., King, W.A., Frazee, J.G., 2000. Endoscopic management of cysticercal cysts within the lateral and third ventricles. *J. Neurosurg.* 92, 14–23. <https://doi.org/10.3171/jns.2000.92.1.0014>.
- Colli, B.O., Martelli, N., Assirati Jr., J.A., Machado, H.R., de Vergueiro Forjaz, S., 1986. Results of surgical treatment of neurocysticercosis in 69 cases. *J. Neurosurg.* 65, 309–315. <https://doi.org/10.3171/jns.1986.65.3.0309>.
- Couldwell, W.T., Apuzzo, M.L., 1992. Cysticercosis cerebri. *Neurosurg Clin N Am* 3, 471–481.
- Couldwell, W.T., Chandrasoma, P., Apuzzo, M.L., Zee, C.S., 1995. Third ventricular cysticercal cyst mimicking a colloid cyst: a case report. *Neurosurgery* 37, 1200–1203. <https://doi.org/10.1227/00006123-199512000-00021>.
- Cueter, A.C., Andrews, R.J., 2002. Intraventricular neurocysticercosis: 18 consecutive patients and review of the literature. *Neurosurg. Focus* 12. <https://doi.org/10.3171/foc.2002.12.6.e5>.
- Del Brutto, O.H., 2018. Ventricular neurocysticercosis: a severe form of the disease waiting for well-designed therapeutic trials. *Am. J. Trop. Med. Hyg.* 98, 1553–1554. <https://doi.org/10.4269/ajtmh.18-0203>.
- García, H.H., Nash, T.E., Del Brutto, O.H., 2014. Clinical symptoms, diagnosis, and treatment of neurocysticercosis. *Lancet Neurol.* 13, 1202–1215. [https://doi.org/10.1016/S1474-4422\(14\)70094-8](https://doi.org/10.1016/S1474-4422(14)70094-8).
- Kaif, M., Husain, M., Ojha, B.K., 2019. Endoscopic management of intraventricular neurocysticercosis. *Turk Neurosurg* 29, 59–65. <https://doi.org/10.5137/1019-5149.JTN.21389-17.3>.
- Kelley, R., Duong, D.H., Locke, G.E., 2002. Characteristics of ventricular shunt malfunctions among patients with neurocysticercosis. *Neurosurgery* 50, 757–762. <https://doi.org/10.1097/00006123-200204000-00014>.
- Khade, P., Lemos, R.S., Toussaint, L.G., 2013. What is the utility of postoperative antihelminthic therapy after resection for intraventricular neurocysticercosis? *World Neurosurg* 79, 558–567. <https://doi.org/10.1016/j.wneu.2011.05.053>.
- Marcin Sierra, M., Arroyo, M., Cadena Torres, M., Ramírez Cruz, N., García Hernández, F., Taboada, D., Galicia Martínez, Á., Govezensky, T., Sciuotto, E., Toledo, A., Fleury, A., 2017. Extraparenchymal neurocysticercosis: demographic, clinicoradiological, and inflammatory features. *PLoS Neglected Trop. Dis.* 11, e0005646. <https://doi.org/10.1371/journal.pntd.0005646>.
- Nash, T.E., Ware, J.M., Mahanty, S., 2018. Intraventricular neurocysticercosis: experience and long-term outcome from a tertiary referral center in the United States. *Am. J. Trop. Med. Hyg.* 98, 1755–1762. <https://doi.org/10.4269/ajtmh.18-0085>.
- Neal, J.H., 1995. An endoscopic approach to cysticercosis cysts of the posterior third ventricle technique and application. *Neurosurgery* 36, 1040–1043. <https://doi.org/10.1227/00006123-199505000-00026>.
- Rajshankar, V., 2010. Surgical management of neurocysticercosis. *Int. J. Surg.* 8, 100–104. <https://doi.org/10.1016/j.ijsu.2009.12.006>.
- Rapaport, B.I., Baird, L.C., Cohen, A.R., 2014. Third-ventricular neurocysticercosis: hydraulic maneuvers facilitating endoscopic resection. *Childs Nerv Syst* 30, 541–546. <https://doi.org/10.1007/s00381-013-2273-7>.
- Shah, H.C., Jain, K., Shah, J.K., 2016. Endoscopic excision of intraventricular neurocysticercosis blocking foramen of Monro bilaterally. *Asian J Neurosurg* 11, 176–177. <https://doi.org/10.4103/1793-5482.175622>.
- Sotelo, J., Marin, C., 1987. Hydrocephalus secondary to cysticercotic arachnoiditis. A long-term follow-up review of 92 cases. *J. Neurosurg.* 66, 686–689. <https://doi.org/10.3171/jns.1987.66.5.0686>.
- Vedantam, A., Daniels, B., Lam, S., 2016. Intraventricular cyst causing acute obstructive hydrocephalus: neurocysticercosis managed with neuroendoscopy. *Pediatr. Neurol.* 55, 71–73. <https://doi.org/10.1016/j.pediatrneurol.2015.09.015>.
- Zhenye, L., Chuzhong, L., Xuyi, Z., Songbai, G., Peng, Z., Jiwei, B., Lei, C., Xinsheng, W., 2017. Ventriculoscopic approach for intraventricular neurocysticercosis: a single neurosurgical center's experience. *World Neurosurg* 107, 853–859. <https://doi.org/10.1016/j.wneu.2017.08.059>.