

# Bilateral mandibular condyle fractures: Should we open both?

### ABSTRACT

Bilateral condylar fractures are common but are frequently undertreated. In most of the cases, only one side is surgically addressed and the other side is managed conservatively. Bilateral condylar fractures lead to loss of ramal height bilaterally, accentuated anterior open bite, disruption of articular surfaces, and disc and muscle attachments. In a mandibular bilateral condylar fracture, even though open reduction and internal fixation (ORIF) is done on one side, a patient still needs Inter Maxillary Fixation (IMF) for 2–4 weeks postoperatively to correct occlusion and deviation. The possibility of doing ORIF on the other is never explored. Here, we present two cases of bilateral condylar fracture treated both sides by ORIF. The article discusses the advantages and new approach to consider treating both sides.

**Keywords:** Bilateral, condyle fracture, mandibular, open reduction and internal fixation

### INTRODUCTION

Condylar fractures are the most commonly reported fractures of the mandible, with the occurrence rate of 25%–35%.<sup>[1]</sup> Bilateral condylar fractures account for 40%–50% of the total condylar fractures.<sup>[2]</sup>

Bilateral condylar fractures lead to loss of ramal height bilaterally, accentuated anterior open bite, disruption of articular surfaces, and disc and muscle attachments. These are accompanied by alteration in maximal mouth opening, lateral excursions, and reduction in bite forces.<sup>[3]</sup>

The closed method of treatment was favored for a long time due to the fear of complications such as facial nerve injury, external scar, sialocele, and others. The complications associated with the closed method such as pain, arthritis, deviation of the mouth, inadequate restoration of ramal height, improper occlusion, and open bite allowed exploration of surgical methods.<sup>[1]</sup> With time and mastering of the surgical techniques, the open method has become the preferred choice for condylar fractures. With the developments in instrumentation, surgical techniques, and better understanding of the anatomy, there was a gradual

shift in approach toward the treatment of condylar fractures from nonsurgical/closed method to surgical/open method.

In 1983, Zide and Kent<sup>[4]</sup> suggested the relative and absolute indications for open reduction/surgery for mandibular condyle fractures, and they reported that in case of bilateral mandibular condyle fractures, at least one mandibular condyle has to be treated by surgical method in order to restore the vertical height of the ramus of mandible.

Studies favored open reduction and internal fixation (ORIF) on one side to restore ramal height in case of bilateral condylar fractures.

**KEDARNATH NAKKALAHALLI SESHAPPA,  
SHRUTHI RANGASWAMY**

Department of Oral and Maxillofacial Surgery, Rajarajeswari Dental College and Hospital, Bengaluru, Karnataka, India


**Address for correspondence:** Dr. Kedarnath Nakkalahalli Seshappa,  
Department of Oral and Maxillofacial Surgery, Rajarajeswari Dental College and Hospital, Ramohalli Cross, Mysore Road, Bengaluru - 560 074, Karnataka, India.  
E-mail: kedarnathns@gmail.com

**Received:** 02 February 2019, **Revised:** 29 August 2019,  
**Accepted:** 27 September 2019, **Published:** 16 December 2020

This is an open access journal, and articles are distributed under the terms of the Creative Commons Attribution-NonCommercial-ShareAlike 4.0 License, which allows others to remix, tweak, and build upon the work non-commercially, as long as appropriate credit is given and the new creations are licensed under the identical terms.

**For reprints contact:** WKHLRPMedknow\_reprints@wolterskluwer.com

**How to cite this article:** Seshappa KN, Rangaswamy S. Bilateral mandibular condyle fractures: Should we open both? Natl J Maxillofac Surg 2020;11:285-8.

Access this article online	
<b>Website:</b> www.njms.in	<b>Quick Response Code</b> 
<b>DOI:</b> 10.4103/njms.NJMS_10_19	

There are no studies regarding surgical reduction on both sides in bilateral condylar fractures of the mandible.

The purpose of this article is to present the surgical outcome of bilateral condylar fracture after ORIF on both sides in two cases and discuss the advantages and limitation.

## CASE REPORTS

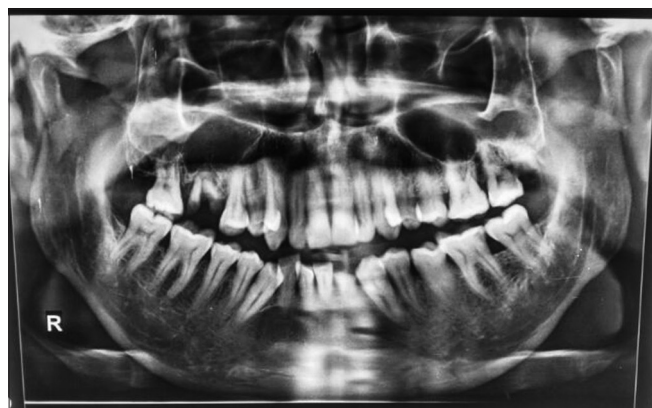### Case 1

A 43-year-old male patient reported to us with the chief complaint of pain on mouth opening and difficulty to chew following the road traffic accident (RTA). The patient's vitals were stable with Glasgow Coma Scale-15.

On examination, edema and tenderness noted over chin and temporomandibular joint region bilaterally. Abnormal mobility of the mandible was present over the left parasymphysis region with deranged occlusion. Orthopantomogram revealed left parasymphysis fracture and bilateral subcondylar fractures of the mandible.

The patient underwent ORIF under general anesthesia (GA), arch bar splinting of the maxilla and mandible was done, and IMF was placed with teeth in occlusion. Vestibular degloving incision was utilized to approach the left parasymphysis fracture, and right-side subcondylar fracture was surgically opened through retromandibular approach, condylar stump reduced, and fixation done with 2-mm titanium delta plate. No difficulties were encountered intraoperatively. Left-side subcondylar fracture was opened similarly, reduction and fixation of fracture done with 2-mm 4-holed titanium miniplate [Figures 1 and 2]. Occlusion and jaw movements were checked after releasing IMF. Watertight closure of the parotid capsule was ensured.

Postoperatively, on day 1, occlusion and jaw movements were checked along with any deficits of facial nerve branches. No



**Figure 1:** Preoperative orthopantomogram showing bilateral low condylar fractures and left parasymphysis fracture

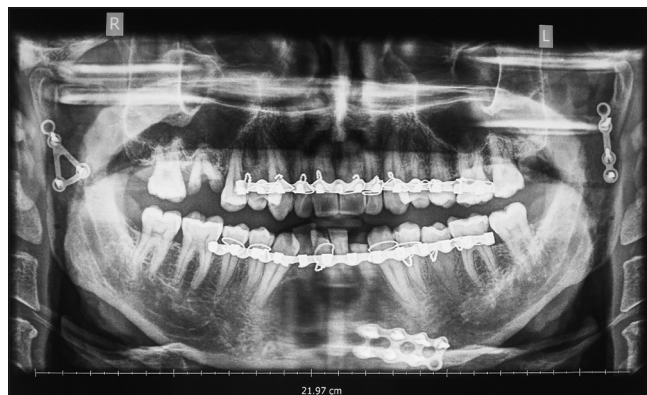abnormalities were noted. The patient was on a soft diet from the first postoperative day and was discharged in good general condition on the 3<sup>rd</sup> postoperative day. Follow-up was done.

### Case 2

A 30-year-old female patient reported to us with a history of RTA and ear bleed on the left side following the injury.

On examination, cut-lacerated wound was noted over the chin measuring about 5 cm × 1 cm in linear dimension, and lacerated wound was present over the upper lip. Tenderness over the chin and bilateral TMJ region was present. Step deformity of the mandible was present over the left parasymphysis region. Mouth opening was restricted to 20 mm on the day of the presentation. Left and right lateral movements were restricted. Anterior open bite was present, and deviation of the mandible to the left was noted. Computed tomography scan revealed parasymphysis fracture of the mandible, laterally displaced subcondylar fracture on the right side, and medially displaced condylar neck fracture on the left side.

The patient underwent ORIF under GA, arch bar splinting of the maxilla and mandible was done, and IMF placed with teeth in occlusion, through the existing wound over the chin, mandibular symphysis fracture was exposed, reduced and fixation done with 2-mm 4-holed titanium plate. Right-side subcondylar fracture was exposed through the retromandibular approach, and reduction and fixation of the fracture was done with trapezoidal plate. Left-side condylar neck fracture was similarly exposed, and reduction of the fracture was done with the help of traction of distal segment. Fixation was done with trapezoidal plate [Figures 3 and 4]. Postoperatively, mouth opening was 40 mm, and lateral excursions were good.



**Figure 2:** Postoperative orthopantomogram image showing fixation of the bilateral condyle fractures with delta plate on the right side and straight plate on the left side, with three-dimensional plate at left parasymphysis fracture

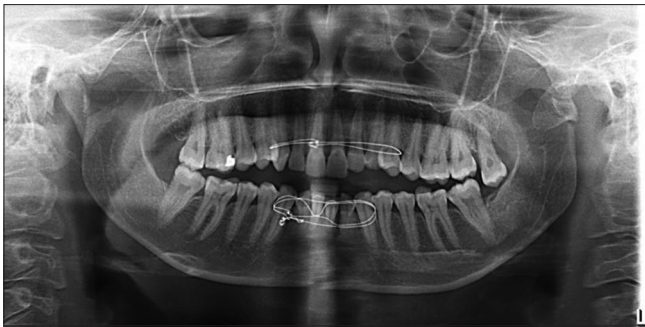

Figure 3: Preoperative orthopantomogram revealing right low condylar fracture and left condylar neck fracture and symphysis fracture of the mandible

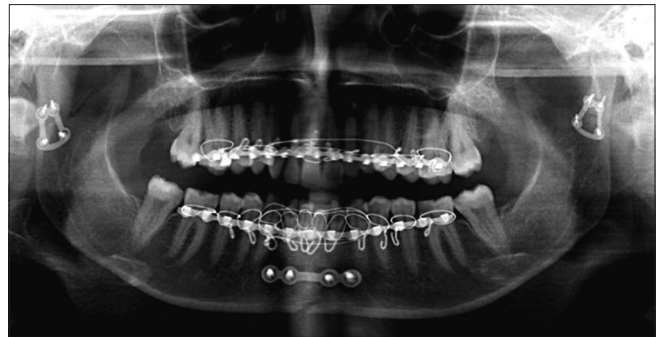

Figure 4: Postoperative orthopantomogram showing fixation of the bilateral condyle fractures with trapezoidal plate on both sides

## DISCUSSION

The aim of open reduction is to restore a correct anatomic relationship, resulting in good function of the masticatory system, including pain-free movement of the mandible, correct occlusion, and symmetry of the jaw.<sup>[5]</sup> Bilateral condylar fracture of the mandible is a more disruptive condition in which neither of the condyles retains the normal morphology than to a unilateral condylar fracture.<sup>[3]</sup>

García-Guerrero *et al.* in their meta-analysis compared conservative treatment and ORIF for mandibular condyle fractures and reported that there was less incidence of asymmetry, residual pain, and malocclusion in the ORIF group.<sup>[6]</sup> Marker *et al.*<sup>[7]</sup> reported that 21% of bilateral condylar fractures experienced TMJ pain, 15% developed reduced mouth opening, 8% had malocclusion, and 3% had deviation when treated conservatively. Gupta *et al.*<sup>[8]</sup> reported a better recovery of mandibular movements and a greater masticatory efficiency in the ORIF group when at least one condyle is addressed.

When one condyle has been treated by surgery in bilateral condylar fractures, it reduces the need for extensive remodeling; however, even though ORIF is done on one side to restore the vertical height of the ramus, the ramal height and masticatory efficiency are compromised on the contralateral side. The patients treated with closed method had a limitation of mouth opening and persistent anterior open bite requiring corrective surgeries indicating that ORIF was a better option for treating bilateral condylar fractures.

Newman<sup>[2]</sup> recommended that fixation of one displaced/dislocated condyle combined with IMF is effective to treat bilateral condylar fractures. However, Silvennoinen *et al.*<sup>[5]</sup> and Baker *et al.*<sup>[9]</sup> noted that this strategy did not always resolve ramus shortening.

In a mandibular bilateral condylar fracture, even though ORIF is done on one side, the patient still needs IMF for

2–4 weeks postoperatively to correct occlusion and deviation. Singh *et al.*<sup>[1]</sup> in their study observed that lateral excursion and protrusion were better in the ORIF group compared to the closed method group. In our both cases, there was no need of IMF, thereby leading to better comfort and early resumption to work.

It has been discussed that extensive dissection around TMJ might lead to compromised microcirculation and late resorption of the condyle. Chen *et al.*<sup>[10]</sup> reported no resorption, erosion, or sclerosis of fractured condyles after ORIF.

For severe condylar displaced/dislocated fractures, patients presenting with subcondylar fracture and condylar neck fracture in one or both sites (Type II or Type III), we recommend ORIF for bilateral sites. Major complications such as facial nerve injury and the need for revision are rare in the hands of sufficiently skilled surgeons, independently of the approach.

## CONCLUSION

Through these cases, we are of the opinion that in the cases of bilateral mandibular condylar fractures (subcondylar and condylar neck fractures) which are deviated/displaced/overriding, possibility of doing ORIF may be considered to restore early function and anatomic reduction.

## Financial support and sponsorship

Nil.

## Conflicts of interest

There are no conflicts of interest.

## REFERENCES

1. Singh V, Bhagol A, Dhingra R. A comparative clinical evaluation of the outcome of patients treated for bilateral fracture of the mandibular condyles. *J Craniomaxillofac Surg* 2012;40:464-6.

2. Newman L. A clinical evaluation of the long-term outcome of patients treated for bilateral fracture of the mandibular condyles. *Br J Oral Maxillofac Surg* 1998;36:176-9.
3. Throckmorton GS, Talwar RM, Ellis E 3<sup>rd</sup>. Changes in masticatory patterns after bilateral fracture of the mandibular condylar process. *J Oral Maxillofac Surg* 1999;57:500-8.
4. Zide MF, Kent JN. Indications for open reduction of mandibular condyle fractures. *J Oral Maxillofac Surg*. 1983;41:89-98.
5. Silvennoinen U, Iizuka T, Pernu H, Oikarinen K. Surgical treatment of condylar process fractures using axial anchor screw fixation: A preliminary follow-up study. *J Oral Maxillofac Surg* 1995;53:884-93.
6. García-Guerrero I, Ramírez JM, Gómez de Diego R, Martínez-González JM, Poblador MS, Lancho JL, *et al*. Complications in the treatment of mandibular condylar fractures: Surgical versus conservative treatment. *Ann Anat* 2018;216:60-8.
7. Marker P, Nielsen A, Bastian HL. Fractures of the mandibular condyle. Part 2: Results of treatment of 348 patients. *Br J Oral Maxillofac Surg* 2000;38:422-6.
8. Gupta M, Iyer N, Das D, Nagaraj J. Analysis of different treatment protocols for fractures of condylar process of mandible. *J Oral Maxillofac Surg* 2012;70:83-91.
9. Baker AW, McMahon J, Moos KF. Current consensus on the management of fractures of the mandibular condyle. A method by questionnaire. *Int J Oral Maxillofac Surg* 1998;27:258-66.
10. Chen CT, Feng CH, Tsay PK, Lai JP, Chen YR. Functional outcomes following surgical treatment of bilateral mandibular condylar fractures. *Int J Oral Maxillofac Surg* 2011;40:38-44.