

THYMIC LYMPHOMA WITH THYMIC CYST

Anwar Ul Haque, MD; Tawfiq Tamimi, MB,ChB,PhD; Mohammad Ashraf Ali, MD;
Charles E. Platz, MD

The thymic lymphoid tissue is occasionally a source of lymphoma while thymic epithelium may give rise to thymic cyst. However, co-occurrence of these two lesions is rather unusual. We describe such a curious association in a young Saudi male and discuss its pathogenesis.

Case Report

A 27-year-old Saudi male presented with a two month history of generalized fatigue, chest pain and palpitations with no dyspnea during vigorous exercise. The chest x-ray and the computed tomography (CT) scan with contrast enhancement revealed a well-demarcated "solid mass" in the left anterior mediastinum with peripheral and irregular central calcification (Figure 1). The pulmonary function tests suggested a mild upper airway obstruction.

The mass was resected in toto. Subsequently, the patient received adriamycin, cyclophosphamide and prednisone daily. About eight months later, he developed bilateral pleural effusion and ascites. The CT scan at that time revealed enlarged mesenteric lymph nodes. The ascitic and pleural fluid contained malignant T cells (stage II thymocytes). On lymphoma chemotherapy, his mesenteric lymph nodes disappeared but pleural effusion persisted. Afterward, he developed *Campylobacter jejuni* enteritis. Despite aggressive treatment, this patient's general health deteriorated, ending in death approximately one year after his first presentation to the hospital.

Pathological Examination

A 220 g, 13.5x8x6 cm smooth, shiny and multiseptate cyst containing chocolate colored clotted blood was received (Figure 2). The cyst wall and surrounding tissue contained a few 1 cm to 2.5 cm diameter fish flesh soft nodules. Some nodules were present on both sides of the

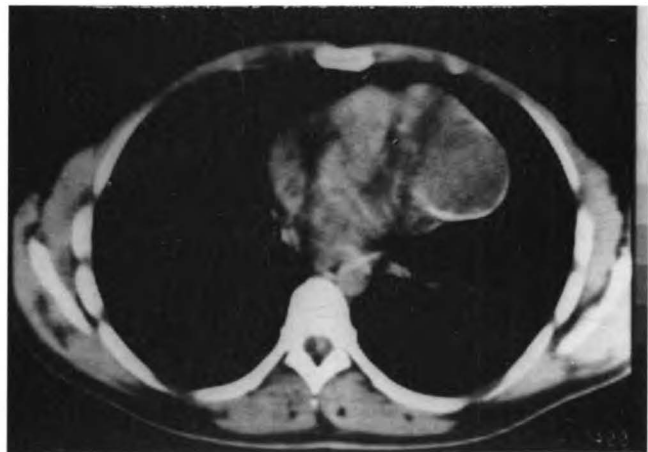

FIGURE 1. CT scan of thymic lymphoma with a large thymic cyst. Note the peripheral rimming by calcification. (Bar - 10 cm).

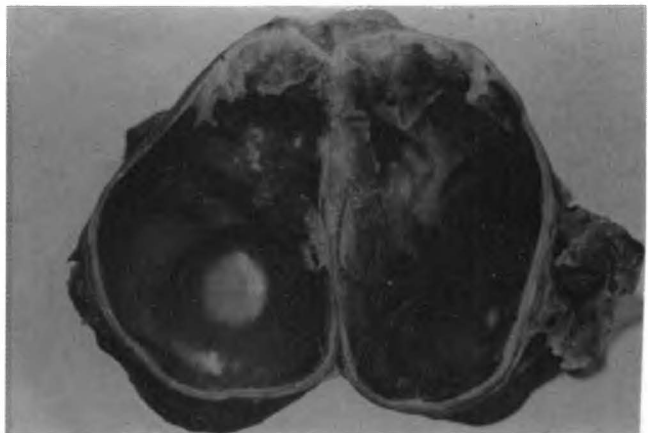


FIGURE 2. Gross appearance of the cyst. Note the "solid" area in the cyst wall.

cyst in dumbbell fashion. The cyst wall was focally calcified.

Histologically, the cyst wall focally contained hyperplastic thymic epithelium. There were focal hemosiderin deposits, cholesterol clefts and calcification in the cyst wall. The adjacent tissue contained residual thymic parenchyma.

The tumor nodules were composed of numerous neoplastic lymphoblasts with prominent starry sky pattern and focal brisk mitoses (Figure 3A). The malignant cells were about twice the size of normal lymphocytes and had

From the Departments of Pathology (Dr. Ul Haque) and Surgery (Dr. Tamimi), King Faisal University, College of Medicine and Medical Sciences, Dammam, Saudi Arabia; Department of Pathology (Dr. Ali), King Faisal Specialist Hospital and Research Centre, Riyadh, Saudi Arabia; and Department of Pathology (Dr. Platz), University of Iowa Hospital, Iowa City, Iowa, USA.

Address reprint requests and correspondence to Dr. Ul Haque: Associate Professor, Department of Pathology, King Faisal University, Dammam, P.O. Box 40054, Al-Khobar 31952, Saudi Arabia.

Accepted for publication 5 January 1994.

irregular cell membranes, better appreciated at oil immersion magnification (Figure 3B). The tumor cell

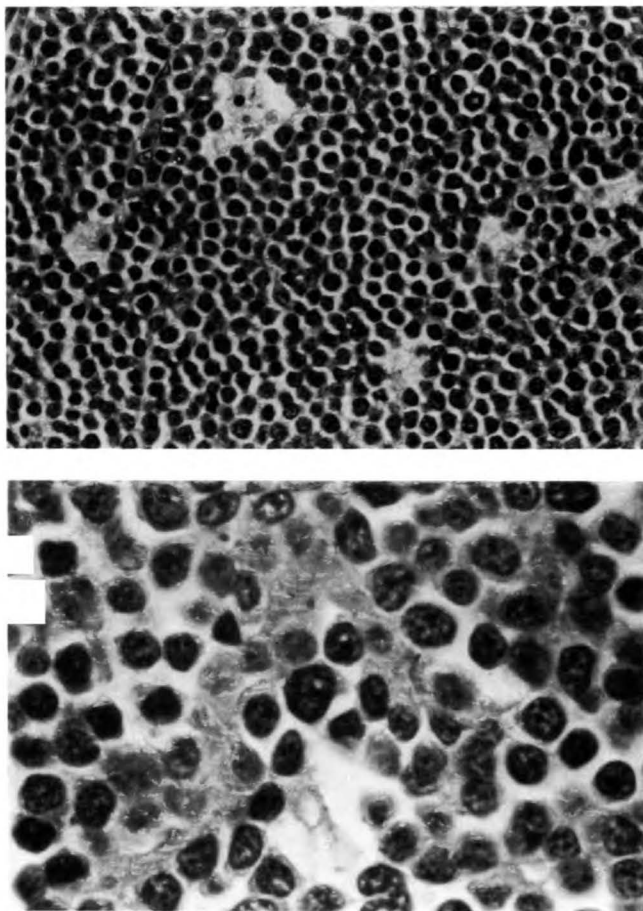


FIGURE 3. A. The lymphoblasts with convoluted nuclei and fine chromatin, scanty cytoplasm and starry sky appearance. (Hematoxylin and eosin 400x). B. (Inset Hematoxylin and eosin 1000x).

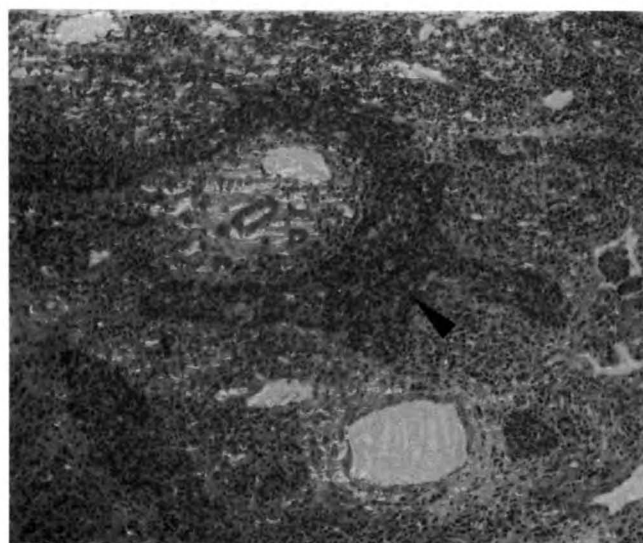


FIGURE 4. Thymic epithelial hyperplasia in the thymic cyst, positive for keratin. (Anti-keratin immunoperoxidase staining: 100x).

nuclei were round to oval with occasional indentations and convolutions and possessed finely dispersed granular and irregular chromatin. One or two small nonprominent basophilic nucleoli were seen. The cytoplasm was scanty and amphophilic.

The electron microscopy revealed large lymphoblastic nuclei with indented nuclear membranes. The chromatin was rather powdery. The cytoplasmic organelles were quite sparse. The thymic epithelial cells were large with relatively low nuclear/cytoplasmic ratio. The cytoplasm was organelle-rich and contained many mitochondria, desmosomes and occasional tonofilaments (Figure 4). The immunoperoxidase staining for keratin was strongly positive in the thymic epithelium (Figure 5). The lymphoma cells were negative for keratin, immunoglobulins and light chains. The pleural fluid lymphoma cells were positive for primitive T cell lymphoblasts (thymocytes stage II) markers.

Discussion

The thymus arises from the third branchial pouch derived thymopharyngeal duct.¹ The persistent remnant of this may give rise to a thymic cyst in the anterior mediastinum² and rarely, in the neck.³ The vast majority of the thymic cysts, however, appear to be acquired. These are secondary to inflammatory, degenerative and/or neoplastic processes. The epithelial cells from cortical, subcortical and Hassall's corpuscles may become hyperplastic and give rise to such cysts.⁴ Frequently, the epithelial lining of the cyst is completely lost, leaving embedded thymic tissue behind to foretell its thymic origin.

The lymphomas constitute the single largest malignant entity of the anterior mediastinum.⁵ They may arise from the lymph nodes within the mediastinum or from the thymus itself. In the latter case, usually prominent thymic tissue is present adjacent to the lymphoma.⁶ The majority of the mediastinal lymphomas are B cell type. These arise from nonthymus B lymphocytes.⁷ The mediastinal T cell lymphomas arise from both thymic lymphoid cells and nonthymic T lymphocytes.

The thymomas and lymphomas may undergo cystic degeneration with hyperplasia of thymic epithelium.^{8,9} Although such possibility cannot be completely excluded here, prominent thymic tissue, hyperplastic thymic epithelium and conspicuous calcification in the cyst wall suggest that the cyst probably existed prior to development of lymphoma.

Differentiating lymphocytic thymoma from a lymphoma may at times be quite taxing.¹⁰ The young age of the patient and aggressive behavior of the disease, particularly metastases below the diaphragm, favored the lymphoma over thymoma. The lymphocytes in thymomas are benign appearing while in the present case, they were quite

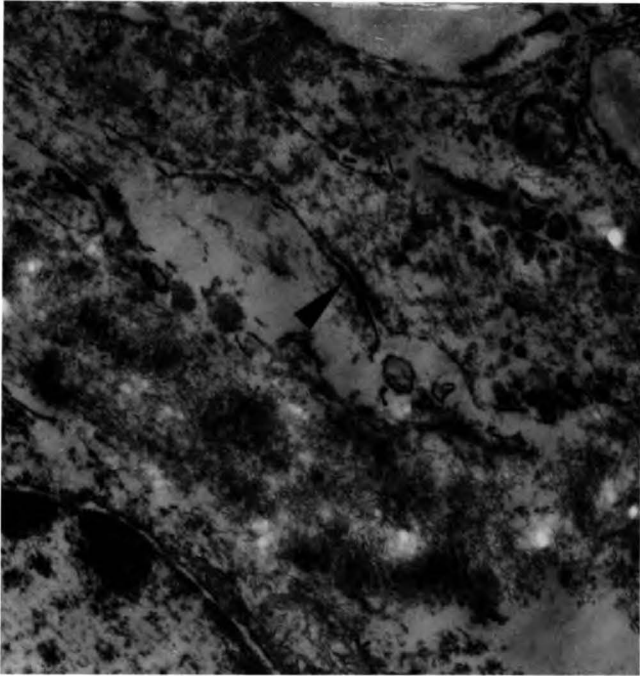


FIGURE 5. The thymic epithelial cell showing intercellular junction and tonofilaments (arrow) (EM 2800x).

aggressive with brisk mitoses and starry sky pattern. The ultrastructure and immunocytochemical markers also substantiated our diagnosis of lymphoma. In view of these criteria and clinical course, Levine and Rosai accepted very small numbers of reported cases as truly metastatic thymomas.¹¹

It is a well-known fact that thymic epithelium plays a crucial role in normal T cell (thymocyte) differentiation and maturation. Hence, nude athymic mice are quite immunodeficient and permit easy heterologous tumor implantation. It is therefore tempting to explore the role of the thymic epithelium in genesis of thymic lymphoma and thymic epithelial hyperplasia. Subclassifying mediastinal lymphomas on thymic and nonthymic origins may be an important step in this direction.

References

1. von Gaudecker B. The development of the human thymus microenvironment. In: Current topics in pathology. The human thymus. Muller-Hermelink HK, ed. Histophysiology and Pathology. Springer-Verlag 1986;75:1-44.
2. Bleger RC, MacAdams AJ. Thymic cysts. Arch Pathol 1966;82:535-41.
3. Ratnesar P. Unilateral cervical thymic cyst. J Laryngol Otol 1971;85:293-8.
4. Rosai J. Mediastinum. In: Ackerman's surgical pathology: mediastinum. CV Mosby, St. Louis, MO, USA 1989;345-90.
5. Davis RD Jr, Oldham HN Jr, Sabiston DC Jr. Primary cysts and neoplasms of the mediastinum: recent changes in clinical presentation, methods of diagnosis, management and results. Ann Thorac Surg 1987;44:229-37.
6. Hsu S-MJ. Phenotypic expression of T lymphocytes in thymus and peripheral lymphoid tissues. Am J Pathol 1985;121:69-78.
7. Ha K, Minden M, Hozumi N, Gelfand EW. Phenotypic heterogeneity at the DNA level in childhood leukemia with a mediastinal mass. Cancer 1985;56:509-13.
8. Smith PLC, Jobling C, Rees A. Hodgkin disease in a large thymic cyst in a child. Thorax 1983;38:392-3.
9. Dyer NH. Cystic thymomas and thymic cysts. a review. Thorax 1967;22:408-21.
10. Leong AS-Y, Brown JH. Malignant transformation in a thymic cyst. Am J Surg Pathol 1984;8:471-5.
11. Levine GD, Rosai J. Thymic hyperplasia and neoplasia: a review of current concepts. Hum Pathol 1978;9:495-515.