



# Giant Clinically Non-Functioning Pituitary Adenoma Presenting as New Onset Generalized Tonic–Clonic Seizures: A Case Report

Pumudu Weerasekara <sup>1</sup>, Nadeeka Chandraratne <sup>2</sup>, Sunil Lakshman Perera<sup>3</sup>

<sup>1</sup>Faculty of Medicine, University of Colombo, Colombo, 00800, Sri Lanka; <sup>2</sup>Department of Community Medicine, Faculty of Medicine, University of Colombo, Colombo, 00800, Sri Lanka; <sup>3</sup>Department of Neurosurgery, Asiri Central Brain & Spine Neurosurgical Group, Colombo, 01000, Sri Lanka

Correspondence: Pumudu Weerasekara, Faculty of Medicine, University of Colombo, No. 25 Kynsey Road, Colombo, Western Province, 00800, Sri Lanka, Email [w.pumudu@gmail.com](mailto:w.pumudu@gmail.com)

**Background:** Giant Clinically Non-Functioning Pituitary Adenomas (GCNFPA) are pituitary neuroendocrine tumours spanning beyond 4 cm in diameter without clinically apparent secretory function. They elicit insidious growth pertaining to its asymptomatic nature and present at large sizes from mass effect. Certain clinical features such as headache and visual disturbances are common presentations of GCNFPA's owing to their size, while others such as seizures are extremely rare.

**Case Report:** A 63-year-old woman presented with back-to-back generalized tonic clonic seizures to the A&E and was treated with Levetiracetam. Following initial normal blood investigations, a visual field analysis revealed a bitemporal upper quadrantanopia and further evaluation using MRI found a giant pituitary lesion with suprasellar extension through the third ventricle into the lateral ventricles with significant mass effect. She underwent neuro-navigation guided endonasal transsphenoidal subtotal resection 2 weeks later. The histological diagnosis of null cell adenoma with a Ki67 of 3% was made. At 3 months of follow-up, she is symptom free and monitored with serial MRIs.

**Conclusion:** Seizures are an uncommon presentation of GCNFPA's limited to a few case reports. This illustrates the importance of careful evaluation of patient presentations to correctly diagnose pituitary neoplasms and prioritizing symptom relief in choosing surgical approaches.

**Keywords:** pituitary neuroendocrine tumour, giant pituitary macroadenoma, case report

## Introduction

Pituitary Neuroendocrine Tumours (PitNET) or generally termed pituitary adenomas, are common benign primary brain tumours with varied presentations based on their functional status and morphological size.<sup>1</sup> PitNETs account for 15% of all primary brain tumours with an annual incidence of 94 cases per 100,000 population with a preponderance of females, particularly in the premenopausal period.<sup>2</sup> Radiologically, these tumours are classified as microadenomas or macroadenomas based on a cut-off of  $\geq 1$  cm in diameter, while giant macroadenomas expand beyond 4 cm in diameter. PitNETs are also classified based on their secretory activity as functional (hyperfunctional) or nonfunctional tumours.<sup>3,4</sup>

The clinical presentations of giant pituitary adenomas vary widely due to the influence of mass effects with visual impairments, visual field defects being the most common, but can extend to cranial nerve palsies, hypopituitarism or even features of tumour hormonal hypersecretion such as galactorrhoea, erectile dysfunction and/or acromegaly.<sup>4,5</sup> However, seizure development in patients with pituitary pathologies in general is rare and usually associated either secondary to electrolyte abnormalities at presentation or a complication of medical treatment in the case of giant prolactinomas.<sup>6</sup>

The first line management of giant pituitary adenomas except prolactinomas is surgery with the objective of safe resection while preserving neurological function. Different approaches such as transsphenoidal and transcranial are utilized but have been expanded with the introduction of endonasal endoscopic transsphenoidal surgery.<sup>4</sup>

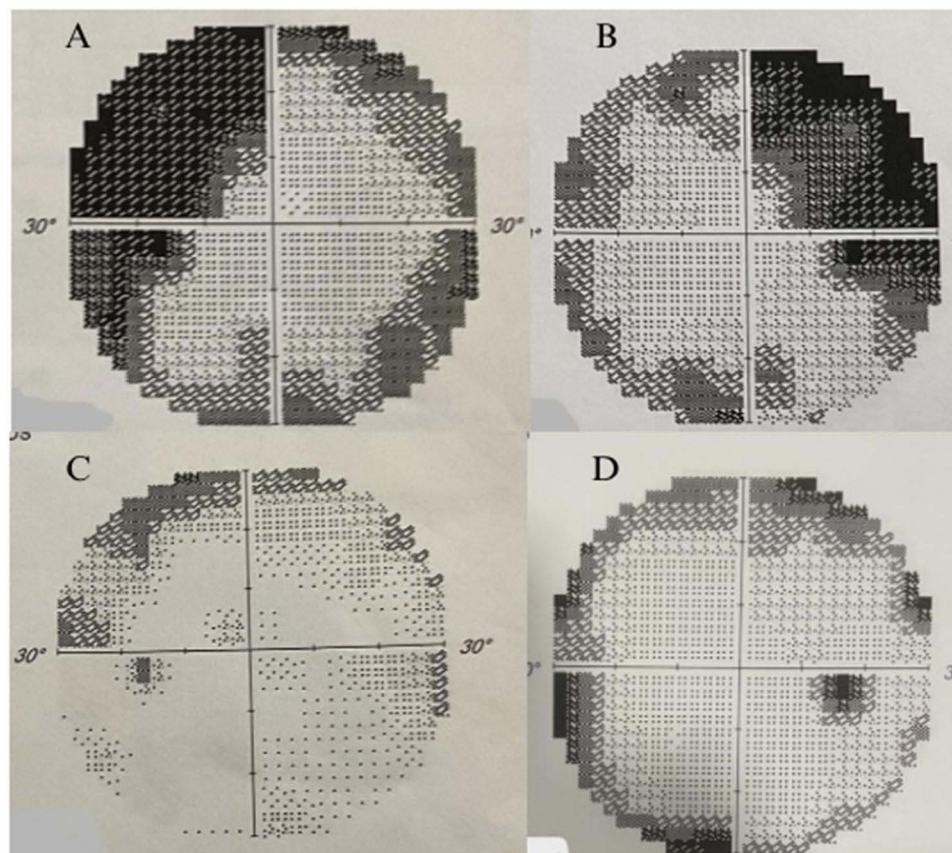
Nonfunctional tumours account for approximately 25% of all PitNETs, and 68.8% of giant pituitary adenomas are clinically non-functioning. Hence, Giant Clinically Non-Functioning Pituitary Adenomas (GCNFPAs) are also termed as ‘silent adenomas’, owing to their absence of demonstratable endocrine symptoms despite frequent immunohistochemical expression of anterior pituitary hormones in tumour cells.<sup>4</sup> Null cell adenomas are an immunohistochemical diagnosis of PitNETs that present as nonfunctioning sellar masses while yielding negative major immunoreactivity to any of the classic anterior pituitary hormones and account for 12.4%.<sup>7</sup>

We describe an unusual case in which a patient with a non-functioning giant pituitary macroadenoma presented with new-onset generalized motor tonic clonic (GTC) seizures. We describe our own clinical experience from the index case and from the literature regarding the surgical management of giant pituitary macroadenomas.

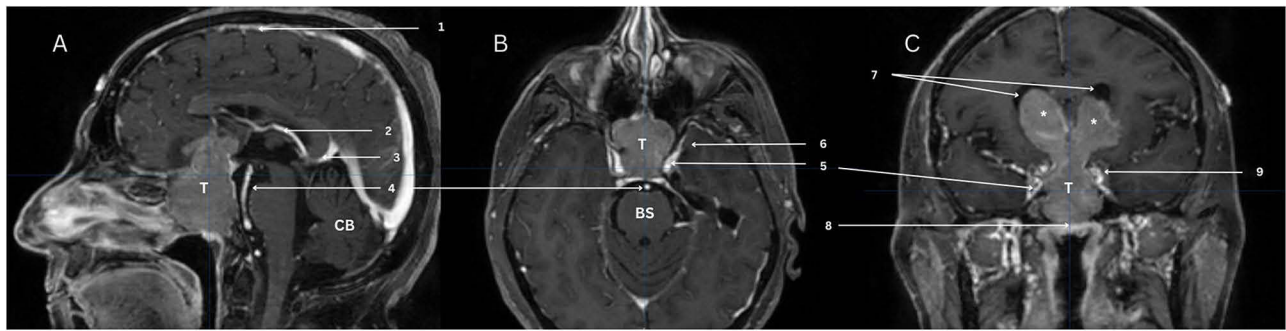
## Case Report

A 63-year-old female with poorly controlled diabetes mellitus, hypertension and dyslipidemia on oral medication presented with 3 episodes of back-to-back GTC seizures, each lasting for approximately 5 minutes, in a background of mild on-and-off headache for several months but without any weight gain, visual impairment or features of pituitary hormonal abnormalities. The seizures were associated with loss of consciousness, frothing, eye deviation and tonic and clonic movements of all four limbs followed by postictal drowsiness lasting for 2 to 3 hours. She was admitted to the A&E department and thereafter transferred to the intensive care unit, where she was managed with Levetiracetam to which she responded.

The neurological examination was unremarkable except for a bitemporal quadrantanopia on the visual field assessment. Moreover, the rest of the physical exam did not elicit any features of pituitary hormonal excess or deficiency. The patient was further assessed by a consultant ophthalmologist, where bitemporal pallor and cupping in addition to bitemporal upper quadrantanopia were detected. (Figure 1A and B)



**Figure 1** Grayscale maps of Humphrey's Visual Field Tests conducted prior to surgery (A – Left, B - right), three months after surgery (C – Left, D - Right).



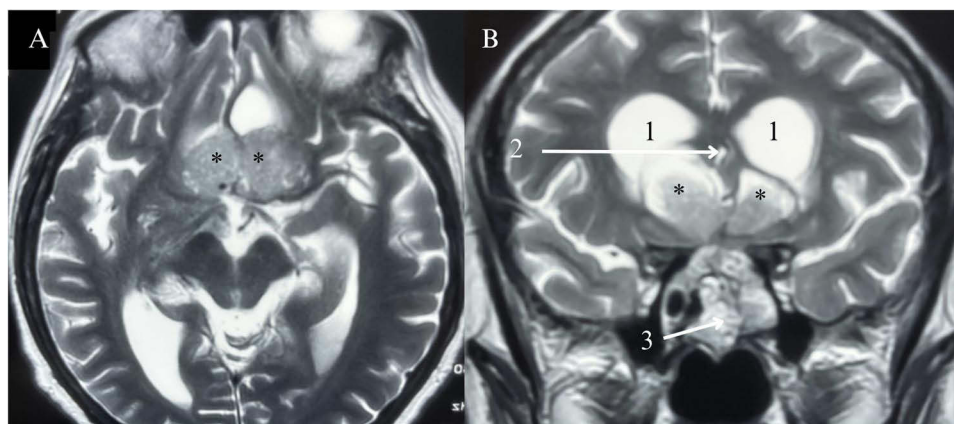
**Figure 2** (A) Sagittal (B) Axial (C) Coronal; Neuro-Navigation Guided Magnetic Resonance Images depicting the large pituitary tumour with suprasellar extension through the third ventricle into both lateral ventricles causing significant mass effect and impending hydrocephalus (volume of 36.081 cm<sup>3</sup>). T: Tumour; CB: Cerebellum; BS: Brainstem; 1: Superior sagittal sinus; 2: Internal cerebral vein; 3: Vein of Galen; 4: Basilar artery; 5: Internal carotid arteries; 6: Left medial temporal lobe; 7: Lateral ventricles; 8: Floor of the sella turcica largely obliterated by the tumour extending into the sphenoid sinus; 9: Left cavernous sinus.

Magnetic resonance imaging was subsequently used to detect a large pituitary tumour measuring 6.0 cm (craniocaudal) × 3.8 cm (transverse) × 4.0 cm (anteroposterior) with suprasellar extension through the third ventricle into both lateral ventricles, causing significant mass effects and impending hydrocephalus (Wilson-Hardy classification: IVC, Knosp classification: 0; Goel classification: IV) (Figure 2). Blood investigations that were also carried out revealed normal serum electrolytes and endocrine panels. (Table 1)

Upon stabilizing her and achieving significant glycemic and blood pressure control under the supervision of a consultant endocrinologist, she underwent neuro-navigation-guided endonasal transsphenoidal subtotal resection 2 weeks after her initial presentation. Histology revealed a null cell adenoma with a Ki-67 index of 3%. She was discharged one week after surgery, and at 3 months of follow-up, she was initiated on adjuvant radiotherapy but was well and seizure free (while on Levetiracetam) without any visual deficits. (Figure 1C and D, Figure 3) She is being closely followed up by the endocrinology team headed by a senior consultant endocrinologist and has not shown to have clinical or biochemical indicators of pituitary dysfunction. Close monitoring by MRI imaging will be performed at 3

**Table 1** Endocrine and Electrolyte Panel at Presentation

Laboratory Marker	Value	Reference Range
TSH (3rd Generation)	0.432	0.270–4.20 $\mu$ IU/mL
fT4	1.00	0.93–1.70 ng/dl
FSH	8.0	2.5–10.2 mIU/mL
LH	6.1	1.7–8.6 mIU/mL
Cortisol	13.46	5.00–25.00 $\mu$ g/dl
Prolactin	15.60	10.6 (median) 4.79–23.3 (percentile 5th–95th)
Sodium	137	135–146 mmol/L
Potassium	3.94	3.50–5.1 mmol/L
Chloride	102	101–109 mmol/L
Glucose (Fasting)	111.8	70.0–99.0 mg/dl
Calcium	10.1	8.8–10.2 mg/dl
Magnesium	1.9	1.8–2.4 mg/dl



**Figure 3** (A) Axial; (B) Coronal; T2 Magnetic Resonance Images depicting the residual tumour (<60%) at 3 months of follow-up from the subtotal resection via the endonasal transsphenoidal approach prior to initiation of radiotherapy. \*: Residual tumour in the lateral ventricles; 1: Lateral ventricles; 2: Third ventricle; 3: Fat graft placed during the transsphenoidal approach into the tumour.

months of completion of radiotherapy and at regular intervals thereafter to assess the growth of the residual tumour for a total cumulative period of 15 years (as per unit protocols).

## Discussion

The absence of typical clinical syndromes associated with tumour hormone hypersecretion in GCNFPA results in significant growth over periods of time, eventually leading to delayed presentations secondary to compression of neighbouring structures. While visual impairments and visual field defects (72%), followed by headache (13%), are the commonest preoperative presentations of these entities, seizures, particularly of the generalized tonic clonic type, are extremely rare and limited to a handful of case reports.<sup>3,6,8–12</sup> (Table 2) Convulsions are hypothesized to occur when the tumour invades the suprasellar area and/or the nervous system, specifically the frontal and temporal lobes, generating an epileptogenic focus.<sup>4</sup>

However, it is important to note that seizures are increasingly common in patients with prolactinomas, specifically those treated with dopamine agonists such as cabergoline and bromocriptine, as discussed in depth through multiple case studies and case series.<sup>9,13,14</sup> This is speculated to be due to the intratumoural hemorrhage that occurs during the medical treatment of prolactinomas, hence acting as an instigator for seizure development, as supported by MRI evidence of hemosiderin deposition in the medial temporal lobes of those patients.<sup>6</sup>

Nevertheless, the index case of GTC seizures from a GCNFPA histologically diagnosed as a null cell adenoma is unique both in its clinical presentation and the surgical management employed in its resection. Presentations of seizures much less seizures as the only complaint in non-functioning PitNETs are observed in a very limited number of case reports.<sup>3,6,12</sup> Out of them all, a case report by Vakharia et al,<sup>3</sup> is closely related to the index case, which describes a 40-year-old man presenting with new-onset generalized seizures to be investigated and diagnosed with a trilobed GCNFPA. Moreover, immunohistochemical findings of the previous case support the involvement of prolactin-producing tumour cells in the pathogenesis of this disease, providing direction for further research on this topic.<sup>8,11</sup> It is important to consider the mass effect of anterior suprasellar extensions of the symmetrically trilobed GCNFPA in that particular case report as the prime suspect for the generation of an epileptogenic focus, which is similar to speculation in the index case.

The radiological characteristics of the index patient were also rather interesting because of the significant sellar and suprasellar extensions of the tumour, accounting for a Hardy-Wilson Class IV C tumour with no parasellar extension but gross displacement of the third ventricle. This finding differed from a tumour described by Vakharia et al, which satisfied Hardy-Wilson Class IV D with parasellar intracranial intradural extensions in addition to diffuse destruction of the sella floor without details of the Knosp or Goel gradings.<sup>3</sup> The lesion in this case fulfils the second of the two preoperative MRI types of intraventricular extensions laid down by Jamaluddin et al, where it directly invades and disrupts the diaphragm to directly fill the third ventricle to give the impression of a “Hora seed” (*Dipterocarpus zeylanicus*) endemic

**Table 2** Summary of a Literature Review on Patients Harboring PitNETs Presenting with Seizures

Reference	Age*/Gender	Presentation	Preop Endocrine	MRI	Histology	Postop Endocrine	Follow-up
Vakharia et al <sup>3</sup>	40/M	Sudden onset seizures/behavioural changes	Normal	Trilobed pituitary tumour	Prolactin releasing tumour (ki 67: <5%)	Panhypopituitarism at postop day 6 managed medically	Discharged at postop day 16
Aini et al <sup>10</sup>	55/F	GTC x 1 episode/intermittent right nasal blockage and nasal symptoms x 3 months	Cort – 811 (118.6–618 nmol/L)	Modified Hardy Type E with extension to nasal cavity	Patient declined surgery. Managed with anticonvulsants. Died at 11 months of follow-up		
Hong et al <sup>6</sup>	54/M	GTC x 1 episode/episodic metallic taste x 10 months	Normal	Tumour extending to cavernous sinus and medial temporal lobe	Non-functioning pituitary adenoma (ki 67: <2%)	N/S	Follow-up MRI (6 month) shows residual tumour/12 months seizure free on treatment
Jamaluddin et al <sup>12</sup>	51/M	Headache/visual loss/ataxia/seizures	Normal	Knosp grade 3 pituitary lesion	Gonadotroph secreting tumor (ki 67: 3–4%)	N/S	Follow-up for 29 months – Left cavernous sinus tumour residue
Papanastasiou et al <sup>9</sup>	42/M	GTC x 1 episode/decreased consciousness/visual loss/headache, erectile dysfunction, loss of libido x 6 years	PRL:2000 (3.46 –19.4 ng/mL) and multiple AP hormone deficiency	60x35 mm with mass effect	Lactotroph Pituitary Adenoma (ki 67: 1%)	PRL reduced to 90.7 ng/mL following DA (CAB)	Initial CAB followed by surgery due to worsening visual impairment from chiasmal herniation. Seizure free (follow-up period N/S)
Deepak et al <sup>11</sup>	33/M	GTC/oral automatism	PRL: 28,000 ng/mL	Suprasellar mass reaching third ventricle	Lactotroph Pituitary Adenoma (ki 67: N/S)	PRL reduced to 5239 ng/mL after 6 months of CAB	CAB, AED and TSS. Seizure free postoperatively
Chentli et al <sup>8</sup>	8 patients Median Age: 33.75	GTC/headache/visual loss/reduced libido	Average PRL: 9198 ng/mL	Median tumour height: 74 mm (41–110)	-	7 prolactinomas and 1 somatolactotroph adenoma. Managed medically. Seizure free; follow-up period 1–20 years	

**Notes:** \*All ages are presented in years.

**Abbreviations:** M, Male; F, Female; AED, Antiepileptic Drugs; AP, Anterior Pituitary; Cort, Cortisol; CAB, Cabergoline; DA, Dopamine Antagonist; GTC, Generalized Tonic-Clonic Seizure; N/S, Not Specified; PRL, Prolactin; TSS, Transphenoidal Surgery.



to Sri Lanka with the seed in the sella and the two wing-like leaves directly extending and filling the third ventricle into the lateral ventricles, causing obstruction and impending hydrocephalus.

From a surgical perspective, GCNFPA with extensive suprasellar extensions pose a significant surgical challenge, and there is ongoing debate as to whether to perform transcranial, endonasal, combined or two-stage resection.<sup>5,15</sup> In the present case, the classical endonasal approach was able to achieve >60% resection of the tumour, as evidenced by the clinical resolution of symptoms and subsequent MRI findings. This was made in consensus with the requests of the patient and the direction of a multidisciplinary team, overriding the general recommendation to employ a combined endonasal-transcranial approach or the fronto-basal interhemispheric approach for suprasellar intraventricular extensions with the hope of achieving maximal debulking and symptom resolution via minimally invasive surgery.<sup>5</sup> This approach was different from that described by Vakharia et al, where a transcranial pterional approach was employed, which is valid because of the greater uniplanar extent of the lesion.<sup>3</sup>

We believe that maximum debulking via the endonasal approach with the intention of relieving mass effects on the surrounding critical neurological structures should always be prioritized in view of the multitude of complications associated with transcranial or combined approaches, especially with respect to increased risks of infection and delayed wound healing, particularly in patients with multiple medical comorbidities in addition to the trauma inflicted from prolonged retraction of the hemispheres. Furthermore, it is important to note that the transcranial approach may be especially unfavourable in the present case since separate resections in the two lateral ventricles may be required in addition to pituitary sellar debulking, imposing significant surgical risk. Hence, postoperative close follow-up with serial clinical and radiological assessments to ensure seizure freedom and residual tumour expansion in patients with subtotal or near total resections can potentially outweigh the surgical burden of transcranial, combined or two-staged approaches.

In conclusion, this unique case describes a patient with a GCNFPA of the null cell adenoma type who presented with isolated GTC seizures and discusses the clinical presentations and surgical strategies related to the existing scientific literature. Furthermore, it discusses the importance of the careful evaluation of clinical symptoms in managing PitNETs and how surgical strategies ought to be planned with priority towards symptom resolution, especially in large lesions where complete resection poses significant neurosurgical challenges. However, further large-scale studies are necessary to discuss about the advantages and long-standing complications associated with different surgical approaches in the management of PitNETs.

## Data Sharing Statement

All patient records, operation notes and radiographic information are available in the form of hardcopies. Scanned documents can be provided upon request from the journal.

## Consent to Participate

Written informed consent was obtained from the patient, and a scanned copy of the consent form can be provided upon request from the journal.

## Consent for Publication

All the authors unanimously agreed to provide consent to publish this paper in the journal. Written informed consent was obtained from the patient for publication of this case report and any accompanying images. A copy of the written consent is available for review by the Editor-in-Chief of this journal.

## Author Contributions

All authors made a significant contribution to the work reported, whether that is in the conception, study design, execution, acquisition of data, analysis and interpretation, or in all these areas; took part in drafting, revising or critically reviewing the article; gave final approval of the version to be published; have agreed on the journal to which the article has been submitted; and agree to be accountable for all aspects of the work.

## Funding

There is no funding to report.

## Disclosure

The authors report no conflicts of interest in this work.

## References

1. Asa SL, Mete O, Perry A, Osamura RY. Overview of the 2022 WHO classification of pituitary tumors. *Endocrine Pathol.* 2022;33(1):6–26. doi:10.1007/s12022-022-09703-7
2. Chen C, Hu Y, Lyu L, et al. Incidence, demographics, and survival of patients with primary pituitary tumors: a SEER database study in 2004–2016. *Sci Rep.* 2021;11(1):1–9. doi:10.1038/s41598-021-94658-8
3. Vakharia RM, Kremen R, Vakharia A, Adarkwah O, Anderson G. Anterior and posterior suprasellar extensions of a symmetrical trilobed nonfunctional giant pituitary adenoma in the sagittal plane: a case report and review of literature. *Radiol Case Rep.* 2016;11(4):419–424. doi:10.1016/j.rader.2016.09.001
4. Iglesias P, Rodríguez Berrocal V, Díez JJ. Giant pituitary adenoma: histological types, clinical features and therapeutic approaches. *Endocrine.* 2018;61(3):407–421. doi:10.1007/s12020-018-1645-x
5. Han S, Gao W, Jing Z, Wang Y, Wu A. How to deal with giant pituitary adenomas: transsphenoidal or transcranial, simultaneous or two-staged? *J Neuro Oncol.* 2017;132(2):313–321. doi:10.1007/s11060-017-2371-6
6. Hong CS, Gorrepati R, Kundishora AJ, et al. Case report: suprasellar pituitary adenoma presenting with temporal lobe seizures. *Front Surg.* 2020;7(December):1–5. doi:10.3389/fsurg.2020.598138
7. Balogun JA, Monsalves E, Juraschka K, et al. Null Cell Adenomas of the Pituitary Gland: an Institutional Review of Their Clinical Imaging and Behavioral Characteristics. *Endocrine Pathol.* 2015;26(1):63–70. doi:10.1007/s12022-014-9347-2
8. Chentli F, Akkache L, Daffeur K, Azzoug S. General seizures revealing macro-adenomas secreting prolactin or prolactin and growth hormone in men. *Indian J Endocrinol Metab.* 2014;18(3):361–363. doi:10.4103/2230-8210.131185
9. Papanastasiou L, Fountoulakis S, Pappa T, et al. Brain and optic chiasmal herniation following cabergoline treatment for a giant prolactinoma: wait or intervene? *Hormones.* 2014;13(2):290–295. doi:10.1007/bf03401344
10. Aini R, Sachlin IS, Chee LC, Abdullah B. A unilateral nasal mass with generalized seizures: potential diagnostic pitfalls in giant pituitary adenoma. *Allergy Rhinol.* 2019;10:215265671989658. doi:10.1177/2152656719896580
11. Deepak D, Daousi C, Javadpour M, MacFarlane IA. Macroprolactinomas and epilepsy. *Clin Endocrinol.* 2007;66(4):503–507. doi:10.1111/j.1365-2265.2007.02759.x
12. Jamaluddin MA, Patel BK, George T, et al. Endoscopic endonasal approach for giant pituitary adenoma occupying the entire third ventricle: surgical results and a review of the literature. *World Neurosurg.* 2021;154:e254–e263. doi:10.1016/j.wneu.2021.07.022
13. Dhanwal DK, Sharma AK. Brain and optic chiasmal herniations into sella after cabergoline therapy of giant prolactinoma. *Pituitary.* 2011;14(4):384–387. doi:10.1007/s11102-009-0179-x
14. Koguchi M, Nakahara Y, Ebashi R, et al. Status epilepticus induced by treatment with dopamine agonist therapy for giant prolactinoma: a case report. *J Med Case Rep.* 2019;13(1):18. doi:10.1186/s13256-018-1939-x
15. Plou P, Seriola S, Leonel LCPC, et al. Surgical anatomy and approaches of the anterior cranial fossa from a transcranial and endonasal perspective. *Cancers.* 2023;15(9):1–13. doi:10.3390/cancers15092587

International Medical Case Reports Journal

Dovepress

Publish your work in this journal

The International Medical Case Reports Journal is an international, peer-reviewed open-access journal publishing original case reports from all medical specialties. Previously unpublished medical posters are also accepted relating to any area of clinical or preclinical science. Submissions should not normally exceed 2,000 words or 4 published pages including figures, diagrams and references. The manuscript management system is completely online and includes a very quick and fair peer-review system, which is all easy to use. Visit <http://www.dovepress.com/testimonials.php> to read real quotes from published authors.

Submit your manuscript here: <https://www.dovepress.com/international-medical-case-reports-journal-journal>