

Complications of post-cochlear implantation in 1027 adults and children

Roa Halawani, Ahmad Aldhafeeri, Sulumain Alajlan, Farid Alzhrani

King Abdullah Ear Specialist Center (KAESC), College of Medicine, King Saud University, Riyadh, Saudi Arabia

Correspondence: Dr. Roa Halawani · King Abdullah Ear Specialist Center (KAESC), College of Medicine, King Saud University, Riyadh, Saudi Arabia PO Box 245 Riyadh 11411, Saudi Arabia · T: +966 1 477 5735 · Roa_halawani@yahoo.com · ORCID: <https://orcid.org/0000-0002-4804-4286>

Citation: Halawani R, Alzhrani F, Aldhafeeri A, Alajlan S. Complications of post-cochlear implantation in 1027 adults and children. *Ann Saudi Med* 39(2): 77-81 DOI: 10.5144/0256-4947.2019.77

Received: December 18, 2018

Accepted: March 5, 2019

Published: April 4, 2019

Copyright: Copyright © 2019, Annals of Saudi Medicine, Saudi Arabia. This is an open access article under the Creative Commons Attribution-NonCommercial-NoDerivatives 4.0 International License (CC BY-NC-ND). The details of which can be accessed at <http://creativecommons.org/licenses/by-nc-nd/4.0/>

Funding: None.

BACKGROUND: The number of cochlear implant (CI) recipients is increasing so there needs to be greater awareness of possible CI complications.

OBJECTIVES: Describe complications of CI.

DESIGN: Retrospective, descriptive.

SETTINGS: Tertiary health care center.

PATIENTS AND METHODS: Data was collected by retrospective chart review on complications for recipients implanted for the period from January 2006 to June 2017.

MAIN OUTCOME MEASURES: Major and minor post cochlear implantation complications.

SAMPLE SIZE: 1027 cochlear implant recipients.

RESULTS: Post-operative complications were reported in 105 patients (10.2%). Minor complications were most often encountered (9.5%). Swelling (wound seroma or hematoma) was the most common complication. The major complication rate was only 7/105, 0.7%. Meningitis did not occur and cholesteatoma occurred in only one patient.

CONCLUSION: CI is a safe surgical procedure at our center. We believe that this is probably due to the preoperative protocol, the surgical technique used, and the postoperative care conducted for all our patients. Despite this, it is important that both physicians and patients have knowledge of the possible consequences and risks posed by CI, especially in view of the fact that these patients require lifetime follow-up.

LIMITATIONS: Further studies are needed, and should include more ENT centers across all regions of Saudi Arabia.

CONFLICT OF INTEREST: None.

Cochlear Implantation (CI) is useful for treating profound hearing loss in patients who do not benefit sufficiently from the use of hearing aids. The numbers of CI recipients is increasing substantially, so patients and physicians need to be aware of the CI complications for both patients and healthcare practitioners.¹⁻⁵ Complications post-CI can be classified as 'major' (as in the case of wound flap necrosis, implant extrusion, electrode misplacement, meningitis, magnet displacement) or 'minor' (as in the case of damage to the chorda tympani nerve, postoperative facial paresis/palsy, acute otitis media, intraoperative bleeding, postoperative pain, facial nerve stimulation, dizziness, and others). Classification as major or minor is based on the need for additional surgery or outpatient procedures.⁶

CI complications can be categorized as intraoperative, early postoperative (≤ 3 months post implantation) and late postoperative (> 3 months post implantation). Early postoperative complications are wound infection, skin necrosis, facial paralysis, seroma, vertigo, meningitis and tinnitus. One of the potentially critical complications of CI is meningitis and precautions should be taken in all cases, especially if a cerebrospinal gusher occurs after opening the cochlea.⁷ Late postoperative complications include failure of the device, facial nerve twitching on stimulation and chronic ear infection with or without cholesteatoma.

Our center is considered one of the biggest referral centers in Saudi Arabia and has the largest series of cochlear implant surgeries in the country. To the best of our knowledge, only one similar study has been carried out in Saudi Arabia, which was published in 2009.⁸ Because a decade has passed, we decided to perform this study. Our objective was to review and summarize the precise data on CI surgery complications at our institute.

PATIENTS AND METHODS

We retrospectively reviewed the charts of all subjects who underwent cochlear implantation at our center between January 2006 and June 2017. All patients who had follow-up for at least one-year postimplantation were included in the study. All operations were performed by three senior surgeons using the transmastoid approach. The middle ear was opened through posterior tympanotomy. All complications were classified as either 'major' or 'minor' depending on the extent of management required.^{5,9-11} Additionally, complications were also categorized based on the time of onset. The study was approved by our University IRB board.

'Device failure' has been cited as a potential post CI-implantation complication.^{1,2,4} However, we excluded

this from our study as this problem is not associated with surgery.⁸ Twenty-eight cases of device failure were excluded from this report. All those cases have documented nonsurgical-related software malfunctioning device failure.

RESULTS

Of 1027 cases retrospectively evaluated for post-implant complications, the majority of the study population were children ($n=892$, 86.9%) aged younger than 18 years when they received their cochlear implant. All patients followed up in the outpatient clinics for an average duration was 42 months (range: 12–82 months). The most common etiology for hearing loss was non-syndromic, congenital sensorineural hearing loss. Other indications included trauma, meningitis, ear infection, autoimmune condition, sickle cell anemia, and post radiotherapy hearing loss.

The overall rate of complications in the studied subjects was 10.2% ($n=105$), of which 98 cases (9.5%) had minor complications; only seven cases (0.7%) had major complications. The most common complications were seroma/hematoma ($n=22$, 21% of complications) followed by pain (13.2%), wound infections (11.4%), and vertigo (9.5%) (**Figure 1**). The onset of complications was intraoperative in 3% of subjects, while a majority of patients had early postoperative complications ($n=75$, 71%). Late postoperative complications were observed in 26% of subjects. One case, a 9-month-old, had severe intraoperative bleeding and needed transfusion of two units of packed red blood cells. Two cases of tympanic membrane perforation were repaired in the same setting. All flap complications were managed with local wound care; however, in four patients there was flap necrosis (3.8%) that required surgical intervention.

In the present study, five cases (4.8%) of facial weakness were observed. Four of these patients suffered a delayed onset injury. Palsy was transient, and they recovered completely within a few weeks after treatment with corticosteroids. However, in one case of immediate onset injury the damage was permanent in a child who had inner ear malformation. Eight cases (6%) of postoperative oozing blood, postoperative ear pain ($n=14$, 13.1%), and transient vertigo ($n=10$, 9.5%) were also noted. Most of these symptoms were completely resolved within a couple of days. Examples of the late postoperative complications that presented were facial nerve stimulation ($n=6$, 6.6%), troublesome scalp numbness ($n=5$, 4.7%), taste disturbances ($n=4$, 3.8%), and tinnitus ($n=3$, 2.8%). Otitis media, a common condition in the pediatric age group, was reported in only 8 of the subjects (7.6%). Unfortunately, two of them de-

veloped coalescent mastoiditis (2%) and needed surgical intervention. One case did not show for follow up and presented later with cholesteatoma (0.95%).

DISCUSSION

The surgical procedure for cochlear implantation has undergone various modifications over the past years, with changes mostly directed towards the prevention of surgical and medical complications. Like any other surgical intervention, complications that are associated with CI involve variables that are intrinsically associated with the patient (such as anatomic variations, inner ear abnormalities). These complications reflect the complexity of the procedure and are also dependent on the surgeons' skills and experience. Thus, proper patient selection as well as care with anesthesia and surgical techniques should be considered.^{5,9,12} In our series, the overall rate of complication was 10.2%, which is lower than that found in previous studies (18.3% and 11.8% excluding device failures).⁵⁻⁶ However, if we include 28 cases of device failure as a major complication, this rate becomes (13%). In a similar study was carried out in Saudi Arabia by Al-Muhaimeed et al,⁸ which included 117 patients, the complication rate in their series was 16.2%.

Several anatomically distinctive features in children less than one year old make them at greater risk of bleeding intraoperatively. The two steps in the CI procedure where most surgeons report having more bleeding is while elevating the periosteum from the mastoid bone and at the time of mastoidectomy drilling, due to bone marrow bleeding. In the event of increased bleeding, infants at this age are prone to rapid cardiovascular decompensation, so cochlear implantation in these children should carefully planned.

Although facial nerve injury has become less frequent over the years, damage to the facial nerve may happen.^{9,13} The previous studies reported a rate of facial palsy following cochlear implantation of 0.42 to 1.2 %, which is comparable to the rate in the present study (5/1207, 0.5%). Hoffman et al mentioned that almost 16% of inner ear anomalies could be associated with abnormal facial nerve course.¹⁴ The delayed onset of facial nerve palsy could be due to inflammation either in the nerve or the tissue around it, or to direct pressure on the nerve from the electrode. It could also be caused by infection, or reactivation of herpes viruses and is unlikely caused by surgery-induced edema, which would present earlier.¹³

While postauricular swelling was a common complication in our study, fluid accumulation at the implant site could be edema, seroma or hematoma. Postauricular

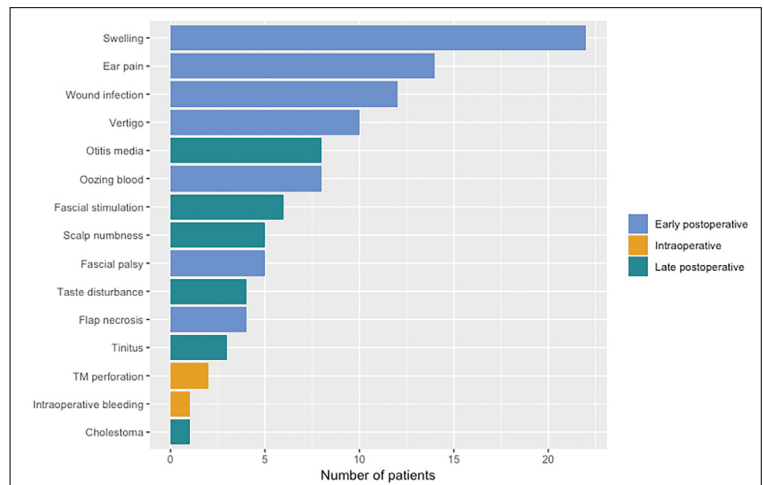


Figure 1. Complications in 1027 patients who underwent cochlear implantation. TM: tympanic membrane

hematoma, especially at the receiver site, was commonly encountered in our study. This complication usually occurred 1 to 2 days after surgery. If hematoma does not respond to a pressure dressing, aspiration may be indicated. The incidence of postoperative hematoma ranges from 0.4% to 3.7%.⁹ However, we noticed a decline in postoperative hematoma recently, which might be due to a change to the tight pocket technique by all our surgeons while elevating the periosteum. The tight pocket technique not only decreases the space but also produces less bleeding by minimizing the area of the periosteum lifted.

Surgical site infection is one of the complications that worries the cochlear implant team. According to the literature, the incidence of infection ranges from 1.7. to 16.6%.⁵ In our study, 1.2% of the overall rate of infection was related to flap problems. The majority of the other complications were managed with local wound care. Unfortunately, four cases of infection refractory to medical treatment subsequently led to flap necrosis. Debridement and primary closure were performed for the treatment of partial necrosis and wound dehiscence.

Even though otitis media is very common in children, only 8 cases (0.8%) were found in this study. Of these, two cases developed coalescent mastoiditis which required surgical intervention; however, none of the cases required removal of the implanted device. Acute otitis media was managed using a standard regimen of antibiotics administered intravenously.¹⁵

Post-implantation facial nerve stimulation is a rare complication. The electric current produced by the CI electrode in the cochlea may pass to the adjacent facial

nerve causing stimulation.¹⁶ Moreover, the onset of facial nerve stimulation can be immediate or delayed. It has been reported that otosclerosis and cochlear nerve hypoplasia patients are at greater risk of facial nerve stimulation after implantation.¹⁷ In the current study group, six patients experienced facial nerve stimulation, which was managed by minimal changes to their fitting maps.

In the current study, the sort of minor complications that were encountered included immediate postauricular pain and transient vertigo. While the former condition can be controlled by analgesia and reassurance, immediate vertigo most likely is self-limiting because of compensation by the vestibular system. Kubo et al reported vertigo after CI at a higher incidence of 12.4%.¹⁸ Taste disturbances are one of the most frequent complications of CI because of the apparent risk of damage to the chorda tympani nerve during surgery, especially during posterior tympanotomy.¹⁹ Postoperative taste dysfunction has been observed in several different studies at varied frequencies: 25% according to Mueller et al,²⁰ from 5–15% according to Wagner et al¹⁹ and 7.7% according to Al-Zahrani et al.²¹ In the current study, only four adult patients (3.8%) complained of taste disturbances, and had complete recovery within two months. The lower incidence observed here could be because a majority of our cases were children who may not be able to elicit disturbances in taste as subtly as adults.

During the drilling of the posterior tympanotomy, iatrogenic injury to the external auditory canal occurred in two subjects. The defects were repaired immediately with conchal cartilage. This occurrence emphasizes the need for a clinical follow up spanning a longer duration of time, especially in cases where the canal wall has been broken and/or injury to the tympanic annulus has occurred because such patients may develop chronic otitis media with cholesteatoma. However, cholesteatomas also affect patients without intraoperative injuries. In fact, the reported prevalence of cholesteatomas as a major complication ranges from 4.8 to 12.2%.^{16,17,22} Primary acquired cholesteatoma can occur in any child with a cochlear implant and is a distinct possibility. Interestingly, Lin et al suggest that CI may predispose to secondary acquired cholesteatoma by interfering with the normal process of middle ear pneumatization or by inducing mucosal changes by acting

as a foreign body or a nidus of infection.²³ There is evidence that biofilm formation on the cochlear implant can also result in chronic otitis media.²⁴ Several suggestions have been proffered as a means of reducing the surgical risk of cholesteatoma; these include the avoidance of damage to the posterior canal wall and perioperative antibiotic cover. However, the key to prevent failure of the implant due to cholesteatoma lies in early diagnosis and intervention. Only one case of cholesteatoma was observed in the current study, and this was managed by subtotal petrosectomy with blind sac closure and device explanation.

Because meningitis is a potentially serious complication after CI surgery, and may be fatal in some cases, the FDA recommends use of prophylactic antibiotics preoperatively.²⁴ This recommendation will decrease the risk of both meningitis and wound infection. Vaccination with pneumococcal conjugate vaccine (PCV13) and Haemophilus influenzae type B (Hib) should be given prior to implantation, especially in cases of inner ear anomalies with the aim of reducing the incidence of meningitis. We had no cases of meningitis during the current study; however, as all the children had been vaccinated against *Streptococcus pneumoniae* as well as *Haemophilus influenzae* type B, and had been given perioperative injectable cefuroxime.²⁵

This study provides an overview of the incidence of various major and minor complications after cochlear implantation in a large sample of CI-implanted patients in Saudi Arabia. However, it is merely a single center study, which limits its generalizability. Hence, further studies are needed, and should include more ENT centers across all the regions of Saudi Arabia in order to obtain a better understanding of post CI-complications and their therapeutic management. Continued monitoring over a longer follow-up time for all patients is recommended as well as early intervention if problems are detected in the immediate period after surgery. Finally, appropriate measures should be implemented to prevent unnecessary complications. It is essential for both the physician and patient to be oriented toward anticipated complications, emphasizing the necessity of lifelong follow-up. This study can provide a basis for further research on the topic in Saudi Arabia, and thereby contribute to the discovery of effective preventive measures for post-cochlear implantation complications.

REFERENCES

1. Arnoldner C, Baumgartner W, Gstoettner W, Hamzavi J. Surgical considerations in cochlear implantation in children and adults: a review of 342 cases in Vienna. *Acta Otolaryngol* . 2005;125(3): 228–234 .
2. Beadle EA, McKinley DJ, Nikolopoulos TP, Brough J, O'Donoghue GM, Archbold SM. Long-term functional outcomes and academic-occupational status in implanted children after 10–14 years of cochlear implant use. *Otol Neurotol*. 2005;26(6): 1152–1160 .
3. Black IM, Bailey C, Albert Detal. The Great Ormond Street Hospital paediatric cochlear implant programme 1992–2004: a review of surgical complications. *Cochlear Implants Int*. 2007;8(2): 53–67
4. Lässig AA, Zwolan TA, Telian SA . Cochlear implant failures and revision. *Otol Neurotol* . 2005;26(4):624–634 .
5. Venail F, Sicard M, Piron JP, et al. Reliability and complications of 500 consecutive cochlear implantations. *Arch Otolaryngol Head Neck Surg* . 2008;134:1276–81.
6. Cohen NL, Hoffman RA, Stroschein M. Medical or surgical complications related to the Nucleus multichannel cochlear implant. *Ann Otol Rhinol Laryngol Suppl*. 1988;97(suppl 135):8-13.
7. Raghunandhan S, Kameswaran M, Anand Kumar RS, Agarwal AK, Hossain MD. A study of complications and morbidity profile in cochlear implantation: the MERF experience. *Indian J Otolaryngol Head Neck Surg*. 2014;66(1):161-168.
8. Al-Muhaimeed HS, Al-Anazy F, Attallah MS, Hamed O. Cochlear implantation at King Abdulaziz University Hospital, Riyadh, Saudi Arabia: a 12-year experience. *J Laryngol Otol*. 2009;123:e20.
9. Bhatia K, Gibbin KP, Nikolopoulos TP, et al. Surgical complications and their management in a series of 300 consecutive pediatric cochlear implantations. *Otol Neurotol*. 2004;25:730–9.
10. Farinetti A, Ben Gharbia D, Mancini J, et al. Cochlear implant complications in 403 patients: Comparative study of adults and children and review of the literature. *Eur Ann Otorhinolaryngol Head Neck Dis*. 2014;131:177–82.
11. Wang JT, Wang AY, Psarros C, et al. Rates of revision and device failure in cochlear implant surgery: a 30-year experience *Laryngoscope*. 2014;124(10):2393-9.
12. Roland JT . Complication of cochlear implant surgery. In: Waltzman SB, Cohen NL (eds) *Cochlear implants*. New York, NY: Thieme; 2000;171-175.
13. F Alzhrani, T Lenarz, M Teschner. Facial palsy following cochlear implantation. *European Archives of Oto-Rhino-Laryngology*. 2016;273 (12), 4199-4207.
14. Hoffman RA, Cohen NL (1995) Complications of cochlear implant surgery. *Ann Otol Rhinol Laryngol Suppl* 104:420–422
15. Ramos A, Charlone R, de Miguel I, Valdivielso A, Cuyas JM, Pe'rez D, Vasallo JR .Complications in cochlear implantation. *Acta Otorrinolaringol Esp*. 2006;57(3):122–125.
16. Kelsall DC, Shalloo JK, Brammeier TG, et al. Facial nerve stimulation after Nucleus 22-channel cochlear implantation. *Am J Otol*. 1997;18:336-41.
17. S. Berrettini, A. De Vito, L. Bruschini, S. Passetti, F. Forli *Acta Otorhinolaryngologica*. 2011;31:11-16.
18. Kubo T, Massuura S, Iwaki T .Complications of cochlear implant surgery. *Oper Tech Otolaryngol Head Neck Surg*. 2005;16:154–158.
19. Alzhrani F, Lenarz T, Teschner M .Taste sensation following cochlear implantation surgery. *Cochlear Implants Int*. 2013;14(4):200–206.
20. Mueller C.A., Khatib S., Temmel A.F.P., Baumgartner W.D. Hummel T. 2007. Effects of cochlear implantation on gustatory function. *Ann Otol Rhinol Laryngol*, 116: 498–501.
21. Wagner J.H., Basta D., Wagner F., Seidl R.O., Ernst A., Todt I. 2010. Vestibular and taste disorders after bilateral cochlear implantation. *European Archives of Otorhinolaryngology*, 267:1849–1854.
22. Brito R, Monteiro TA, Leal AF, Tsuji RK, Pinna MH, Bento RF. Surgical complications in 550 consecutive cochlear implantation. *Braz J Otorhinolaryngol*. 2012;78:80-5.
23. Lin YS. Management of otitis media-related diseases in children with a cochlear implant. *Acta Otolaryngol*. 2009;129:254–60.
24. Pawlowski KS, Wawro D, Roland PS. Bacterial biofilm formation on a human cochlear implant. *Otol Neurotol* . 2005;26:972–5.
25. F. Qin et al. After cochlear implantation: Complications related to flap around implants. *Journal of Otology* . 2016;198e201.