

Tetralogy of Fallot: A Surgical Perspective

Tom R. Karl, M.D.

Tetralogy of Fallot (TOF) is an index lesion for all paediatric and congenital heart surgeons. In designing an appropriate operation for children with TOF, the predicted postoperative physiology must be taken into account, both for the short and long term. A favourable balance between pulmonary stenosis (PS) and pulmonary insufficiency (PI) may be critical for preservation of biventricular function. A unified repair strategy to limit both residual PS and PI is presented, along with supportive experimental evidence. A strategy for dealing with coronary anomalies and some comments regarding best timing of operation are also included.

Key words: 1. Tetralogy of Fallot
2. Right ventricle
3. Pulmonary valve
4. Surgical repair

INTRODUCTION

Tetralogy of Fallot (TOF) is the first cyanotic cardiac lesion to have been formally described, and subsequently stimulate development of some of the first palliative and definitive cardiac operations. Lillehei's original TOF repairs (whether with cross circulation or cardiopulmonary bypass [CPB]) generally employed a large right ventricular (RV) incision for access to both the right ventricular outflow tract obstruction (RVOTO) and ventricular septal defect (VSD). Mortality for TOF repair in the 1950s approached 50%, but current risk has fallen to consistently less than 2%. The relatively favourable long term results have been noted in numerous studies, although some level of physical compromise is common in adults who have survived repair during childhood in an earlier era [1-4]. Because late mortality postoperative is rela-

tively uncommon in the first 3 or 4 decades, TOF is an excellent model for natural history studies of treated congenital heart disease (CHD). Moreover, TOF has played a central role in our understanding of morphology, molecular biology, myocardial protection, and inflammation as they relate to CHD.

TOF is potentially lethal if untreated. One, three, and ten year survival probabilities without surgery are approximately 66%, 49%, and 24%, even though there have been isolated case reports of natural survival into the 8th and 9th decade [5]. In a recent report from the Society of Thoracic Surgeons database, multi-institutional surgical mortality for TOF repair was noted to be 1.1% [6]. Furthermore there was minimal variability between the 74 reporting centers, with no outliers identified statistically [6]. Therefore the natural history has been effectively altered timely surgical intervention, even if a uniformly excellent result remains elusive.

Cardiac Surgical Unit, Mater Children's Hospital, Queensland Paediatric Cardiac Service

Received: May 18, 2012, Revised: June 11, 2012, Accepted: June 12, 2012

Corresponding author: Tom R. Karl, Paediatric Cardiac Surgery, Mater Children's Hospital, Queensland Paediatric Cardiac Service, Raymond Terrace, South Brisbane, QLD 4101, Australia

(Tel) 61-7-3163-7597 (Fax) 61-7-3163-5308 (E-mail) Trkarl.aus@gmail.com

© The Korean Society for Thoracic and Cardiovascular Surgery. 2012. All right reserved.

© This is an open access article distributed under the terms of the Creative Commons Attribution Non-Commercial License (<http://creativecommons.org/licenses/by-nc/3.0>) which permits unrestricted non-commercial use, distribution, and reproduction in any medium, provided the original work is properly cited.

The ideal TOF repair should be suitable for infants and children of all ages, and should provide good relief of RVOTO, complete atrial and ventricular septation, with avoidance of extensive ventriculotomy and of circulatory arrest. Preservation of pulmonary valve (PV) and tricuspid valve (TV) function and biventricular contractility is fundamental, along with minimal early mortality and morbidity. Since the immediate outcome of TOF repair is good employing diverse surgical strategies, our goals of treatment should include minimisation of long-term complications and a low probability of early and late reoperation. A good neurodevelopmental and functional status and quality of life could complete the expectations.

What is different today as compared to the Lillehei era? It has become evident that myocardial injury, coronary injury, RV dysfunction, and arrhythmias are all related in part to large RV incisions, especially in the context of transannular patching with free pulmonary insufficiency (PI). We may have a better understanding of some of the events leading to late RV failure, and perhaps the technical ability to improve the results for the next generation of children undergoing repair.

Historical thinking regarding post repair TOF physiology has emphasized two points. Firstly, postoperative RVOTO has been considered to be undesirable, to the point that some teams would consider revision of a repair in the setting of a right ventricle RV/left ventricular (LV) systolic pressure ratio >0.75 . The second "traditional" belief is that postoperative PI will be well tolerated in the longer term, and that only very significant RV dilation will be problematic. Both concepts have been challenged in recent years.

PI is exacerbated by loss of downstream compliance and lessened or prevented by proximal resistance. The degree of PI therefore depends in part on pulmonary artery (PA) compliance, and the location of resistance relative to a valveless RV-PA junction [7]. Free PI causes RV dilation that in turn affects the LV. The functional reserve and myocardial contractility of the RV and LV may decline with chronic PI. This phenomenon is detectable in experimental models as early as 3 months after the onset of PI [8]. Geva [9] noted that LV dysfunction often coexists with PI induced RV dysfunction/dilation. This is thought to be related to LV interaction

with the volume loaded RV, due to humoral factors, geometry, shared myofibres, and electromechanical (EM) dyssynchrony [9]. Such physiology may be well tolerated clinically for a long time, but some patients will eventually experience diminished exercise tolerance and progressive RV dilation and failure [10,11]. This in turn predisposes the patient to late life-threatening ventricular arrhythmias [10,12]. Severe RV dilation and related dysfunction, RV wall motion abnormalities, syncope, QRS duration >180 minutes, and sustained ventricular tachycardia all predict late heart failure and sudden death [9]. Schwartz et al. [13] noted a linear association between RV end diastolic volume index and LV end diastolic pressure in post operative TOF cases undergoing catheterisation. RV end diastolic pressure, PA pressure, and support time during repair were also important in predicting LV end diastolic pressure [13]. Liberalisation of indications for PV replacement is currently recommended in an attempt to avoid the aforementioned scenarios [14-19]. Not all patients will benefit, however, and the timing and exact indications are controversial. There is no consensus regarding the best tools for assessment, nor their relative importance in decision making regarding significance of PI. Tissue Doppler imaging of TV annular motion during dobutamine stress echocardiography, for example, is useful for estimating contractile reserve, which may be relevant for timing of PV revision [20]. Diastolic function may be as important as systolic function in decision making [21]. Magnetic resonance imaging (MRI), brain natriuretic peptide levels, QRS duration, presence of arrhythmia, anatomy of the RV, and other factors may all be useful [22-27].

Following TOF repair, residual/recurrent RVOTO is extremely common. The degree of RVOTO may be inversely proportional to the grade of PI. With an isolated RV pressure load, increases in cellular hypertrophy, microtubule density, and interstitial collagen formation may lead to decreased contractility over time. In a recent Korean publication, RV pressure load following TOF repair was found to protect to some extent against RV dilation from chronic PI, without inducing systolic dysfunction, although the limits of this phenomenon are not fully understood [28]. It is relevant that RV mass and mass/volume ratio are independently predictive of ventricular tachycardia and late death following TOF repair [29].

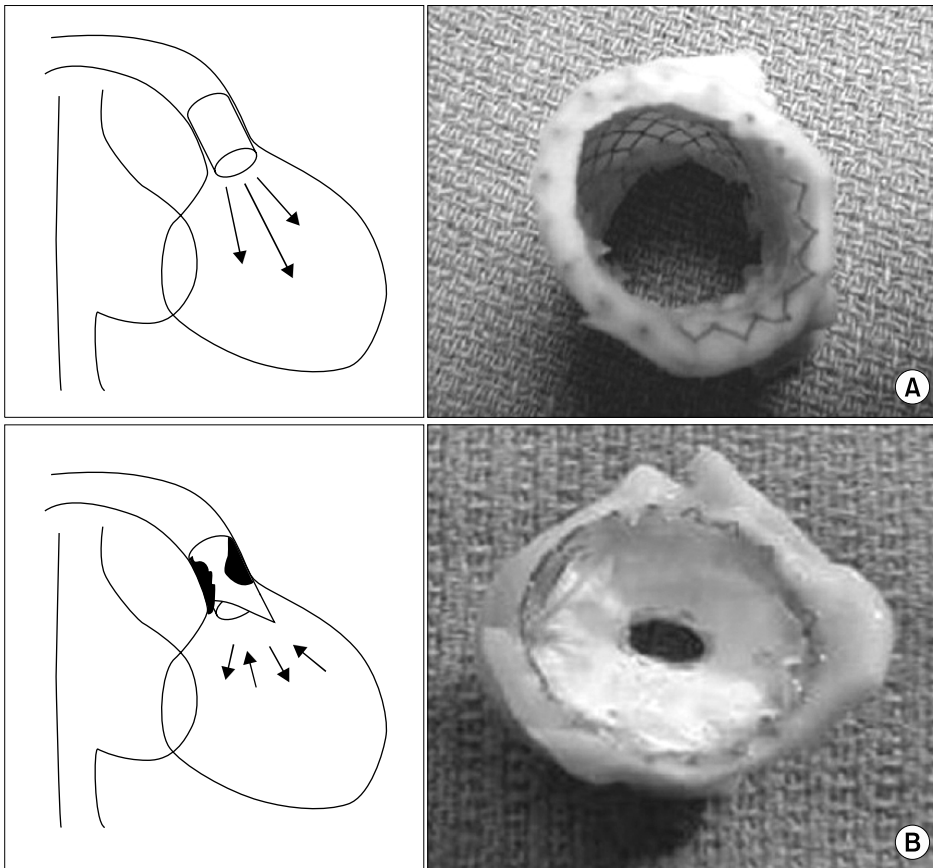


Fig. 1. Creation of a chronic porcine model of pulmonary insufficiency (PI) (A) and combined pulmonary stenosis/PI (B), achieved with percutaneous delivery of transannular stents (with and without a restrictive polytetrafluoroethylene diaphragm) into the right ventricular outflow tract obstruction (From Karl TR. *Ann Pediatr Card* 2008;1:93-100, with permission from *Annals of Pediatric Cardiology*) [31].

In balancing pulmonary stenosis (PS) and PI, it would therefore be useful in the clinical setting to know which is worse for the RV and LV over the long term: isolated PI or combined PS-PI. Should we try to limit PI by accepting more PS at the initial repair? Can we eliminate both problems using appropriate techniques?

EXPERIMENTAL EVIDENCE

University of California San Francisco investigators have created a non-surgical porcine model to assess the effects of chronic combined PS-PI on the RV and LV, looking at both anatomic and functional changes (Fig. 1) [30,31]. Growing pigs had transcatheter stents placed across the Right ventricular outflow tract (RVOT) and PV to induce PS-PI. Assessment was done within 2 days of intervention and 3 months later, looking at indices of systolic function (stroke volume, ejection fraction, and cardiac functional reserve), myocardial contractility (slope of the end-systolic pressure-volume

relationship, and change in pressure over time-end-diastolic volume relationship, and diastolic compliance. MRI was used to quantify PI and ventricular volumes. Conductance catheters were used to obtain indices of the cardiac functional reserve, diastolic compliance, and myocardial contractility from pressure-volume relations acquired at rest and under dobutamine infusion (Fig. 2) [31]. The data were compared with data from controls and animals with isolated PI [32]. After 3 months of PS-PI, indices of RV systolic pump function were diminished at rest and failed to increase appropriately during dobutamine stress. Impaired systolic pump function was associated with decreased RV diastolic compliance but enhanced RV myocardial contractility. These findings contrasted markedly with the effects of isolated PI observed in a similar model [33]. In addition, PS-PI resulted in a smaller regurgitant fraction, more RV hypertrophy, and a smaller increase in RV volumes than did isolated PI.

PS in addition to PI seemed to have been beneficial by promoting hypertrophy, limiting RV dilatation, and enhancing

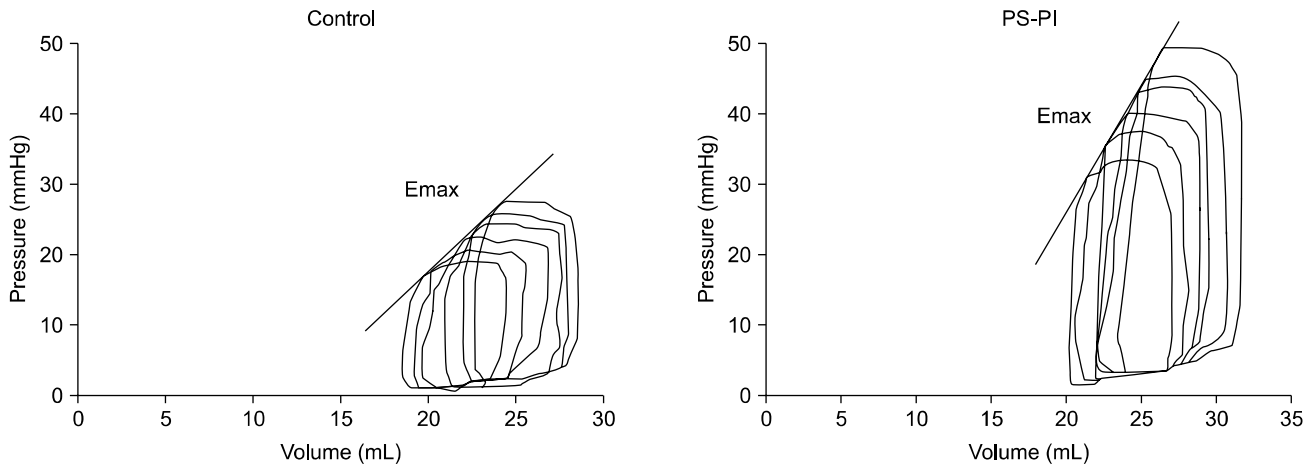


Fig. 2. Representative right ventricular pressure-volume loop of a pig with combined pulmonary stenosis-pulmonary insufficiency (PS-PI) and a control animal (measured at rest) at 3 month follow-up. Emax, slope of end-diastolic pressure-volume relation (From Karl TR. *Ann Pediatr Card* 2008;1:93-100, with permission from *Annals of Pediatric Cardiology*) [31].

myocardial contractility. These beneficial effects of short to intermediate term stenosis on RV myocardial contractility raise many questions in light of the known adverse effects of long term severe PS on RV function. However, this also brings into question the long-held belief that stenosis, even mild, is detrimental to RV function while insufficiency is well tolerated.

RELEVANCE TO TOF REPAIR TECHNIQUE

The acute change from a pressure loaded to a volume loaded RV, in addition to the right ventriculotomy, can adversely affect the performance of the RV in the immediate postoperative period [33,34]. A number of valve sparing techniques have been advocated across the years, including commissurotomy, rigid or balloon intraoperative dilation, and even acceptance of systemic RV pressure in order to maintain competence of a moderately restrictive valve [35]. Our understanding of postoperative TOF physiology leads us directly to the transatrial-transpulmonary (TA-TP) tetralogy repair as a possible solution. The TA-TP approach involves RVOT resection via the TV and PV, and VSD closure via the TV [36]. We try to complete the repair without division of the annulus, although this is not often possible. As an alternative we can perform a limited ventriculotomy, which is reconstructed with a transannular patch. We can usually avoid

incision into the RV body, limiting the extent to the outlet portion of RV or infundibulum, which has a relatively minor functional contribution to RV stroke volume (Fig. 3) [31,37]. The TA-TP approach has resulted in significantly less RV dilatation and better preservation of contractility at 10 year follow-up [38,39]. Since the presentation of the pulmonary cusp augmentation technique by Sung et al. [40], we have adopted that strategy for most patients requiring a transannular patch.

Our current operative technique is outlined in Figs. 3, 4. A patch of autologous pericardium is harvested and treated with 0.2% glutaraldehyde for 10 minutes. CPB is established (34°C) via bicaval and aortic cannulation. Systemic to PA shunts, if present, are divided on CPB. The heart is arrested with antegrade cold blood cardioplegia. The right atrium is opened longitudinally, and the left heart is vented through the foramen ovale or atrial septal defect (ASD). A longitudinal incision is made in the main PA and extended to the PV annulus. Commissural fusion or tethering of the leaflets to the PA wall is addressed with simple incision. Radical excision of the parietal extension of the infundibular septum is performed through the TV and PA as required (Fig. 4) [31]. Hegar dilators are passed through the TV into the main PA. If the weight-indexed annular Z score is <0 , the annulus is also divided [41].

In the majority of cases the PV will be bicuspid with location of the commissures at 90 and 270 degrees. An incision

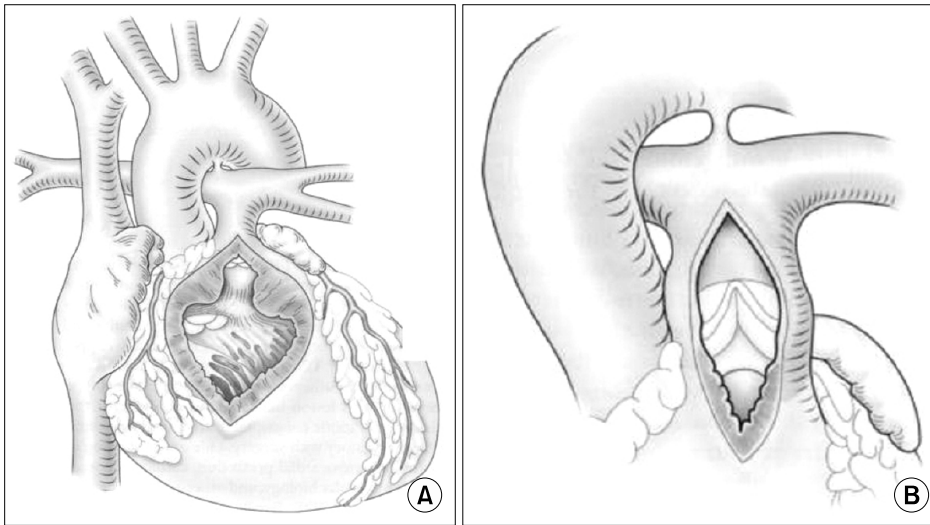


Fig. 3. Comparison of the classical transventricular approach (A) and the transatrial-transpulmonary approach (B). In the latter strategy the right ventricular (RV) incision is limited to what is required to relieve the RV outflow tract obstruction (RVOTO), with ventricular septal defect closure and RVOT resection performed via the tricuspid valve and pulmonary valve (From Karl TR. *Ann Pediatr Card* 2008;1:93-100, with permission from *Annals of Pediatric Cardiology*) [31].

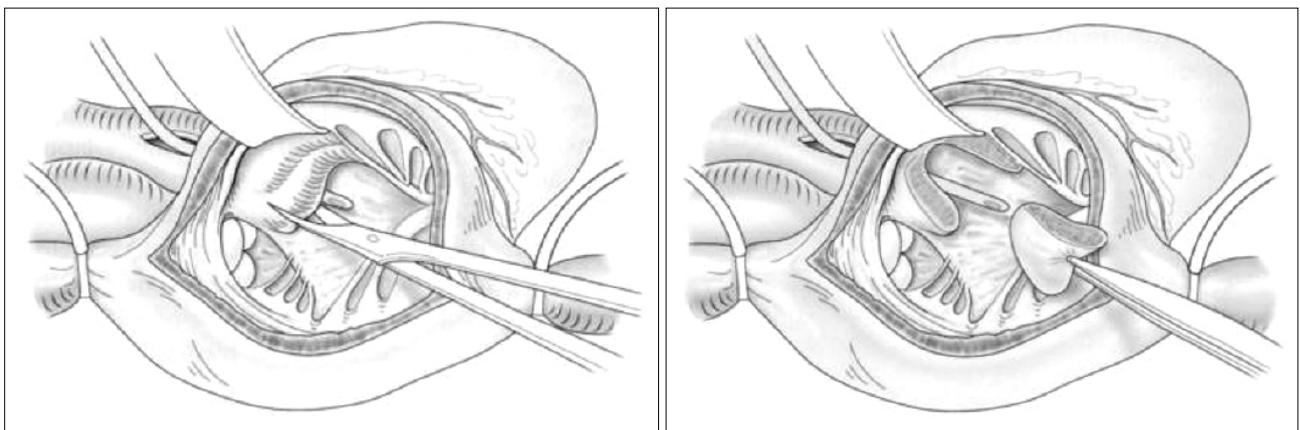


Fig. 4. Resection of the parietal extension of the infundibular septum, using a transtricuspid approach. A Hegar dilator has been passed from the pulmonary artery into the right ventricular (RV) to demonstrate the location of the RV outflow tract (From Karl TR. *Ann Pediatr Card* 2008;1:93-100, with permission from *Annals of Pediatric Cardiology*) [31].

is made in the middle of the anterior cusp and then extended to the RV free wall for approximately 10 to 15 mm. If the commissures are located at 0 and 180 degrees, or in an oblique configuration, we divide the PV at or near the anterior commissure to preserve as much valve tissue as possible, as described by Sung et al. [40]. The division of the remaining obstructing muscular and fibrous bands is performed through the limited ventriculotomy. The VSD and ASD are closed through the TV, the heart is de-aired, and the aortic clamp is removed.

For transannular reconstructions (i.e., cases in which the PV cannot be spared) a triangular autologous pericardial

patch is sutured to the endocardium from the most inferior aspect of the right ventriculotomy up to the hinge point of the anterior cusp, and then along the divided edge of the valve on either side. The size of this patch is determined by the indexed PV annular diameter, aiming to exceed this value by 2 to 3 mm. When the anterior cusp is small or the anterior commissure is located at 180 degrees, the patch is anchored to the main PA. In patients in whom the commissure is eccentric, the patch is sutured to the main PA on one side and to the free edge of the leaflet on the other side. Then a second patch is used to close the RVOT and the pulmonary arteriotomy, thus recreating a sinus of Valsalva over the aug-

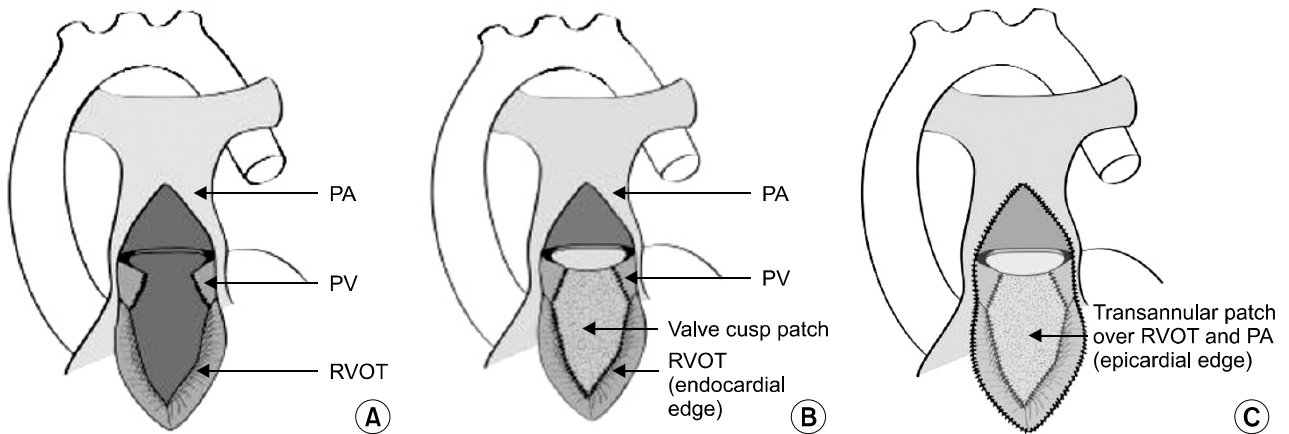


Fig. 5. Pulmonary cusp augmentation repair technique. (A) A transannular incision has been created according to calibration of the right ventricular outflow tract (RVOT) diameter. The incision divides the anterior pulmonary valve leaflet, although the exact location will vary with the valve orientation and morphology. (B) A triangular patch of glutaraldehyde-preserved autologous pericardium is sutured to the epicardial edge of the RVOT incision and to the divided edges of the valve leaflet. The leaflet dimensions are based on the caliber of a normal pulmonary valve diameter and should provide sufficient free edge diameter to ensure coaptation with the native valve remnant. (C) A second larger oval patch of the same material is sutured to the epicardial aspect of the RVOT incision and to the edges of the pulmonary arteriotomy, creating a sinus anterior to the reconstructed leaflet. PA, pulmonary artery; PV, pulmonary valve (From Karl TR. *Ann Pediatr Card* 2008;1:93-100, with permission from *Annals of Pediatric Cardiology*) [31].

mented valve leaflet (Fig. 5) [31].

In our preliminary report of this technique, 43 patients with TOF and 2 patients with isolated PV stenosis had relief of RVOTO with either a transannular patch plus PV cusp augmentation (n=18) or a transannular patch alone (n=25) [34]. The median age (5.3 vs. 3.2 months, p=0.09) and weight (6.4 vs. 5.2 kg, p=0.3) were similar for the cusp augmentation and transannular patch groups, respectively. The diameter of the PV annulus (6.4 vs. 6.0 mm, p=0.57) and the McGoon index (1.47 vs. 1.69, p=0.75) were also similar. The mean aortic clamp time (48±18 minutes vs. 52±19 minutes, p=0.46) and median CPB time (89 vs. 91 minutes, p=0.9) did not differ. Patients with PV cusp augmentation had a shorter duration of intubation (p<0.001) and intensive care unit stay (p<0.001). Thirteen patients with a transannular patch and 1 patient with PV cusp augmentation required inotropic support for more than 72 hours (p=0.001). Discharge echocardiograms demonstrated moderate or severe PI in 5 patients with PV cusp augmentation and in 21 patients with a transannular patch (p<0.001). At 7.5 months, 3 patients (17%) with PV cusp augmentation had progression of PI. The degree of PI at discharge diminished as we gained experience with the Sung

technique, and the current expectation is trivial to mild PI in the immediate postoperative period.

Of the 18 patients who underwent PV cusp augmentation, 1 was lost to follow-up. Two patients required reintervention. One patient presented to the hospital 3 months postoperatively with a delayed pericardial effusion and required a pericardial window. The second patient was symptomatic with persistent subvalvar PS. She underwent operative RVOT muscle bundle resection 2 years after her original repair. This patient had moderate PI at discharge, and the degree of PI did not change during follow-up. At a median follow-up of 7.5 months (range, 0 to 29 months), 6 of the 17 patients (35.3%) had moderate or severe PI at follow-up. Three patients (17%) who underwent PV cusp augmentation had progression of PI when compared with the degree of PI at discharge. Similarly improved outcomes have been demonstrated in a larger cohort by Sung et al. [40], employing the same basic technique. Based on these results we have adopted the Sung repair as our standard procedure for TOF, and have found it to be possible in 95% of cases. While not “perfect,” in our opinion it is the most effective strategy to date for TOF repair.

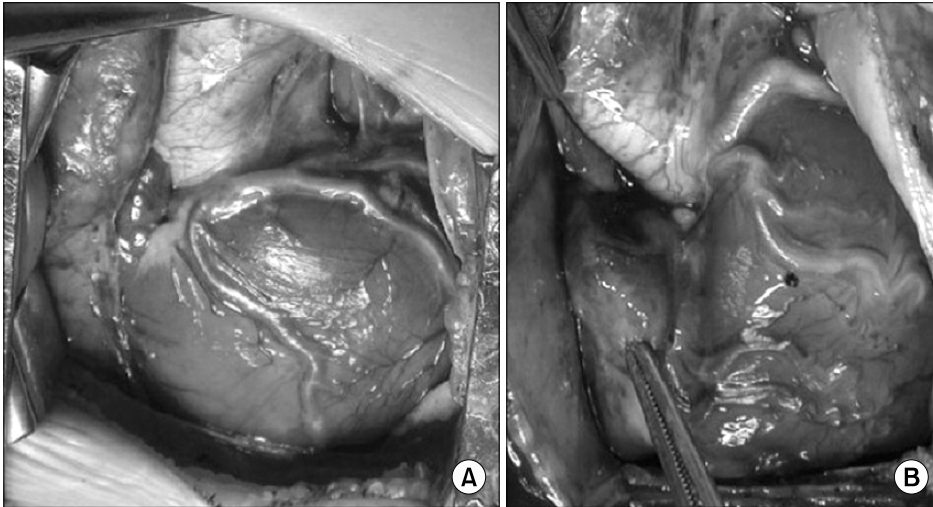


Fig. 6. Coronary anomalies complicating tetralogy of Fallot repair. (A) Left anterior descending from the right coronary artery. (B) All coronaries arising from the right sinus. Both situations would be problematic for a transventricular repair, but both patients had successful transatrial-transpulmonary repairs (From Karl TR. *Ann Pediatr Card* 2008;1:93-100, with permission from *Annals of Pediatric Cardiology*) [31].

DISCUSSION

Several groups have described strategies to limit the size of the right ventriculotomy, hoping to reduce the incidence of PI after primary repair. Valved homografts and xenografts were proposed as the most anatomic and physiologic way to resolve RVOT obstruction, but all eventually need replacement because of patient growth and conduit deterioration [42]. The use of a monocusp valve created from pericardium, xenograft valve cusps, fascia lata, autologous pulmonary artery wall, or polytetrafluorethylene has been shown to decrease short-term PI [43-45]. However due to limited durability, many groups have abandoned the monocusp, citing lack of proven significant advantage for the long term [42,43]. Seventeen percent of our patients had progression of PI on short-term follow-up (median 7.5 months). In the Sung series, 2 of the 18 patients also had progression of PI at the 10 month follow-up [40]. We continue to follow these patients to assess ultimate durability.

The Sung technique may be different than prior iterations in that it preserves the native hinge mechanism of the valve cusps, especially when the PV is bicuspid and the commissures are located at 90 and 270 degrees. The use of native valve tissue also offers the theoretical potential for growth. In our experience the technique can be applied in all but a small subgroup of patients who have a very small pulmonary annulus with inadequate native PV tissue. In this group of patients the TA-TP repair with a minimal right ventriculotomy and

closure of the RVOT with a simple transannular patch may be preferable. Sung augmentation of the PV cusp with autologous pericardium is simple, does not significantly prolong the operation, reduces the degree of PI in the immediate post-operative period, and potentially improves the early outcome after TA-TP TOF repair.

TOF WITH ANOMALOUS CORONARY ARTERIES

Coronary anomalies occur in between 5% and 12% of patients with TOF [18-20]. The most commonly encountered patterns are left anterior descending (LAD) from right coronary artery (RCA), RCA from left coronary artery (LCA), RCA from LAD, large conal artery from RCA, and single RCA (Fig. 6) [31]. Coronary anatomy can be imaged effectively with standard 2D echocardiography. Abnormalities of epicardial distribution are generally not associated with myocardial ischemia. Their main importance is related to surgical repair, at which time coronary injury could occur during the ventriculotomy or the RVOT resection. One technical advantage of the TA-TP approach is the possibility of undertaking repair without an extracardiac conduit, even when a major coronary artery branch crosses the infundibulum, (which usually precludes a transventricular repair) (Figs. 5, 6) [31,41]. We presented results of this approach nearly a decade ago, with a continued favourable experience to date (Fig. 7) [31,41]. We now employ this technique in Brisbane, usu-

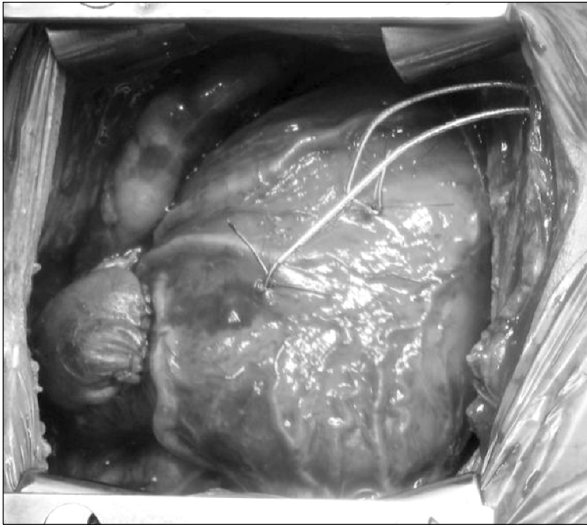

Fig. 7. Tetralogy of Fallot with right coronary artery arising from left anterior descending and crossing the right ventricular outflow tract. A transatrial-transpulmonary repair has been performed with a transannular patch stopping short of the anomalous coronary. Cusp augmentation can also be used when there is sufficient coronary-free right ventricular wall (From Karl TR. *Ann Pediatr Card* 2008;1:93-100, with permission from *Annals of Pediatric Cardiology*) [31].

ally with the Sung modification. In our initial experience at the Royal Children's Hospital, Melbourne, the TA-TP approach was used in 611 TOF repairs, 36 (5.9%) of which were associated with a surgically relevant coronary artery anomaly. The median age and weight of the initial cohort at repair were 23 months (range, 2.8 to 170 months) and 9.9 kg (range, 5.2 to 41 kg), respectively. Anomalies included LAD from RCA or single RCA (n=22), RCA from LCA or LAD (n=8), and large RCA conal branch (n=6). The TA-TP approach was successful in 34/36 cases, in 25 of which placement of a limited transannular patch was necessary. Two patients had a RV-PA conduit as a result of proximity of the coronary branch to the PV annulus and our inability to adequately relieve the RVOTO. There was no early or late death in the anomalous coronary patients. Mean RV-PA systolic pressure gradient at last follow-up was 19 mmHg (95% confidence interval, 14.5 to 24 mmHg), compared with 15 mmHg (95% confidence interval, 12.5 to 17.5 mmHg) for patients with normal coronary arteries (p=0.3). Actuarial freedom from reoperation at 120 months was 96.5% (95% con-

fidence interval, 79.8% to 99.5%) and was similar for patients with and without coronary artery abnormalities (p=0.92). Thus the published Melbourne series of patients with anomalous coronary arteries demonstrates the same short and long term results after repair as seen in the remainder of our cohort with TOF and normal branching patterns, with similarly favourable results obtained in Brisbane.

TIMING OF SURGERY

The best age for TOF repair remains controversial, and the technique employed may influence the timing of operation. TOF can be repaired at any age with a low risk in units equipped to deal with complex heart surgery in infants. The TA-TP strategy with Sung modification is easier and more reliable in infants 2 to 6 months of age than it is in neonates, but is certainly possible at any age. We continue to use the algorithm initially set forth by Karl et al. [36] at the Royal Children's Hospital, Melbourne. Neonates with an unacceptable level of haemoglobin saturation and/or hypercyanotic spells may be palliated with a transsternal modified Blalock Taussig shunt (MBTS). Although there has been some past morbidity and interval mortality with this approach, many centers have reported excellent outcomes and a risk of palliation that approaches 0% [36,44-46]. Ductal and RVOT stenting have also evolved to become effective strategies in the hands of some teams. If the goal is to delay surgical repair until the child is bigger, a weight of 5 to 7.5 kg can usually be achieved with neonatal ductal stenting [47].

Proponents of primary neonatal repair cite factors such as prevention of time related end organ damage from cyanosis, removal of stimulus for RV hypertrophy and fibrosis, improved lung development (vascular and alveolar), avoidance of deleterious effects and risks of palliative shunts, and psychosocial-economic issues (for the family and care givers). Most of these arguments have merit, although the difference between neonatal and later infant repair seems difficult to measure. Many surgeons using a neonatal tetralogy repair strategy still employ a transventricular approach, with a transannular valveless RVOT patch reconstruction, despite the (now well documented) detrimental effects of these strategies on the RV. Furthermore, an interatrial communication is often

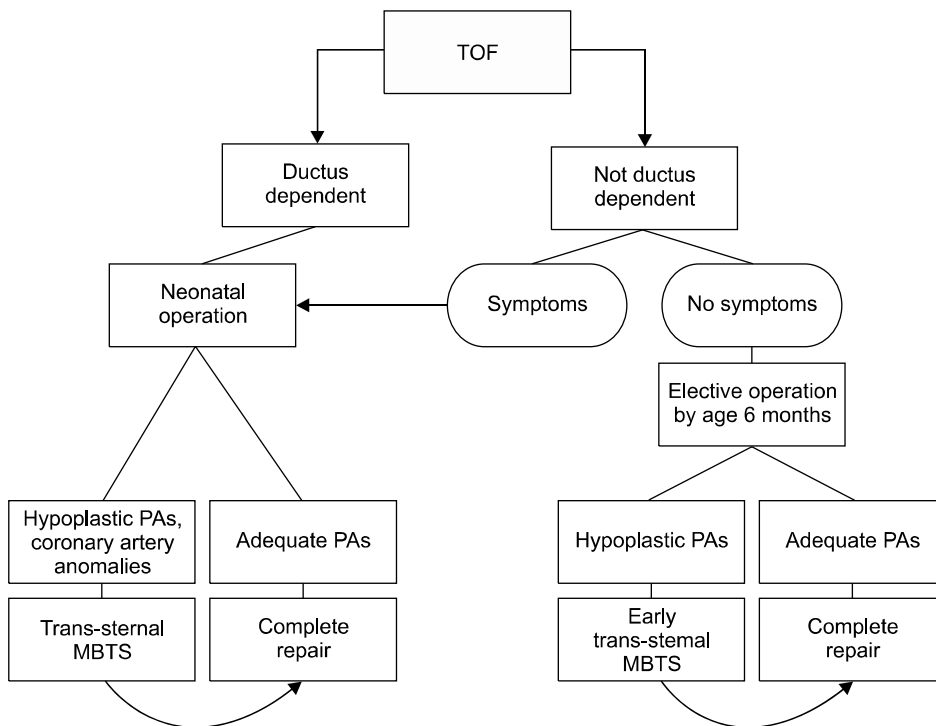


Fig. 8. Current protocol for timing of repair for neonates and infants with tetralogy of Fallot (TOF). In practice, most patients will undergo elective repair by 2 to 4 months of age, or sooner if indicated clinically. The trans-sternal modified Blalock Taussig shunt (MBTS) shunt strategy (or ductal stent) is reserved for selected cases with unfavourable anatomy, extracardiac co-morbidities, and other unusual circumstances. PA=pulmonary artery (From Karl TR. *Ann Pediatr Card* 2008;1:93-100, with permission from *Annals of Pediatric Cardiology*) [31].

maintained post-operatively in very young patients, creating a situation in which neither PO₂ nor cardiac output can be guaranteed. Although survival statistics are generally favourable, most published neonatal TOF series have not had a long enough follow-up time to fully assess the effects of free PI [48-50].

The argument is often put forth as primary neonatal repair versus palliative systemic to pulmonary arterial shunt with later repair. However, virtually every published report of infant or neonatal tetralogy repair excludes or mentions patients who had a palliative shunt rather than a primary repair. Therefore even the strongest proponents of neonatal primary, suggesting that the MBTS is still useful for selected cases, such as anomalous coronaries, multiple VSDs, generalized critical illness, rehabilitation of small or distorted PAs, prematurity and low birth weight, need to establish a volume load to prevent diastolic dysfunction after repair (older children), and even religious objection to blood transfusion. In fact, most tetralogy patients (probably 75%) do not require any surgical treatment in the neonatal period. The important argument then is not “primary repair vs. shunt” but “neonatal vs. non-neonatal elective primary repair”.

Newborns with CHD are known to be susceptible to abnormal brain development and widespread central nervous system abnormalities, which may be exacerbated following neonatal operations utilizing CPB, especially with deep hypothermia and circulatory arrest (DHCA). This consideration may be especially relevant in syndromic TOF. Agergaard et al. [50] looked at CHD patients in Denmark, noting that 46/2,478 cases had 22q11.2 chromosomal deletions, a prevalence of 1.9% [51]. Fifteen of these cases had TOF. Other syndromes (e.g., VATER, Down’s, Cornelia de Lange, etc.) may complicate the clinical picture in TOF and change the repair risk, especially for neonates.

Arguments for neonatal repair in the current era should include a detailed assessment of neurodevelopmental status, which rarely appears in outcome data for “early” TOF repair, even if “prevention of cerebral injury” is widely cited as a justification for early repairs. Newborns are known to be more susceptible to brain injury such as periventricular leukomalacia in the perioperative period, especially with the use of DHCA [52,53]. Nonetheless, many neonatal TOF repairs (even in the current era) have employed a CPB strategy involving DHCA and/or low flow CPB. It is clear that the fre-

quency and severity of brain injury (pre and postoperatively) for all neonatal heart surgery depends on the sensitivity of tools used to assess it [54]. It is perhaps less evident that for cyanotic lesions, cerebral oxygen delivery actually may be (temporarily) worse immediately after repair than before repair, at the most vulnerable time for cerebral injury in the child's lifetime. This is generally not the case with non-neonatal repair. Therefore if neonatal tetralogy surgery can be safely delayed, and if other outcome variables would look similar with an operation at 3 to 6 months of age (with or without a MBTS), then one would want to follow a strategy of elective non-neonatal primary repair. There are many excellent cardiac surgical units (all with favourable neonatal experience in other lesions) in which elective primary repair in newborns with TOF is still avoided (Toronto, Melbourne, Chicago, Houston, New Delhi, San Francisco, Buenos Aires, London, Auckland, Tokyo, Santiago, Madrid, Paris, etc.). The preferred solution will vary from unit to unit, and our thinking (as well as that of many other teams) remains in evolution on this point. Our current preference for timing of operation is presented in Fig. 8 [31]. Non-neonatal primary elective repair (2 to 6 months) is considered preferable to a staged procedure involving palliative shunts in most patients. Cyanotic neonates who are suitable anatomic and physiologic candidates will also have a primary repair. Infants with TOF and atrioventricular septal defect are generally managed along the same lines, and with PV reconstruction according to the Sung technique [54].

CONCLUSION

Significant refinements have been made in the repair strategy for TOF, based on improved understanding of post repair physiology. Important considerations for timing and technique of surgery, have been presented, and continued evolution is expected. Expanded use of the PV reconstruction technique outlined herein, whatever the age of repair, may improve long term outcome.

REFERENCES

1. Knott-Craig CJ, Elkins RC, Lane MM, Holz J, McCue C, Ward KE. *A 26-year experience with surgical management of tetralogy of Fallot: risk analysis for mortality or late reintervention.* Ann Thorac Surg 1998;66:506-11.
2. Nollert G, Fischlein T, Bouterwek S, Bohmer C, Klinner W, Reichart B. *Long-term survival in patients with repair of tetralogy of Fallot: 36-year follow-up of 490 survivors of the first year after surgical repair.* J Am Coll Cardiol 1997;30:1374-83.
3. Lillehei CW, Varco RL, Cohen M, et al. *The first open heart corrections of tetralogy of Fallot: a 26-31 year follow-up of 106 patients.* Ann Surg 1986;204:490-502.
4. Hickey EJ, Veldtman G, Bradley TJ, et al. *Functional health status in adult survivors of operative repair of tetralogy of fallot.* Am J Cardiol 2012;109:873-80.
5. Gorla R, Macchi A, Franzoni I, et al. *Unrepaired tetralogy of Fallot in an 85-year-old man.* Congenit Heart Dis 2012 Apr 3 [Epub]. DOI: 10.1111/j.1747-0803.2012.00642.x.
6. Jacobs JP, O'Brien SM, Pasquali SK, et al. *Variation in outcomes for benchmark operations: an analysis of the Society of Thoracic Surgeons Congenital Heart Surgery Database.* Ann Thorac Surg 2011;92:2184-91.
7. Kilner PJ, Balossino R, Dubini G, et al. *Pulmonary regurgitation: the effects of varying pulmonary artery compliance, and of increased resistance proximal or distal to the compliance.* Int J Cardiol 2009;133:157-66.
8. Hon JK, Steendijk P, Khan H, Wong K, Yacoub M. *Acute effects of pulmonary artery banding in sheep on right ventricle pressure-volume relations: relevance to the arterial switch operation.* Acta Physiol Scand 2001;172:97-106.
9. Geva T. *Tetralogy of Fallot repair: ready for a new paradigm.* J Thorac Cardiovasc Surg 2012;143:1305-6.
10. Leeuwenburgh BP, Helbing WA, Steendijk P, Schoof PH, Baan J. *Biventricular systolic function in young lambs subject to chronic systemic right ventricular pressure overload.* Am J Physiol Heart Circ Physiol 2001;281:H2697-704.
11. Li W, Hornung TS, Francis DP, et al. *Relation of biventricular function quantified by stress echocardiography to cardiopulmonary exercise capacity in adults with Mustard (atrial switch) procedure for transposition of the great arteries.* Circulation 2004;110:1380-6.
12. Lopes Cardozo RH, Steendijk P, Baan J, Brouwers HA, De Vroomen M, Van Bel F. *Right ventricular function in respiratory distress syndrome and subsequent partial liquid ventilation: homeometric autoregulation in the right ventricle of the newborn animal.* Am J Respir Crit Care Med 2000;162(Pt 1):374-9.
13. Schwartz MC, Rome JJ, Gillespie MJ, et al. *Relation of left ventricular end diastolic pressure to right ventricular end diastolic volume after operative treatment of tetralogy of Fallot.* Am J Cardiol 2012;109:417-22.
14. Frigiola A, Redington AN, Cullen S, Vogel M. *Pulmonary regurgitation is an important determinant of right ventricular*

- contractile dysfunction in patients with surgically repaired tetralogy of Fallot.* *Circulation* 2004;110(11 Suppl 1):II153-7.
15. Lim C, Lee JY, Kim WH, et al. *Early replacement of pulmonary valve after repair of tetralogy: is it really beneficial?* *Eur J Cardiothorac Surg* 2004;25:728-34.
 16. Therrien J, Siu SC, McLaughlin PR, Liu PP, Williams WG, Webb GD. *Pulmonary valve replacement in adults late after repair of tetralogy of Fallot: are we operating too late?* *J Am Coll Cardiol* 2000;36:1670-5.
 17. Tulevski II, Hirsch A, Dodge-Khatami A, Stoker J, van der Wall EE, Mulder BJ. *Effect of pulmonary valve regurgitation on right ventricular function in patients with chronic right ventricular pressure overload.* *Am J Cardiol* 2003;92:113-6.
 18. van Straten A, Vliegen HW, Hazekamp MG, et al. *Right ventricular function after pulmonary valve replacement in patients with tetralogy of Fallot.* *Radiology* 2004;233:824-9.
 19. Vliegen HW, van Straten A, de Roos A, et al. *Magnetic resonance imaging to assess the hemodynamic effects of pulmonary valve replacement in adults late after repair of tetralogy of Fallot.* *Circulation* 2002;106:1703-7.
 20. Brili S, Stamatopoulos I, Barbetseas J, et al. *Usefulness of dobutamine stress echocardiography with Tissue Doppler imaging for the evaluation and follow-up of patients with repaired tetralogy of Fallot.* *J Am Soc Echocardiogr* 2008; 21:1093-8.
 21. Mulder BJ, Vliegen HW, van der Wall EE. *Diastolic dysfunction: a new additional criterion for optimal timing of pulmonary valve replacement in adult patient with tetralogy of Fallot?* *Int J Cardiovasc Imaging* 2008;24:867-70.
 22. Knirsch W, Dodge-Khatami A, Kadner A, et al. *Assessment of myocardial function in pediatric patients with operated tetralogy of Fallot: preliminary results with 2D strain echocardiography.* *Pediatr Cardiol* 2008;29:718-25.
 23. Carlucci C, Giamberti A, Pome G, et al. *Right ventricular restoration in adult patients after TOF surgery.* *Pediatr Med Chir* 2008;30:9-15.
 24. Lurz P, Coats L, Khambadkone S, et al. *Percutaneous pulmonary valve implantation: impact of evolving technology and learning curve on clinical outcome.* *Circulation* 2008; 117:1964-72.
 25. Ammash NM, Dearani JA, Burkhardt HM, Connolly HM. *Pulmonary regurgitation after tetralogy of Fallot repair: clinical features, sequelae, and timing of pulmonary valve replacement.* *Congenit Heart Dis* 2007;2:386-403.
 26. Meijboom FJ, Roos-Hesselink JW, McGhie JS, et al. *Consequences of a selective approach toward pulmonary valve replacement in adult patients with tetralogy of Fallot and pulmonary regurgitation.* *J Thorac Cardiovasc Surg* 2008;135: 50-5.
 27. Gengsakul A, Harris L, Bradley TJ, et al. *The impact of pulmonary valve replacement after tetralogy of Fallot repair: a matched comparison.* *Eur J Cardiothorac Surg* 2007;32:462-8.
 28. Yoo BW, Kim JO, Kim YJ, et al. *Impact of pressure load caused by right ventricular outflow tract obstruction on right ventricular volume overload in patients with repaired tetralogy of Fallot.* *J Thorac Cardiovasc Surg* 2012;143:1299-304.
 29. Geva T. *Repaired tetralogy of Fallot: the roles of cardiovascular magnetic resonance in evaluating pathophysiology and for pulmonary valve replacement decision support.* *J Cardiovasc Magn Reson* 2011;13:9.
 30. Kuehne T, Gleason BK, Saeed M, et al. *Combined pulmonary stenosis and insufficiency preserves myocardial contractility in the developing heart of growing swine at mid-term follow-up.* *J Appl Physiol* 2005;99:1422-7.
 31. Karl TR. *Tetralogy of Fallot: current surgical perspective.* *Ann Pediatr Card* 2008;1:93-100.
 32. Kuehne T, Saeed M, Gleason K, et al. *Effects of pulmonary insufficiency on biventricular function in the developing heart of growing swine.* *Circulation* 2003;108:2007-13.
 33. Gundry SR, Razzouk AJ, Boskind JF, Bansal R, Bailey LL. *Fate of the pericardial monocusp pulmonary valve for right ventricular outflow tract reconstruction. Early function, late failure without obstruction.* *J Thorac Cardiovasc Surg* 1994; 107:908-12.
 34. Anagnostopoulos P, Azakie A, Natarajan S, Alphonso N, Brook MM, Karl TR. *Pulmonary valve cusp augmentation with autologous pericardium may improve early outcome for tetralogy of Fallot.* *J Thorac Cardiovasc Surg* 2007;133:640-7.
 35. Bacha E. *Valve-sparing options in tetralogy of Fallot surgery.* *Semin Thorac Cardiovasc Surg Pediatr Card Surg Annu* 2012;15:24-6.
 36. Karl TR, Sano S, Pornviliwan S, Mee RB. *Tetralogy of Fallot: favorable outcome of nonneonatal transatrial, transpulmonary repair.* *Ann Thorac Surg* 1992;54:903-7.
 37. Geva T, Powell AJ, Crawford EC, Chung T, Colan SD. *Evaluation of regional differences in right ventricular systolic function by acoustic quantification echocardiography and cine magnetic resonance imaging.* *Circulation* 1998;98: 339-45.
 38. Stellin G, Milanesi O, Rubino M, et al. *Repair of tetralogy of Fallot in the first six months of life: transatrial versus transventricular approach.* *Ann Thorac Surg* 1995;60(6 Suppl):S588-91.
 39. Atallah-Yunes NH, Kavey RE, Bove EL, et al. *Postoperative assessment of a modified surgical approach to repair of tetralogy of Fallot: long-term follow-up.* *Circulation* 1996;94(9 Suppl):II22-6.
 40. Sung SC, Kim S, Woo JS, Lee YS. *Pulmonic valve annular enlargement with valve repair in tetralogy of Fallot.* *Ann Thorac Surg* 2003;75:303-5.
 41. Brizard CP, Mas C, Sohn YS, Cochrane AD, Karl TR. *Transatrial-transpulmonary tetralogy of Fallot repair is ef-*

- fective in the presence of anomalous coronary arteries.* J Thorac Cardiovasc Surg 1998;116:770-9.
42. Sano S, Karl TR, Mee RB. *Extracardiac valved conduits in the pulmonary circuit.* Ann Thorac Surg 1991;52:285-90.
 43. Roughneen PT, DeLeon SY, Parvathaneni S, Cetta F, Eidem B, Vitullo DA. *The pericardial membrane pulmonary monocusp: surgical technique and early results.* J Card Surg 1999;14:370-4.
 44. Gladman G, McCrindle BW, Williams WG, Freedom RM, Benson LN. *The modified Blalock-Taussig shunt: clinical impact and morbidity in Fallot's tetralogy in the current era.* J Thorac Cardiovasc Surg 1997;114:25-30.
 45. Stewart RD, Backer CL, Young L, Mavroudis C. *Tetralogy of Fallot: results of a pulmonary valve-sparing strategy.* Ann Thorac Surg 2005;80:1431-8.
 46. Tweddell JS, Simpson P, Li SH, et al. *Timing and technique of pulmonary valve replacement in the patient with tetralogy of Fallot.* Semin Thorac Cardiovasc Surg Pediatr Card Surg Annu 2012;15:27-33.
 47. Pigula FA, Khalil PN, Mayer JE, del Nido PJ, Jonas RA. *Repair of tetralogy of Fallot in neonates and young infants.* Circulation 1999;100(19 Suppl):II157-61.
 48. Van Arsdell GS, Maharaj GS, Tom J, et al. *What is the optimal age for repair of tetralogy of Fallot?* Circulation 2000;102(19 Suppl 3):III123-9.
 49. Hirsch JC, Mosca RS, Bove EL. *Complete repair of tetralogy of Fallot in the neonate: results in the modern era.* Ann Surg 2000;232:508-14.
 50. Agergaard P, Hebert A, Sorensen KM, Ostergaard JR, Olesen C. *Can clinical assessment detect 22q11.2 deletions in patients with cardiac malformations?: a review.* Eur J Med Genet 2011;54:3-8.
 51. Galli KK, Zimmerman RA, Jarvik GP, et al. *Periventricular leukomalacia is common after neonatal cardiac surgery.* J Thorac Cardiovasc Surg 2004;127:692-704.
 52. Licht DJ, Wang J, Silvestre DW, et al. *Preoperative cerebral blood flow is diminished in neonates with severe congenital heart defects.* J Thorac Cardiovasc Surg 2004;128:841-9.
 53. Miller SP, McQuillen PS, Hamrick S, et al. *Abnormal brain development in newborns with congenital heart disease.* N Engl J Med 2007;357:1928-38.
 54. Karl TR, Provenzano SC, Nunn GR, Anderson RH. *The current surgical perspective to repair of atrioventricular septal defect with common atrioventricular junction.* Cardiol Young 2010;20 Suppl 3:120-7.