

CASE REPORT

Ethmoid malformation associated with pediatric nasal polyposis and allergic fungal sinusitis

Cameron G. Hanson^{1,2,*} and Todd B. Proctor³¹School of Health Sciences, Oakland University, Rochester, MI, USA, ²College of Osteopathic Medicine, Kansas City University of Medicine and Biosciences, Kansas City, MO, USA, and ³Department of Otolaryngology, Beaumont Hospital, Troy, MI, USA

*Correspondence address. School of Health Sciences, Oakland University, 230 Science and Engineering Building, Rochester, MI 48309, USA.
Tel: +1-24-88-72-97-72; E-mail: cameron.g.hanson@gmail.com

Abstract

A 17-year-old female with allergic fungal sinusitis and nasal polyposis presented with epistaxis in the emergency room. On examination, right-sided proptosis and irregular nasal obstruction were observed in the right nasal cavity. CT imaging revealed massive right-sided polyposis and significant ipsilateral malformation with boney architecture preservation of the ethmoidal labyrinth and lamina papyracea. The patient was treated surgically with symptomatic improvement. These findings indicate a unique malformation of the ethmoid while the patient was in development. To the authors' knowledge, this anatomical malformation has not been previously described in the literature. Physicians should implement diagnostic procedures early if nasal polyposis and allergic fungal sinusitis is suspected in pediatric patients, especially with periorbital involvement, to mitigate the risk of bony malformations of the sinuses.

INTRODUCTION

Nasal polyposis and allergic fungal sinusitis (AFS) can be a severe condition, especially in the pediatric population. Early detection and surgical management is key to reducing potential comorbidities. We describe a novel case of malformation of the ethmoid sinus and lamina papyracea due to unilateral nasal polyposis and AFS.

CASE REPORT

A 17-year-old female with history of progressive nasal obstruction, purulent drainage, cough and anosmia over 8 months, was diagnosed with a nasal polyp by her primary doctor and was treated with azithromycin, and montelukast sodium with negligible relief. Intranasal steroids were also not effective. Her

past medical history included insulin resistant diabetes, allergic rhinitis, unilateral proptosis of the right eye and Hashimoto's thyroiditis. Allergy testing had been done 12 years prior.

She presented to the emergency room with epistaxis, prompting an otolaryngology referral.

On examination, the patient's nasal septum was deviated to the left, irregular polyps were completely occluding the right nasal cavity, and there was unilateral right-sided proptosis. Sweat chloride [1] test was negative. A computed tomography (CT) scan of the sinuses was ordered.

The results of the CT indicated complete opacification of the frontal, ethmoidal, sphenoidal and maxillary sinus on the right side with hyper-dense intraluminal soft tissue filling the sinus cavities. Significant widening of the ostiomeatal complex was observed (Fig. 1). Soft tissue from the right maxillary sinus extended into the right side of the nasal cavity. Extensive

Received: March 29, 2017. Accepted: May 17, 2017

Published by Oxford University Press and JSCR Publishing Ltd. All rights reserved. © The Author 2017.

This is an Open Access article distributed under the terms of the Creative Commons Attribution Non-Commercial License (<http://creativecommons.org/licenses/by-nc/4.0/>), which permits non-commercial re-use, distribution, and reproduction in any medium, provided the original work is properly cited. For commercial re-use, please contact journals.permissions@oup.com

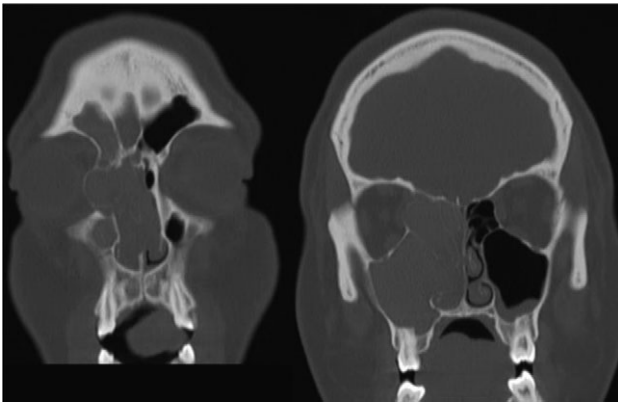


Figure 1: Coronal CT image indicating extent of soft tissue in the right nasal passage, malformation of the right lamina papyracea, and complete opacification of the right maxillary, ethmoidal and frontal sinus.

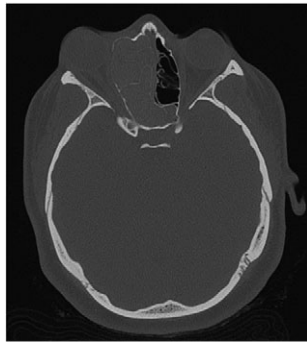


Figure 2: Axial CT image indicating widening of the ostiomeatal complex with malformation of the right ethmoid.

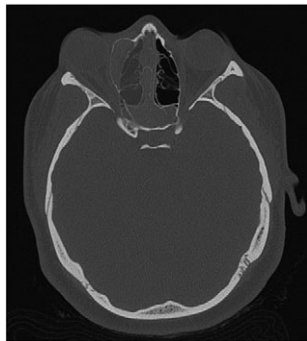


Figure 3: Axial CT view of the ethmoid labyrinth with the left side superimposed on the right side over the midline for comparison.

changes in the right ethmoidal labyrinth were also discovered. The intact lamella of the middle turbinate and lamella of the bulla ethmoidalis extended further laterally when compared to the left side, and lamina papyracea was protruding into the orbit (Figs 1 and 2). Options were discussed and endoscopic CT guided surgery was recommended.

Findings at surgery included extensive polyps and concretions filling all of the right side sinuses. The right lamina papyracea was ~2 cm lateral. Biopsies from both the right and left sinuses demonstrated focal fungal elements including spores and hyphae.

The patient had an uneventful postoperative course. The family decided against standard use of oral corticosteroids [2–4] due to

her Juvenile diabetes. Allergy management was recommended. Five weeks post-operatively, she had significant improvement in breathing and perceived improvement in proptosis, along with alleviated anosmia. At 10 weeks post-operatively, the patient perceived her proptosis to be nearly completely resolved and there was no sign of infection recurrence. The patient was informed she may need oculoplastic surgery to fully correct the malformed bone structure.

DISCUSSION

AFS is a known risk factor for development of nasal polyps [5, 6]. Incidences of AFS causing unilateral proptosis have also been described in the literature [7, 8]. The findings from the current CT, however, indicate a unique developmental process. When compared to the patient's left side, the extent is easily seen (Fig. 3). In consideration of the preservation of the ethmoid architecture along with the patient's age, it appears that due to the severity and duration of the polyposis and AFS, the ethmoidal labyrinth malformed while still in development. Contrastingly, in cases of several nasal polyposis, including those with ocular involvement, bone erosion and destruction are most frequently seen with respect to changes in bone anatomy [9]. Chronic remodeling of the ethmoid bone has been described in venous malformations [10], however, cases of nasal polyps leading to bone malformation are significantly underrepresented in the literature. CT imaging proved the most valuable diagnostic tool in examining the extent of the proptosis secondary to polyposis, as well as describing the changes in the ethmoid labyrinth structure. Surgical approach proved effective in reducing the patient's symptoms, as well as confirming the etiology of the unilateral proptosis.

In pediatric patients, nasal polyposis and AFS can precipitate secondary concerns. The current case indicates that these combined diagnoses may lead to malformations of the ethmoidal labyrinth. As such, CT diagnostic measures should be implemented early if nasal polyposis or AFS is suspected in juvenile cases, particularly with periocular involvement.

ACKNOWLEDGMENTS

This research did not receive any specific grant from funding agencies in the public, commercial, or not-for-profit sectors.

Signed consent was obtained from the patient.

CONFLICT OF INTEREST STATEMENT

None declared.

REFERENCES

1. Sheahan PO, Harvey RJ, Schlosser RJ. Nasal polyps in cystic fibrosis. In: Önerci TM, Ferguson BJ, eds. *Nasal Polyposis*. Berlin Heidelberg: Springer-Verlag, 2010;145–52. https://doi.org/10.1007/978-3-642-11412-0_17.
2. Schubert MS, Goetz DW. Evaluation and treatment of allergic fungal sinusitis. I. Demographics and diagnosis. *J Allergy Clin Immunol* 1998;**102**:387–94. [https://doi.org/10.1016/s0091-6749\(98\)70125-3](https://doi.org/10.1016/s0091-6749(98)70125-3).
3. Schubert MS, Goetz DW. Evaluation and treatment of allergic fungal sinusitis. II. Treatment and follow-up. *J Allergy Clin Immunol* 1998;**102**:395–402. [https://doi.org/10.1016/s0091-6749\(98\)70126-5](https://doi.org/10.1016/s0091-6749(98)70126-5).
4. Bent JP, Kuhn FA. Antifungal activity against allergic fungal sinusitis organisms. *Laryngoscope* 1996;**106**:1331–4. <https://doi.org/10.1097/00005537-199611000-00005>.

5. Asero R, Bottazi G. Hypersensitivity to molds in patients with nasal polyposis: a clinical study. *J Allergy Clin Immunol* 2000;**105**:186–8. [https://doi.org/10.1016/s0091-6749\(00\)90198-2](https://doi.org/10.1016/s0091-6749(00)90198-2).
6. Ponikau H, Sherris D, Kern E, Homburger H, Frigas E, Gaffey T, et al. The diagnosis and incidence of allergic fungal sinusitis. *Mayo Clin Proc* 1990;**74**:877–84. <https://doi.org/10.1097/00006454-200005000-00034>.
7. Coop CA, England RW. Allergic fungal sinusitis presenting with proptosis and diplopia: a review of ophthalmologic complications and treatment. *Allergy Asthma Proc* 2006;**27**: 72–6. <https://doi.org/10.1017/s0022215108003459>.
8. Geren BN, Brown HH, Hearnberger HG, Westfall CT. Allergic fungal sinusitis with unilateral eye involvement. *Arch Ophthalmol* 2004;**122**:1390–3. <https://doi.org/10.1001/archophth.122.9.1390>.
9. Nussenbaum B, Marple BF, Schwade ND. Characteristics of bony erosion in allergic fungal rhinosinusitis. *Otolaryngol Head Neck Surg* 2001;**124**:150–4. <https://doi.org/10.1067/mhn.2001.112573>.
10. Gertel AJ, Southwood JE, North PE, Poetker DM, Loehrl TA. Venous malformation of the ethmoid and sphenoid sinuses. *Am J Otolaryngol* 2016;**13**:12–6. <https://doi.org/10.1016/j.amjoto.2015.09.008>.