

Microtia Reconstruction and Postsurgical Grisel's Syndrome: A Rare Cause of Torticollis in a Child

Jay Ching Chieh Wang, MD*
 Claudia Malic, MD, FRCS
 (Plast)†
 Christopher Reilly, MD,
 FRCS‡§
 Cynthia Verchere, MD,
 FRCS†¶

Summary: Grisel's syndrome is an unusual but important cause of torticollis which may be encountered in a pediatric plastic surgery practice, where craniofacial and oropharyngeal surgeries are commonly performed. Grisel's syndrome is characterized by painful torticollis and limited cervical rotation, and the diagnosis is confirmed via radiologic imaging. Initial management of Grisel's syndrome is with anti-inflammatories and in some cases antibiotics. In unresolving or recurrent cases, more invasive treatments, such as cervical collar, halo, or surgical arthrodesis, may be considered. (*Plast Reconstr Surg Glob Open* 2014;2:e176; doi: 10.1097/GOX.000000000000117; Published online 24 June 2014.)

CASE REPORT

A 12-year-old Asian boy with left hemifacial microsomia and associated left microtia underwent a first-stage Nagata-type reconstruction of the left ear with right rib cartilage graft. Before the surgery, the patient had unremarkable range of motion in the neck with no head-and-neck pain, infection, or mass. Surgical positioning was typical for microtia reconstruction with a shoulder roll, the head prepped

and draped fully, and mostly turned to the right on an Acton gel donut. Postoperatively, the patient presented on the ward with a stiff neck, with head tilted and turned to the right side, and limited voluntary mobility (Fig. 1). It was felt to be a protective response to pain and increased pain medication, and mobilization was encouraged. The stiffness persisted even after discharge home. A physiotherapist was consulted who suspected Grisel's syndrome. A computed tomography (CT) scan revealed a C1–C2 subluxation and Grisel's syndrome was confirmed (Fig. 2). Treatment with a course of anti-inflammatories, relaxed neck positioning, and collar use proved unsuccessful, and the patient was admitted to hospital for halter traction and splinting. Two months after the initial onset of the torticollis, the torticollis slowly resolved.

A 3-month postsurgical CT scan demonstrated some persistent dysplasia of the anterosuperior surface of the left C2 lateral mass, potentially facilitating anterior subluxation of the C1 lateral mass (Fig. 3). It was unclear if the change was a congenital asymmetry or secondarily resulted from the prolonged subluxation.

Since the resolution of the torticollis, the patient has been followed for 2 years and has resumed full activities with no recurrence. The second stage of ear reconstruction has not been undertaken.

From the *School of Medicine, Faculty of Medicine, University of British Columbia, Vancouver, BC, Canada; †Division of Paediatric Plastic Surgery, BC Children's Hospital, Vancouver, BC, Canada; ‡Division of Paediatric Orthopaedics, Department of Orthopedics, University of British Columbia, Vancouver, BC, Canada; §Division of Paediatric Orthopaedics, BC Children's Hospital, Vancouver, BC, Canada; and ¶Division of Paediatric Plastic Surgery, Department of Surgery, University of British Columbia, Vancouver, BC, Canada.

Received for publication February 25, 2014; accepted April 11, 2014.

Copyright © 2014 The Authors. Published by Lippincott Williams & Wilkins on behalf of The American Society of Plastic Surgeons. PRS Global Open is a publication of the American Society of Plastic Surgeons. This is an open-access article distributed under the terms of the Creative Commons Attribution-NonCommercial-NoDerivatives 3.0 License, where it is permissible to download and share the work provided it is properly cited. The work cannot be changed in any way or used commercially.

DOI: 10.1097/GOX.000000000000117

Disclosure: The authors have no financial interest to declare in relation to the content of this article. The Article Processing Charge was paid for by the authors.

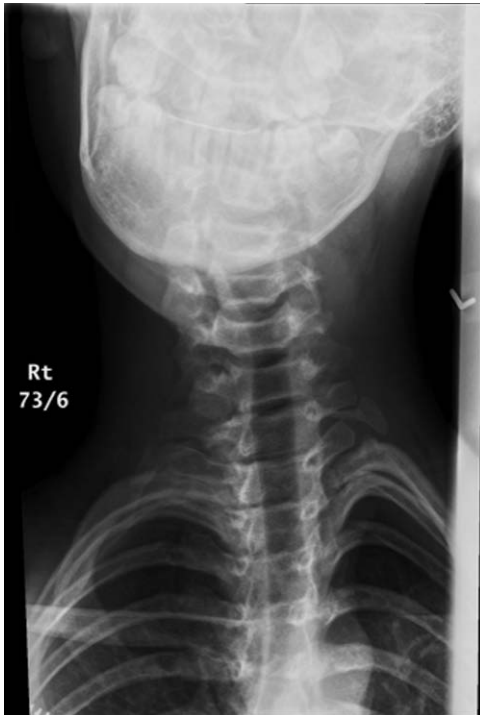

Fig. 1. X-ray showing the subject’s head position. With no neurological signs or peripheral nerve complaints, the patient retained full flexion and right-sided cervical rotation. Neck extension was limited to 20 degrees, and left cervical rotation did not go beyond midline.

DISCUSSION

The list of causes of acquired torticollis in children and infants is extensive: traumatic, infectious (retropharyngeal infection), neoplastic (intraspinous or posterior fossa tumors), neurologic, ocular (fourth nerve palsy head tilt), and medication-induced (antipsychotics). Although Grisel’s syndrome is most common in the pediatric otolaryngologic popula-

tion, due to its potential for permanent neurologic dysfunctions, paralysis, or death,^{1,2} all surgeons who operate in the craniofacial region should be familiar with it to ensure timely diagnosis and management.

Grisel’s syndrome is the nontraumatic subluxation of the C1–C2 joint.³ This syndrome was first described by Sir Charles Bell in 1830 and subsequently reported by Pierre Grisel in 1930.⁴ A review by Karkos et al⁵ revealed that the most common cause of Grisel’s syndrome is infection of the head and neck, which is associated with 48% of cases in their study, followed by surgery of the head and neck, associated with 31% of the cases.⁵ Among the various types of infections, upper respiratory tract infections accounted for 83% of cases, followed by retropharyngeal abscess and otitis media, at 11% and 4%, respectively.⁵ Of the head and neck operations, adenotonsillectomy was associated with 78% of the cases, whereas pharyngoplasty and otoplasty were associated with 15% and 2.5% of the cases observed.⁵

To date, the pathogenesis of Grisel’s syndrome is still unclear. Normally, the transverse ligament of the atlas contributes largely to the stability of the C1–C2 joint.¹ Anatomically directly adjacent to the pharynx, some feel pharyngeal inflammation may mediate a laxity of this ligament and also provide a small amount of intra-articular inflammatory fluid that may act as a lubricant for the atlantoaxial joint to more easily sublux.⁴ Although there is less likely to be a firm skeletal block to reduction, strong muscle spasm maintains the subluxed position.¹ Currently, the most accepted theory is that the pharynx and upper respiratory tract share lymphatic drainage with the C1–C2 joint, and any inflammatory process may therefore lead to C1–C2 joint instability.^{1,4–6} In our noninflammatory surgical case, and the reported surgical cases related to nonpharyngeal pathology,




Fig. 2. 3D model from a CT of vertebrae C1–C3. Right and left view.

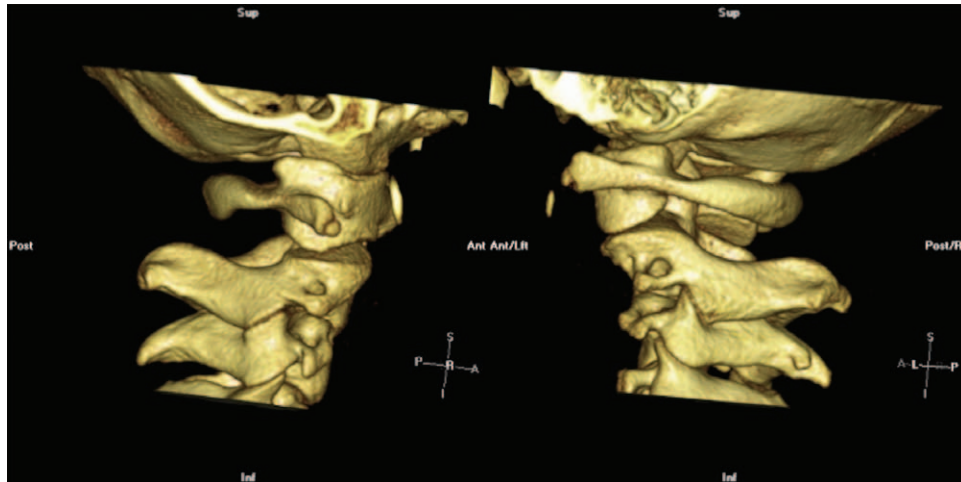

Fig. 3. 3D CT images of C1–C3 after correction with halter traction and splinting. Right and left view. Note asymmetry of C2 lateral masses.

preexisting cervical skeletal anomalies and/or aggressive rotational positioning must be considered potential causes. In our case, we did not note any difficulty achieving intraoperative positioning or operate in extreme rotation.

The diagnosis of Grisel's syndrome is made upon mostly on clinical assessment and confirmed with radiologic imaging. Grisel's syndrome usually presents as painful torticollis.³ Rotation of the neck is limited and passive attempts to reposition can cause pain.³ Due to the potentially serious complications of Grisel's syndrome, early radiographic imaging and management is crucial. A transoral x-ray can be diagnostic but is not usually included in our standard c-spine views. The anteroposterior view would reveal the asymmetry between the C1–C2 facet joints, whereas the lateral view can sometimes show an increased distance in the atlantodens interval^{7,8} or show a relative oblique tilt to the C1 vertebral ring (Fig. 2). CT can provide 3D evidence of rotator subluxation of the C1–C2 joint.^{7,9}

There is currently no consensus treatment for Grisel's syndrome,⁴ but the first line of treatment is generally conservative, including antibiotics and anti-inflammatories. In some cases, muscle relaxants and a cervical collar may also be used.⁴ In patients who do not improve through nonoperative management, gentle constant traction and/or repositioning under general anesthesia and/or halo fixation may be necessary.^{4,10} In cases where reductions cannot be achieved in that fashion, or where subluxations recur, surgical options, including arthrodesis,² may be considered.⁴

CONCLUSIONS

Grisel's syndrome is a cause of acquired torticollis in children and infants and is most often encoun-

tered in otolaryngological practices. It is rare enough that most nonotolaryngologists will be unaware of the diagnosis; however, all surgeons who operate on the head and neck regions of pediatric patients may encounter such condition. Due to the potentially severe consequences that may arise without timely diagnosis and management, it is crucial for practitioners to be familiar with the diagnosis and hold a high index of suspicion to recognize, diagnose, and manage this condition.

Cynthia Verchere, MD, FRCSC

Division of Plastic Surgery
BC Children's Hospital
University of British Columbia
Room K3-131
P.O. Box 150
4480 Oak Street
Vancouver, BC V6H 3V4
Canada
E-mail: cverchere@cw.bc.ca

REFERENCES

1. Rinaldo A, Mondin V, Suárez C, et al. Grisel's syndrome in head and neck practice. *Oral Oncol.* 2005;41:966–970.
2. Fielding JW, Hawkins RJ, Hensinger RN, et al. Atlantoaxial rotary deformities. *Orthop Clin North Am.* 1978;9:955–967.
3. Dagtekin A, Kara E, Vayisoglu Y, et al. The importance of early diagnosis and appropriate treatment in Grisel's syndrome: report of two cases. *Turk Neurosurg.* 2011;21:680–684.
4. Osiro S, Tiwari KJ, Matusz P, et al. Grisel's syndrome: a comprehensive review with focus on pathogenesis, natural history, and current treatment options. *Childs Nerv Syst.* 2012;28:821–825.
5. Karkos PD, Benton J, Leong SC, et al. Grisel's syndrome in otolaryngology: a systematic review. *Int J Pediatr Otorhinolaryngol.* 2007;71:1823–1827.
6. Parke WW, Rothman RH, Brown MD. The pharyngovertebral veins: an anatomical rationale for Grisel's syndrome. *J Bone Joint Surg Am.* 1984;66:568–574.

7. Yu KK, White DR, Weissler MC, et al. Nontraumatic atlantoaxial subluxation (Grisel syndrome): a rare complication of otolaryngological procedures. *Laryngoscope* 2003;113:1047–1049.
8. Salpietro V, Polizzi A, Granata F, et al. Upper respiratory tract infection and torticollis in children: differential diagnosis of Grisel's syndrome. *Clin Neuroradiol*. 2012;22:351–353.
9. Pilge H, Prodinger PM, Bürklein D, et al. Nontraumatic subluxation of the atlanto-axial joint as rare form of acquired torticollis: diagnosis and clinical features of the Grisel's syndrome. *Spine (Phila Pa 1976)*. 2011;36:E747–E751.
10. Deichmueller CM, Welkoborsky HJ. Grisel's syndrome—A rare complication following “small” operations and infections in the ENT region. *Eur Arch Otorhinolaryngol*. 2010;267:1467–1473.