

Case Report

An elective detection of an Amyand's hernia with an adhesive caecum to the sac: Report of a rare case

Ilker Sengul¹, Demet Sengul², Duygu Aribas³

¹Department of General Surgery, Giresun University Faculty of Medicine, 28100 Giresun, Turkey.

²Department of Pathology, Prof. Dr. A. Ilhan Ozdemir State Hospital, 28100 Giresun, Turkey.

³The Clinic of Pathology, Sistem Laboratories, Demetevler, Ankara, Turkey.

Citation: Sengul I, Sengul D, Aribas D. An elective detection of an Amyand's hernia with an adhesive caecum to the sac: Report of a rare case. *North Am J Med Sci* 2011; 3: 391-393.

doi: 10.4297/najms.2011.3391

Abstract

Context: Existence of non-inflamed or inflamed vermiform appendix in an inguinal hernia is named Amyand's hernia in honor to the surgeon Claudius Amyand who successfully performed first perforated appendicitis. **Case Report:** A 69-year-old Turkish male patient with a slight right groin pain and swelling was presented to our clinic, and found to have a slightly tender and reducible right inguinal hernia. He underwent surgery under general anesthesia, and a adhesive caecum and an inflamed appendix were explored within the hernia sac. Adhesions were divided by sharp dissection and appendectomy was performed. After carrying out a Lichtenstein hernioplasty, a broad-spectrum antibiotic was postoperatively admitted for 3 days. He recovered uneventfully, and neither complication nor recurrence was detected during 52 months of follow-up. **Conclusions:** Although occurrence of an appendicitis in an inguinal hernia is rare, a surgeon should be vigilant for facing with it even in elective cases. Treatment can be provided only surgically, but surgical treatment is not standard except from appendectomy. In our opinion, application of mesh hernia repair should depend on the degree of inflammation of appendix and the presence of incarceration of hernia sac with a suitable antibiotic admission for 3-5 days postoperatively.

Keywords: Hernia, inguinal, appendicitis.

Correspondence to: Ilker Sengul, MD, Assistant Professor of General Surgery, Vice Dean, The Founder Chairman of Department of General Surgery, Deanery of Giresun University Faculty of Medicine, 28100 Giresun, Turkey. Tel.: +90 454 3101000, Fax: +90 4542140247, E-mail: dr.ilker52@mynet.com

Introduction

Claudius Amyand (1660-1740), also known as "surgeon-in-ordinary" or "sergeant surgeon" to King George II of England, defined an acutely inflamed appendix located in the inguinal canal in an 11-year-old boy on 6 December 1735. Then he treated himself by an appendectomy, which is the first recorded successful appendectomy in the World. Actually, he described an appendicitis in the inguinal canal (later, it is named as Amyand's hernia), and performed first successful appendectomy at the same time in 1735. The surgeon defined the operation as "most complicated and perplexing", and pathology revealed a chronically inflamed appendix included within the inguinal hernia sac and perforated by a previously swallowed pin. After the

successful appendectomy, "so much of hernia bag had been detached from the skin". The boy recovered uneventfully and "discharged with a truss, he was ordered to wear it for some time, to confirm cure." This case was published in Philosophical Transactions of the Royal Society of London [1].

In the present report, we purposed to present a rare case of inguinal hernia consisting the appendicitis and adhesive caecum in a 69-year-old man.

Case Report

A 69-year-old Turkish man presented with slight right groin pain and swelling, but did not complain about nausea, vomiting or abdominal pain. On the physical

examination, a slightly tender and reducible right inguinal hernia was detected. It was no abnormality except for a minimal tenderness at the right lower quadrant of the abdomen. The mobile bowel was observed inside the right inguinal channel and the scrotum, but no any mass or abnormality was detected in the testes in the preoperative scrotal ultrasonography. At the operation, an adhesive caecum and an inflamed appendix with appendiceal fecalith were explored within the hernia sac (Figure 1).

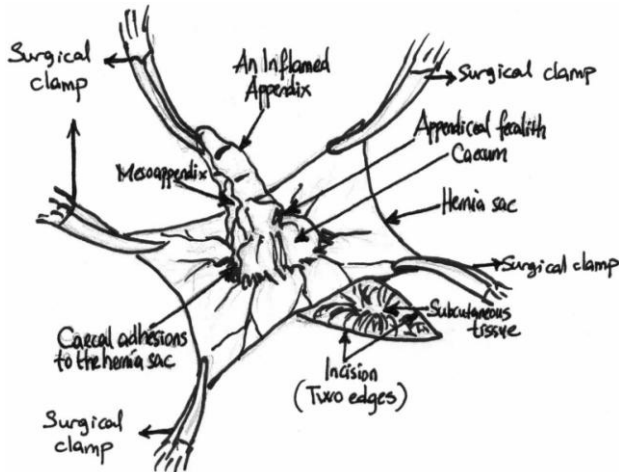


Fig. 1 A drawn image of an adhesive caecum and an inflamed appendix with an appendiceal fecalith within the sac of right inguinal hernia after splitting the sac perioperatively.

Adhesions were divided by sharp dissection and the testis was left in the scrotum. Then an appendectomy was performed, and the remnant stump and caecum were brought back into the abdominal cavity. The hernia repair was achieved by carrying out a Lichtenstein hernioplasty using Prolene mesh and Prolene sutures. A broad-spectrum antibiotic was postoperatively admitted for 3 days. The patient was discharged with no complaints, and recovered uneventfully. Microscopic examinations revealed that the mucosal and submucosal parts were in normal histological appearance.

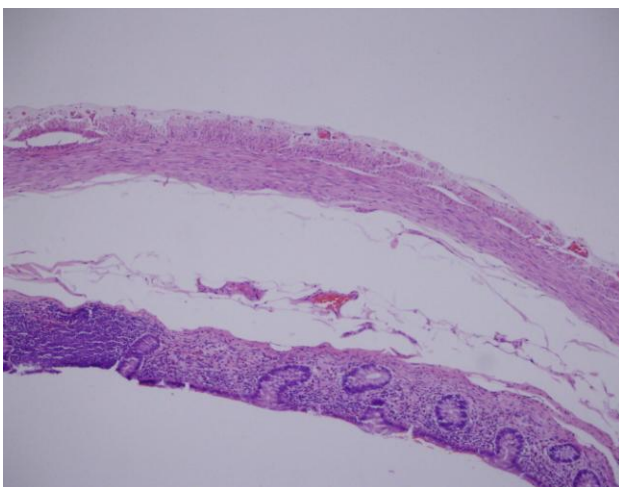


Fig. 2 Although mucosal and submucosal part was in normal histological appearance, congestion and focal lenfocytic infiltration was seen in serosal portion of the appendix (Haematoxylin & Eosin, Original magnification, 100x).

However, the congestion and focal lenfocytic infiltration was seen in serosal portion of the appendix (Figure 2). Additionally, the findings of congestion were histopathologically detected in the hernia sac. Neither complication nor recurrence of hernia was detected during 52 months follow-up.

Discussion

The probability of a person to have the disease of acute appendicitis in her/his life is 8%, and occurrence of an asymptomatic appendix within an hernia sac is a rare entity accounting for 1%. However, the incidence of an acute appendicitis in a sac of inguinal hernia is an even less common, it is about 0.13% [2-4]. Many individuals having an inguinal hernia are reported as asymptomatic or minimally symptomatic [5]. Ryan [4] reported in 1937 that 11 of 8692 cases (0.13 %) of appendicitis were located in external hernia sacs. Thomas et al [6] reported only 7 acute appendicitis occurring in an external hernia sac during 8 years. The average age was calculated as 69.4. The age of our case was also 69. However, ages of that kind of cases ranges from 3 weeks to 88 years [7]. The incidence of acute appendicitis in an hernia sac is reported between 0.008% and 1% in the English-language literature [8, 9].

An inflamed appendix is an emergency condition. In the case of Amyand's hernia, diagnosis is almost always made intraoperatively [7]. Nonetheless, to our knowledge, Weber [10] is the unique surgeon who suggested that he was detected it preoperatively. In the evaluation of groins and scrotum, ultrasonography may not be enough alone. Similarly, ultrasound imaging did not give additional information preoperatively except for the exhibition of the sliding hernia in the present case. Strangulated hernia, strangulated omentocele, acute hydrocele, Richter's hernia, testicular tumor with hemorrhage, inguinal adenitis, and epididymitis may be concerned in the differential diagnosis of Amyand's hernia. Appendectomy through the herniotomy with primary hernia repair using the same incision is used for the treatment of hernial appendicitis [11]. In the presence of appendix vermiform in the sac of hernia, the mesh hernia repair without appendectomy is recommended by most authors [12]. However, in case of inflamed appendix in the sac, appendectomy without mesh hernia repair is suggested by some authors [11, 13]. Nonetheless, some prefer to perform both appendectomy and mesh hernia repair in the treatment of inflamed appendix in the inguinal hernia sac, and they recommended the intravenous broad-spectrum antibiotics for at least 3-5 days to prevent a possible mesh infection [14, 15]. Additionally, Torino et al [14] irrigated the inguinal area with antibiotics. In our case, even if the appendix was congested and inflamed with an adhesive caecum inside the sac, the sac was not incarcerated and no any abscess was observed. Therefore, we performed an appendectomy with mesh hernia repair, did not irrigate the inguinal area with antibiotics, and postoperatively admitted an intravenous broad-spectrum antibiotic for 3 days.

The appendicitis within an Amyand's hernia is rare, but misdiagnosis is not seldom when it occurs. Although it can be treated by surgery only, surgical treatment is not standard except from appendectomy. In our opinion, application of mesh hernia repair should depend on the degree of inflammation of appendix and the presence of incarceration of hernia sac. Awareness of this condition would be helpful in the preoperative diagnosis of both exigent and elective cases.

Acknowledgement

No funding was used in the present work. All authors contributed equally and involved in writing the paper, and finally approved the submitted and published versions without any conflict of interest.

References

1. Amyand C. Of an inguinal rupture, within a pin in the appendix caeci, incrusted with Stone, and some observations on wounds in the guts. *Philos Transact R Soc Lon* 1736; 39: 329-336.
2. Addiss DG, Shaffer N, Fowler BS, Tauxe RV. The epidemiology of appendicitis and appendectomy in the United States. *Am J Epidemiol* 1990; 132: 910-925.
3. House MG, Goldin SB, Chen H. Perforated Amyand's hernia. *South Med J* 2001;94:496-498.
4. Ryan WJ. Hernia of the vermiform appendix. *Ann Surg* 1937;106:135-139.
5. Fitzgibbons RJ Jr, Giobbie-Hurder A, Gibbs JO, et al. Watchful waiting vs. repair of inguinal hernia in minimally symptomatic men: a randomized clinical trial. *JAMA* 2006;295:285-292.
6. Thomas WE, Wowles KD, Williamson RC. Appendicitis in external hernia. *Ann R Coll Surg Engl* 1982; 64:121-122.
7. Cunha HA, Sugahara RD, Castilho MV. Amyand's hernia. *Rev Col Bras Cir* 2009; 36:279-280.
8. Carey LC. Acute appendicitis occurring in hernias: a report of 10 cases. *Surgery* 1967;61:236-238.
9. D'Alia C, Lo Schiavo MG, Tonante A, et al. Amyand's hernia: case report and review of the literature. *Hernia* 2003;7:89-91.
10. Weber RV, Hunt ZC, Kraal JG. Amyand's hernia: Etiologic and therapeutic implications of the two complications. *Surg Rounds* 1999;22:552-556.
11. Logan MT, Nottingham JM. Amyand's hernia: a case report of an incarcerated and perforated appendix within an inguinal hernia and review of the literature. *Am Surg* 2001;67:628-629.
12. Sharma H, Gupta A, Shekhawat NS, Memon B, Memon MA. Amyand's hernia: a report of 18 consecutive patients over a 15-year period. *Hernia* 2007; 11:31-35.
13. Kueper MA, Kirschniak A, Ladurner R, Granderath FA, Konigsrainer A. Incarcerated recurrent inguinal hernia with covered and perforated appendicitis and periappendicular abscess: case report and review of the literature. *Hernia* 2007;11:189-191.
14. Torino G, Campisi C, Testa A, Baldassarre E, Valenti G. Prosthetic repair of a perforated Amyand's hernia: hazardous or feasible? *Hernia* 2007;11:551-552; author reply 553-554.
15. Chatzimavroudis G, Papaziogas B, Koutelidakis I, et al. The role of prosthetic repair in the treatment of an incarcerated recurrent inguinal hernia with acute appendicitis (inflamed Amyand's hernia). *Hernia* 2009; 13:335-336; author reply 337.