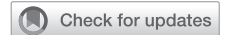

See Article page 324.



Commentary: Tricuspid regurgitation in hypoplastic left heart syndrome: Getting beyond a finger in the dyke

William M. DeCampli, MD, PhD

In this issue of *JTCVS Open*, Ross and coworkers¹ examined the mechanics of the tricuspid valve annulus in 8 infants with hypoplastic left heart syndrome (HLHS) and compared it with that of 4 normal newborns. Among other findings, annular circumference in patients with HLHS was 20% to 30% larger and anteroposterior diameter 35% to 45% greater than in normal hearts. Normal annuli remained elliptical throughout the cardiac cycle, with major axis in the septal–lateral direction. In HLHS, the major axis was instead in the anteroposterior direction and decreased during isovolumic contraction, ie, the annulus became more circular. The annulus was flatter in mid-diastole and more “bent” (off-plane) at valve closure.

Significant tricuspid regurgitation (TR) develops in approximately 30% of HLHS. Using conventional imaging, the most common reported preoperative pathology is anterior leaflet prolapse, followed by septal leaflet tethering, septal leaflet prolapse, annular dilation, and cleft anterior leaflet.^{2,3} Effective repair has been challenging. Combining the results from 3 studies published within the past year, the unadjusted incidence of moderate-to-severe TR after valvuloplasty was 52 of 96 patients (54%).²⁻⁴ At 10 years, transplant-free survival is lowest (38%) when valvuloplasty is performed at stage 1 for single-ventricle defects.⁵

From the Division of Pediatric Cardiovascular Surgery, Arnold Palmer Hospital for Children; and Department of Clinical Sciences, University of Central Florida College of Medicine, Orlando, Fla.

Disclosures: The author reported no conflicts of interest.

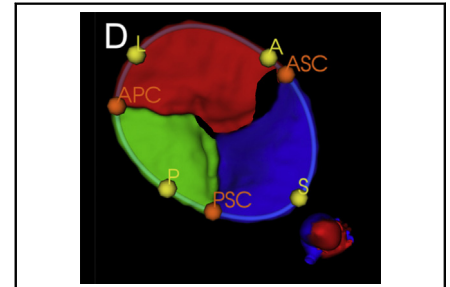
The *Journal* policy requires editors and reviewers to disclose conflicts of interest and to decline handling or reviewing manuscripts for which they may have a conflict of interest. The editors and reviewers of this article have no conflicts of interest.

Received for publication Feb 27, 2022; revisions received Feb 27, 2022; accepted for publication April 8, 2022; available ahead of print May 7, 2022.

Address for reprints: William M. DeCampli, MD, PhD, Arnold Palmer Hospital for Children, 92 W. Miller St, Orlando, FL 32806 (E-mail: William.decampli@orlandohealth.com).

JTCVS Open 2022;10:340-1
2666-2736

Copyright © 2022 The Author(s). Published by Elsevier Inc. on behalf of The American Association for Thoracic Surgery. This is an open access article under the CC BY-NC-ND license (<http://creativecommons.org/licenses/by-nc-nd/4.0/>).
<https://doi.org/10.1016/j.xjon.2022.04.004>



Reconstructed tricuspid valve image in HLHS: Hope for better surgical planning.

CENTRAL MESSAGE

Tricuspid regurgitation is significantly morbid in hypoplastic left heart syndrome. Advanced image reconstruction may facilitate development of better surgical techniques to yield a durable repair.

The pathophysiologic pathway to TR likely begins in utero, because some babies with HLHS are born with TR. In utero, the right ventricle (RV) already has a 50% excess volume load that lasts for months. After birth, when pulmonary vascular resistance drops, the volume load is 2 to 3 times normal. After the stage 1 operation, several more months pass with the volume and pressure load. (The pressure load likely contributes but not dominantly, ie, patients with tetralogy normally don't get progressive TR). TR itself adds more to the volume load; so does RV dysfunction. The volume load deforms the RV geometry, dilates the annulus, changes its shape, and alters papillary muscle orientations. While biological adaptation has been shown to occur in the mitral valve, it is unclear whether the tricuspid valve in HLHS does so and does so sufficiently.⁶ While the stage II operation removes much of the volume load, by then “the cat's out of the bag,” ie, some of the changes are permanent. Simplistic procedures such as posterior annuloplasty and commissuroplasty often do not yield a lasting result.

The current work by Ross and coworkers adds important information to the behavior of the tricuspid apparatus in infants with HLHS. For image acquisition, they used “4-dimensional” echocardiography, then performed manual segmentation at 5 time points to reconstruct the time-related shape of the annulus. Similar studies had been performed in

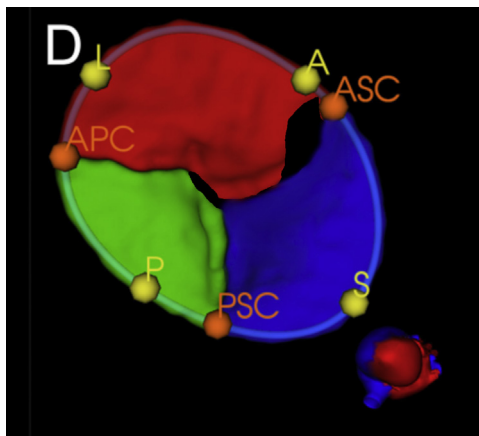


FIGURE 1. Three-dimensional model of a tricuspid valve segmented using the fully convoluted network, a machine-learning technique, modified to illustrate areas of regurgitation. Small heart image shows view direction. L, Apical; A, anterior, P, posterior, C, commissure; S, septal. Adapted from Figure 1D of Herz and colleagues.⁸ Used with permission.

the past, but at only 1 or 2 time points.⁷ The current study effectively shows us how the annulus behaves throughout the cardiac cycle. The process is time-intensive and was limited to the annulus. As mentioned by the authors, a study published just months ago accelerates the workflow using a deep learning technique (fully convolutional network) and reconstructs individual leaflet anatomy (Figure 1).⁸ Once this technique is improved and extended to analyzing the

subvalvar apparatus and RV, one may hope to use the findings to design surgical techniques to intelligently refashion the tricuspid valve in HLHS, rather than just putting a finger in the dyke.

References

1. Ross CJ, Trimble EJ, Johnson EL, Baumwart R, Jolley MA, Mir A, et al. A pilot investigation of the tricuspid valve annulus in newborns with hypoplastic left heart syndrome. *J Thorac Cardiovasc Surg Open*. 2022;10:324-39.
2. Mah K, Khoo NS, Martin BJ, Maruyama M, Alvarez S, Rebeyka IM, et al. Insights from 3D echocardiography in hypoplastic left heart syndrome patients undergoing TV repair. *Pediatr Cardiol*. 2022;43:735-43. <https://doi.org/10.1007/s00246-021-02780-1>
3. Ono M, Mayr B, Burri M, Piber N, Rohlig C, Strbad M, et al. Tricuspid valve repair in children with hypoplastic left heart syndrome: impact of timing and mechanism on outcome. *Eur J Cardiothorac Surg*. 2020;57:1083-90.
4. Wamala I, Friedman KG, Saeed MY, Gauvreau K, Gellis L, Borisuk M, et al. Tricuspid valve repair concomitant with the Norwood operation among babies with hypoplastic left heart syndrome. *Eur J Cardiothorac Surg*. February 13, 2022 [Epub ahead of print].
5. Sinha R, Altin HF, McCracken C, Well A, Rosenblum J, Kanter K, et al. Effect of atrioventricular valve repair on multistage palliation results of single-ventricle defects. *Ann Thorac Surg*. 2021;111:662-70.
6. Chaput M, Handschumacher MD, Tournoux F, Hua L, Guerrero JL, Vlahakes GJ, et al. Mitral leaflet adaptation to ventricular remodeling: occurrence and adequacy in patients with functional mitral regurgitation. *Circulation*. 2008;118:845-52.
7. Kutty S, Colen T, Thompson RB, Tham E, Li L, Vigarnsorn C, et al. Tricuspid regurgitation in hypoplastic left heart syndrome: mechanistic insights from 3-dimensional echocardiography and relationship with outcomes. *Circ Cardiovasc Imaging*. 2014;7:765-72.
8. Herz C, Pace DF, Nam HH, Lasso A, Dinh LA, Flynn M, et al. Segmentation of tricuspid valve leaflets from transthoracic 3D echocardiograms of children with hypoplastic left heart syndrome using deep learning. *Front Cardiovasc Med*. 2021;8:1-12. <https://doi.org/10.3389/fcvm.2021.735587>