



## Case Report

# Lupus Miliaris Disseminatus Faciei: A Case Report and Brief Literature Review

Aslı Aksu Çerman,<sup>1</sup> Ezgi Aktaş Karabay,<sup>1,\*</sup> Özben Yalçın,<sup>2</sup> Ilknur Kıvanç Altunay<sup>1</sup>

<sup>1</sup>Department of Dermatology and Venereology, Sisli Hamidiye Etfal Training and Research Hospital, Istanbul, Turkey

<sup>2</sup>Department of Medical Pathology, Sisli Hamidiye Etfal Training and Research Hospital, Istanbul, Turkey

\*Current affiliation: Department of Dermatology and Venereology, Bahcesehir University, Faculty of Medicine, Istanbul, Turkey

### Abstract

Lupus miliaris disseminatus faciei (LMDF) is a rarely seen, granulomatous disease of the face with an unknown etiology. Clinically, the disease is characterized by monomorphic, reddish-brown, dome-shaped papules symmetrically distributed on the face. Histopathologically, a perifollicular caseating granuloma is the hallmark.

A 20-year-old male patient was referred to our outpatient clinic with multiple papules distributed on his face, and he was diagnosed with LMDF based on histopathological examination. The patient was unresponsive to the oral tetracycline treatment; however, he was successfully treated with systemic dapsone and topical tacrolimus. This is a rare case of LMDF, which showed rapid improvement with dapsone therapy.

**Keywords:** Dapsone; granuloma; lupus miliaris disseminatus faciei.

Please cite this article as "Aksu Çerman A., Aktaş Karabay E., Yalçın Ö., Kıvanç Altunay İ. Lupus Miliaris Disseminatus Faciei: A Case Report and Brief Literature Review. Med Bull Sisli Etfal Hosp 2018;52(2):142–144".

Lupus miliaris disseminatus faciei (LMDF), first described by Fox et al.<sup>[1]</sup> in 1877, is a rarely seen dermatosis, and approximately 200 cases have been reported in the literature so far.<sup>[2]</sup> Previously mycobacterium tuberculosis and later on demodex folliculorum were considered as the etiological agents of caseification necrosis in LMDF papules; however, both agents could not be demonstrated in granulomas that ruled out the validity of these hypotheses.<sup>[3]</sup>

In young adults, LMDF, which is mostly seen on face and less frequently on the extrafacial regions, tends to be a self-limiting pathology.<sup>[4]</sup>

### Case Report

A 20-year-old male patient was referred to our outpatient clinic with asymptomatic rashes persisting for 2 months.

The patient had no history of any known disease or drug use. On dermatological examination, monomorphic, solid, reddish-brown papular lesions with a smooth surface were observed on the nasolabial sulci and right infraorbital region and more intensely on the perioral region (Fig. 1). The patient had no subjective complaints such as pruritus, pain, and burning sensation. Histopathological examination of the biopsy material excised from the papule on his chin revealed superficial hyperkeratosis; mild dermal acanthosis; dermal granulomas; an area of focal caseification necrosis surrounded by epithelioid histiocytes, multinuclear giant cells, and lymphocytes; and a perivascular, perifollicular, and interstitial lymphocytic infiltration area (Fig. 2). Ziehl–Neelsen or Periodic acid–Schiff (PAS) staining could not demonstrate any fungal or mycobacterial agents.

**Address for correspondence:** Ezgi Aktaş Karabay, MD. Department of Dermatology and Venereology, Sisli Hamidiye Etfal Training and Research Hospital, Istanbul, Turkey

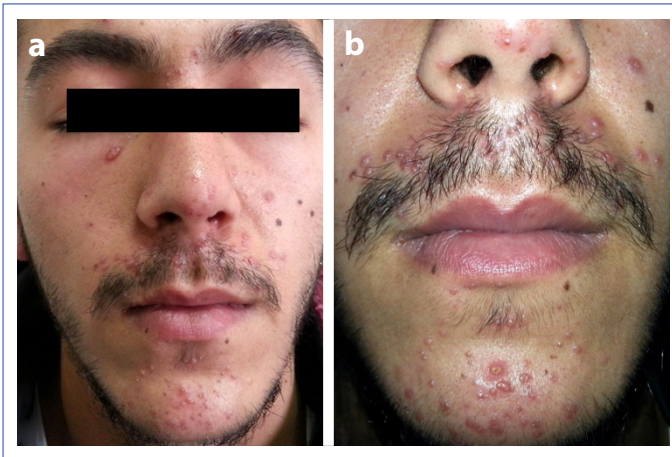
**Phone:** +90 505 585 35 61 **E-mail:** ezgiii.aktas@gmail.com

**Submitted Date:** February 08, 2017 **Accepted Date:** April 03, 2017 **Available Online Date:** May 28, 2018

©Copyright 2018 by The Medical Bulletin of Sisli Etfal Hospital - Available online at [www.sislietfalthip.org](http://www.sislietfalthip.org)

This is an open access article under the CC BY-NC-ND license (<http://creativecommons.org/licenses/by-nc/4.0/>).





**Figure 1.** Lupus miliaris disseminatus faciei. **(a)** Multiple, reddish-brown papules can be seen on the patient's face. **(b)** Papular lesions were more intensely seen on the perioral region.

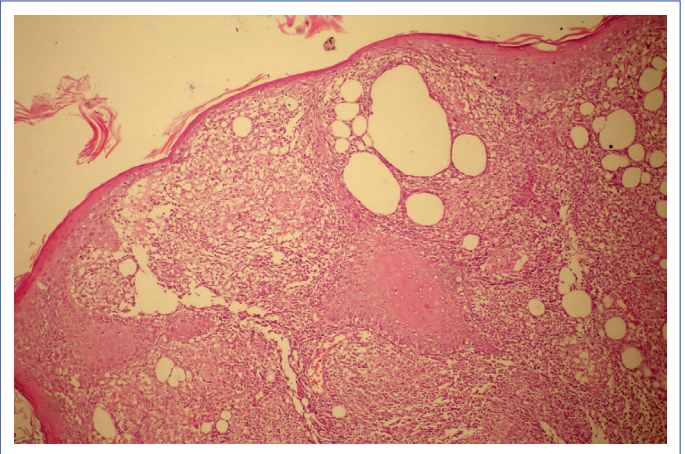
Complete blood counts and biochemical test results of the patient were within normal limits, and chest X-rays showed no abnormal findings. Based on clinical and histopathological findings, he was diagnosed with LMDF.

The patient was started on oral doxycycline at daily doses of 200 mg and did not show any improvement at the end of the first month. After 1 month, the lesions markedly regressed with treatment with systemic dapsone (50 mg/day) and topical tacrolimus.

## Discussion

LMDF is a granulomatous, inflammatory chronic disease, which is mostly seen in young adults and affects both sexes equally.<sup>[5, 6]</sup> It particularly affects the central part of the face, and multiple, reddish-yellow or reddish-brown, solid papules are frequently seen on the malar, submandibular, and periorifacial regions. The eyelid is typically involved.<sup>[2, 7]</sup> In cases with LMDF coursing with extrafacial involvement, the axilla, shoulders, arms, hands, neck, legs, and inguinal region are frequently affected.<sup>[8]</sup> Also in our case, the LMDF lesions were localized on the face, chin, nasolabial sulci, and infraorbital region and more intensely on the perioral region. Although the histopathological findings may change according to the stage of the lesion,<sup>[9]</sup> perifollicular granulomas formed by epithelioid cells with a central caseification necrosis are characteristic features of LMDF. Typically, chronic infiltrates accompany the granulomas seen in the vicinity of adnexal structures.<sup>[7]</sup> Lymphoid tissue accumulation surrounding the giant cells, which may be contained in the granulomas, may be observed.<sup>[10]</sup>

For the etiopathogenesis of LMDF, various theories have been suggested; however, the most frequently accepted



**Figure 2.** Histopathological examination of the papule (HE;  $\times 100$ ).

one is that LMDF is a subtype of granulomatous rosacea.<sup>[11]</sup> In the differential diagnosis, sarcoidosis, nontuberculous mycobacterial infections, deep fungal infections, acne vulgaris, milia, and syringomas should be considered.<sup>[12]</sup>

Frequently, the lesions in LMDF, a self-limiting dermatosis, spontaneously regress within 12–24 months, leaving a scar tissue as a sequela.<sup>[9]</sup> For the management of LMDF, systemic (tetracycline, low-dose isotretinone, dapsone, corticosteroids, and immunosuppressive drugs) and topical (corticosteroids, tacrolimus, and psoralen combined with UV-A radiation) treatment alternatives are available.<sup>[9, 12]</sup> Treatment initiation at an early stage shortens the treatment duration and decreases scar formation.<sup>[6]</sup>

In our patient, who was refractory to doxycycline, a rapid response was obtained using systemic dapsone (50 mg/day) and topical tacrolimus. From the first month of the treatment, the lesions markedly regressed, and scar formation was seen after healing of the lesions. Our patient with rarely seen LMDF provided a rapid response to dapsone; therefore, we emphasize that dapsone and topical calcineurin inhibitors should be considered among treatment alternatives.

## Disclosures

**Informed consent:** Written informed consent was obtained from the patient for the publication of the case report and the accompanying images.

**Peer-review:** Externally peer-reviewed.

**Conflict of Interest:** None declared.

**Authorship contributions:** Concept – A.A.Ç., E.A.K.; Design – A.A.Ç.; Supervision – İ.K.A.; Materials – A.A.Ç., E.A.K.; Data collection &/or processing – A.A.Ç., E.A.K., Ö.Y.; Analysis and/or interpretation – E.A.K., Ö.Y.; Literature search – E.A.K.; Writing – E.A.K.; Critical review – A.A.Ç.

## References

1. Fox T. Disseminated follicular lupus (simulating acne). *Lancet* 1878;112:75–6.
2. Esteves T, Faria A, Alves R, Marot J, Viana I, Vale E. Lupus miliaris disseminatus faciei: a case report. *Dermatol Online J* 2010;16:10.
3. Rocas D, Kanitakis J. Lupus miliaris disseminatus faciei: report of a new case and brief literature review. *Dermatol Online J* 2013;19:4.
4. Koike Y, Hatamochi A, Koyano S, Namikawa H, Hamasaki Y, Yamazaki S. Lupus miliaris disseminatus faciei successfully treated with tranilast: report of two cases. *J Dermatol* 2011;38:588–92.
5. Dekio S, Jidoi J, Imaoka C. Lupus miliaris disseminatus faciei- report of a case in an elderly woman. *Clin Exp Dermatol* 1991;16:295–6.
6. Gupta D, Dewan SP, Kaur A, Malhotra SK, Kaur S, Gambir ML. Lupus miliaris disseminatus faciei. *Indian J Dermatol* 1996;62:371–2.
7. Sehgal VN, Srivastava G, Aggarwal AK, Belum VR, Sharma S. Lupus miliaris disseminatus faciei. Part I: Significance of histopathologic undertones in diagnosis. *Skinmed* 2005;4:151–6.
8. Sehgal VN, Shrivastava G, Aggarwal AK, Reddy V, Sharma S. Lupus Miliaris Disseminatus Faciei Part II: An Overview. *Skinmed* 2005;4:234–8.
9. Al-Mutairi NA. Nosology and therapeutic options for lupus miliaris disseminatus faciei. *J Dermatol* 2011;38:864–73.
10. Hillen U, Schröter S, Denisjuk N, Jansen T, Grabbe S. Axillary acne agminata (lupus miliaris disseminatus faciei with axillary involvement). *J Dtsch Dermatol Ges* 2006;4:858–60.
11. Tokunaga H, Okuyama R, Tagami H, Aiba S. Intramuscular Triamcinolone Acetonide for Lupus Miliaris Disseminatus Faciei. *Acta Derm Venereol* 2007;87:451–2.
12. Amiruddin D, Mii S, Fujimura T, Katsuoka K. Clinical evaluation of 35 cases of lupus miliaris disseminatus faciei. *J Dermatol* 2011;38:618–20.