

Case Report

Stimulus-induced myoclonus treated effectively with clonazepam in genetically confirmed Coffin–Lowry syndrome[☆]Elif Acar Arslan^{a,*}, Serdar Ceylaner^b, Güzide Turanlı^c^a Department of Pediatric Neurology, Hacettepe University Children's Hospital, Ankara, Turkey^b Department of Molecular Biology and Genetics, InterGen Genetics Center, Ankara, Turkey^c Department of Pediatric Neurology, Medipol University Medical School of Medicine, Istanbul, Turkey

ARTICLE INFO

Article history:

Received 27 September 2014

Accepted 30 September 2014

Available online 25 November 2014

Keywords:

Clonazepam

Coffin–Lowry syndrome

Stimulus-induced myoclonus

ABSTRACT

Purpose: Coffin–Lowry syndrome (CLS) is a rare X-linked semidominant syndromic genetic disorder that is characterized by typical facial and radiologic findings, psychomotor and growth retardation, and various skeletal anomalies. A distinctive paroxysmal disorder called stimulus-bound myoclonus is clinically heterogeneous and is generally characterized by a sudden loss of muscle tone that is regained within a few seconds and is induced by sudden auditory or tactile stimulus. As the pathophysiology of stimulus-induced drop episodes (SIDEs) is not well understood, there is no definite therapy for those episodes.

Methods: We report a 15-year-old female with stimulus-induced drop episodes occurring many times a day that resulted in failure to perform her daily activities. Because her SIDEs were misdiagnosed as atonic seizures, she was treated with several antiepileptic drugs, including valproic acid, levetiracetam, lamotrigine, primidone, carbamazepine, and clobazam.

Results: We realized that her clinical and radiological findings, together with SIDEs, are compatible with Coffin–Lowry syndrome. All of her medications were discontinued following the diagnosis of SIDE, and she was started on clonazepam. After treatment, she became more independent and was able to perform her daily activities. Subsequently, her episodes decreased from 3 times a day to 1–2 times a month. Sodium oxybate and fluoxetine were added to the treatment protocol without remarkable improvement. Her genetic analysis revealed a heterozygous variation of CLS.

Conclusion: We conclude that SIDE should be included in a differential diagnosis of epileptic seizures in patients with CLS and that clonazepam is an effective choice in the treatment of SIDEs.

© 2014 The Authors. Published by Elsevier Inc. This is an open access article under the CC BY-NC-ND license (<http://creativecommons.org/licenses/by-nc-nd/3.0/>).

1. Introduction

Coffin–Lowry syndrome (CLS) is an X-linked semidominant inherited disease that was first described independently by Coffin et al. and Lowry et al. [1,2] Temtamy et al. were the first to recognize that the patients reported by Coffin and Lowry et al. [3] shared a similar course. The typical clinical features of this disease are mental retardation, facial dysmorphism, puffy proximal digits, tapering digits, and progressive skeletal changes [3]. This condition is very rare, with an estimated incidence of 1:50,000 to 1:1,000,000; approximately 70–80% of patients are sporadic cases [4]. Genetically, CLS is caused by 'loss-of-function mutations' in the Rps6ka3 gene encoding the protein

of ribosomal S6 kinase 2, a growth factor-regulated protein kinase. The disease is characterized by sudden drop attacks induced by sound or tactile stimulus without any loss of consciousness. These drop episodes last a very short time, as little as a few seconds [5]. Typical facial features include a prominent forehead, hypertelorism, a flat nasal bridge, and a downward-sloping palpebral fissure. In addition, affected individuals have severe mental retardation, short stature, pectus excavatum or carinatum deformity, thoracolumbar kyphosis/scoliosis, large and soft hands with tapering of the distal short and broad fingers and nails, hypotonia, and facial dysmorphism characterized by a coarse facial appearance [6]. 'Stimulus-induced drop episodes' (SIDEs) have been proposed as a name for these nonepileptic events in patients with CLS. The pathophysiology of SIDEs is not fully understood. Stimulus-induced drop episodes begin at the age range of 4 to 17 years, with a mean age at onset of around 8 years [5,7]. Many different agents are used in the treatment of SIDEs, including antiepileptic agents (e.g., lorazepam, clobazam, tiagabine, felbamate, valproic acid, and carbamazepine), selective serotonin reuptake inhibitors (e.g., fluoxetine and escitalopram), and tricyclics (e.g., clomipramine) [5–7]. Benzodiazepines are usually the drug of

[☆] This paper was presented as an oral presentation at the 14th Turkish Pediatric Society Scientific Congress, Kayseri, Turkey on May 2012.

* Corresponding author at: Clinic of Pediatric Neurology, Giresun Prof. Dr. A. İlhan Özdemir Hospital, Teyyaredüzü Mahallesi, PC: 28100 Giresun, Turkey. Tel.: +90 454 310 20 00; fax: +90 454 215 51 46.

E-mail address: elifacararslan@gmail.com (E.A. Arslan).

choice [5], as conventional antiepileptic drugs are often useless. We examine here a case of genetically confirmed Coffin–Lowry syndrome in a female patient with fully manifested clinical features and drop episodes, the latter of which partially responded to treatment with clonazepam.

2. Case report

A 15-year-old patient was admitted with a diagnosis of drug-resistant epilepsy. According to the history, the patient showed normal development until 10 years of age, except for falling a little behind her peers in school performance. At this age, she began to experience sudden-onset drop attacks stimulated by sound. Her prenatal history was unremarkable, and she had a healthy older sister. The other five subsequent pregnancies of her mother resulted in spontaneous abortion. Her mother and father are first-degree cousins. Her dysmorphic features included orbital hypertelorism, downward-slanting palpebral features, a flat nasal bridge, a prominent forehead, anteverted nares, thickening of the ala nasi and nasal septum, and a long mouth with little everted lips. Her hands are broad and puffy, with broad, typically tapering fingers. In addition to her facial dysmorphism, the thinning of her distal fingers and a clumsy gait were remarkable findings from the physical examination (Fig. 1). She exhibited the skeletal deformity of kyphosis, and the X-ray findings of her hands revealed that their drumstick appearance was compatible with the disease (Fig. 2). She had moderate mental retardation. Because her SIDEs were misdiagnosed as atonic seizures, she was treated with several anti-epileptic drugs including valproic acid, levetiracetam, lamotrigine, primidone, carbamazepine, and clobazam. Since all of her interictal EEGs were normal despite the sudden drop attacks, the patient was admitted to our video monitoring unit for long-term monitoring. No pathological appearance was observed in the simultaneous EEGs, except for a muscular artifact during drop episodes. Her MR imaging revealed a normal appearance of the cerebellum and brain except for a mild dilatation of the lateral ventricles. Her genetic analysis of the RSK2 gene supported a diagnosis of Coffin–Lowry syndrome.

Sequence analysis was performed on all 22 of the exons and the exon–intron boundaries of RPS6KA3 by using the ABI 3130 capillary electrophoresis system. Heterozygote variation c.1973_1974insA (p.M659Dfs*55) was found on exon 21, generating a frameshift mutation beginning in p.Met659 and stopping at the stop codon at position 713. As this event constitutes a truncating mutation and frameshift variant, protein units after position 659 become defective. As seen in Fig. 3, this variation causes damage to the functional protein kinase domain, resulting in a novel mutation. Based on our *in silico* evaluation of the functional effects by using the mutation

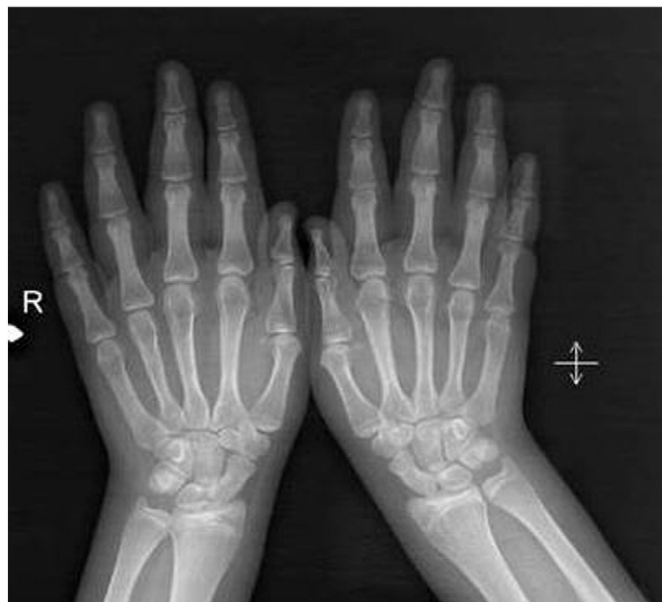

Fig. 2. X-ray showing a drumstick appearance.

taster, Polyphen2, SIFT, and Mutation Assessor, this mutation seems to be the disease-causing entity.

All medications were discontinued following the diagnosis of SIDE. First, clonazepam was started because it is a treatment for this disease that is available in our country. While receiving a daily dose of clonazepam 40 mg (maximum) per day, the number of drop attacks decreased from two or three times a day to 5–6 times a week, depending on the stimuli. Interestingly, most of the drop attacks occurred during menstrual cycles. The reduction in the frequency of drop attacks and the coordination of the patient's movements and gait balance improved with clonazepam treatment. Although clonazepam reduced the frequency of drop attacks, the patient did not achieve a full recovery. For this reason, we began a secondary therapy of sodium oxybate and fluoxetine; however, this treatment regimen did not affect the clinical findings of the patient.

3. Discussion

Coffin–Lowry syndrome is an X-linked inherited disease that is characterized by typical facial and radiological dysmorphism, mental retardation, short stature, pectus deformity, sensory–neuronal hearing loss, and mitral valve deformity. Multipoint linkage analysis of the many X-linked RFLP markers in 4 families was performed in 1988 [8], and the causal gene was identified in 1996. These potential causes of CLS have been postulated as abnormalities in the MAPK/RSK signaling pathway [9]. The effects of RSK, which comprises 22 exons and encodes a protein spanning 740 amino acids, include proliferation, differentiation, cellular stress response, and apoptosis [10].

Coffin–Lowry syndrome is usually diagnosed based on clinical presentation and radiological findings. However, as this diagnosis is difficult to make in very young children and females, a mutational analysis of the RPS6KA3 gene is recommended [4]. Female carriers show a variable range of involvement in this disease, and individuals who are heterozygous are affected less [5]. Moreover, the present case exhibited a heterozygous variant of the disease. More than 100 different mutations have been identified up to 2007; still, 50% of clinically diagnosed patients have no mutations [6]. Highly heterogeneous loss-of-function mutations in the RPS6KA3 gene are responsible for CLS [4]. Both the widespread distribution of mutations and the rather large number of exons contribute to the difficulties in CLS. Because there is no

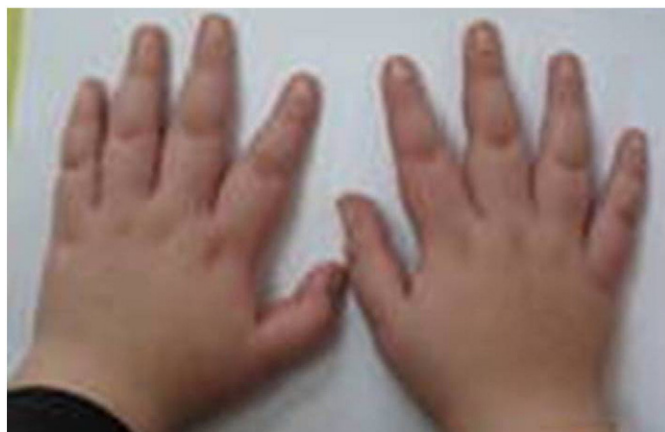


Fig. 1. Photograph of the patient showing the thinning of the distal fingers.

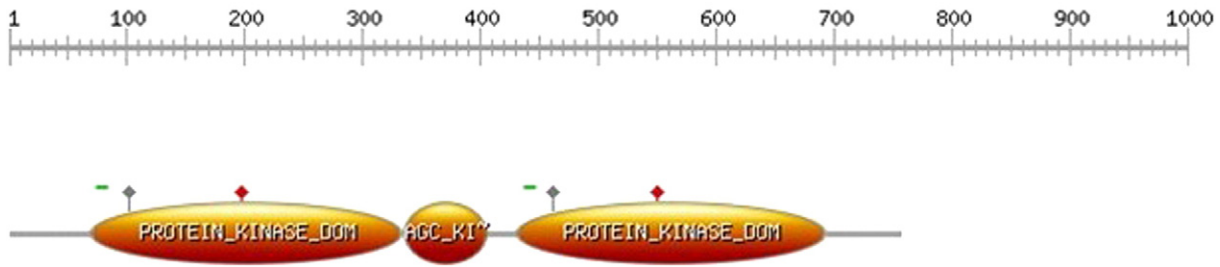


Fig. 3. A truncating mutation and frameshift variant are shown. All protein units after position 659 are defective. This variation causes damage to the functional protein kinase domain.

relationship between the severity of disease and the identified mutations, genetic counseling is difficult [4].

'Stimulus-induced drop episodes' (SIDEs) have been proposed as the term for nonepileptic events in patients with CLS. Stimulus-induced drop episodes are usually characterized by a sudden loss of muscle tone induced after an unexpected tactile or auditory stimulus, the latter of which is more common [5]. Stimulus-induced drop episodes are clinically similar events as cataplexy. Clonazepam was first used by Nakamura et al. in their successful treatment of the drop episodes of a 16-year-old female with Coffin–Lowry syndrome [8–11].

In our case, the patient did not achieve a full recovery with clonazepam; therefore, we started a secondary therapy of sodium oxybate and fluoxetine. Different treatment modalities have been applied in SIDEs. Despite our 6-month trial using sodium oxybate, no improvement in the SIDEs was noted. The effectiveness of sodium oxybate in cases exhibiting a sudden loss of muscle tone is considered an explanation of the mechanism seen in cataplexy rather than in hyperekplexia [7, 12, 13]. Moreover, sodium oxybate is known to be effective in treating drop attacks, even though its exact mechanism remains undetermined [14]. Some reports have indicated that instances of cataplexy, such as atonic falls, are observed at younger ages, whereas hyperekplexia is increasingly observed with advancing age [7]. Several case series have considered the use of valproic acid, fluoxetine, and clomipramine for the treatment of SIDEs. As valproic acid has previously been used without benefit, we added fluoxetine to the present therapy. Fluoxetine did not contribute to an improvement of our case.

4. Conclusion

Our patient performed all of her daily activities with the aid of her family prior to the treatment. After treatment with clonazepam, the family indicated that their child exhibited more balanced movements. Thus, we conclude that clonazepam is the most effective drug for the treatment of SIDEs. Moreover, published reports have shown that the severity and frequency of SIDEs increase with age.

Funding

None.

Acknowledgments

We are very grateful to Dr. Jean Pierre Delaunoy for his aid in our genetic studies. We also thank the int.site "Picture: <http://prosite.expasy.org/cgi-bin/prosite/ScanView.cgi?scanfile=443433327386.scan.gz>" for displaying Fig. 3 and Dr. Dilek Yalnizoğlu for her helpful edits.

Conflicts of interest

The authors declare that there are no conflicts of interest.

References

- [1] Coffin GS, Siris E, Wegenkia LC. Mental retardation with osteocartilaginous anomalies. *Am J Dis Child* 1966;112:205–13.
- [2] Lowry B, Miller JR, Fraser FC. A new dominant gene mental retardation syndrome. *Am J Dis Child* 1971;121:496–500.
- [3] Temtamy SA, Miller JD, Hussels-Maumenee I. The Coffin–Lowry syndrome: an inherited faciodigital mental retardation syndrome. *J Pediatr* 1975;86:724–31.
- [4] Pereira PM, Schneider A, Pannetier S, Heron D, Hanauer A. Coffin Lowry syndrome. *Eur J Hum Genet* 2010;18:627–33.
- [5] Hahn JS, Hanauer A. Stimulus-induced drop episodes in Coffin–Lowry syndrome. *Eur J Med Genet* 2012;55:335–7.
- [6] Micheli V, Sestini S, Parri V, Fichera M, Romano C, Ariani F, et al. RSK2 enzymatic assay as a second level diagnostic tool in Coffin Lowry syndrome. *Clin Chim Acta* 2007;384:35–40.
- [7] Nelson GB, Hahn JS. Stimulus-induced drop episodes in Coffin Lowry syndrome. *Pediatrics* 2003;111:197–202.
- [8] Hanauer A, Alembik Y, Gilgenkrantz S, Mujica P, Nivelon-Chevallier A, Pembrey ME, et al. Probable localisation of the Coffin–Lowry locus in Xp22.2-p22.1 by multipoint linkage analysis. *Am J Med Genet* 1988;30:523–30.
- [9] Trivier E, De Cesare D, Jacquot S, Pannetier S, Zackai E, Young I, et al. Mutations in the kinase Rsk-2 associated with Coffin–Lowry syndrome. *Nature* 1996;384:567–70.
- [10] Hanauer A, Young ID. Coffin–Lowry syndrome: clinical and molecular features. *J Med Genet* 2002;39:705–13.
- [11] Nakamura M, Yamagata T, Momoi MY, Yamazaki T. Drop episodes in Coffin Lowry syndrome: exaggerated startle responses treated with clonazepam. *Pediatr Neurol* 1998;19:148e150.
- [12] Yeomans JS, Frankland PW. The acoustic startle reflex neurons and connections. *Brain Res Rev* 1995;21:301–14.
- [13] Guilleminault C, Gelb M. Clinical aspects and features of cataplexy. *Adv Neurol* 1995; 67:65–77.
- [14] Havaligi N, Matadeen-Ali C, Khurana DS, Marks H, Kothare SV. Treatment of drop attacks in Coffin–Lowry syndrome with the use of sodium oxybate. *Pediatr Neurol* 2007;37:373–4.