

Bursae around the knee joints

Priyank S Chatra

Department of Radiology, Yenepoya Medical College, Mangalore, Karnataka, India

Correspondence: Dr. Priyank S. Chatra, Department of Radiology, Yenepoya Medical College, Deralakatte, Mangalore – 575 018, Karnataka, India. E-mail: khiladi001980@yahoo.co.in

Abstract

A bursa is a fluid-filled structure that is present between the skin and tendon or tendon and bone. The main function of a bursa is to reduce friction between adjacent moving structures. Bursae around the knee can be classified as those around the patella and those that occur elsewhere. In this pictorial essay we describe the most commonly encountered lesions and their MRI appearance.

Key words: Iliotibial bursa; infrapatellar bursa; pes anserine bursa

Introduction

A bursa is a fluid-filled structure that is present between the skin and tendon or tendon and bone. The main function of a bursa is to reduce friction between adjacent moving structures. Typically, bursae are located around large joints such as the shoulder, knee, hip, and elbow.^[1] Inflammation of this fluid-filled structure is called bursitis. Trauma, infection, overuse, and hemorrhage are some of the common causes for inflammation.^[2] Other causes include systemic illness like collagen vascular disease and inflammatory arthropathy; in some instances the cause is unknown.^[3] Some cases of bursitis are associated with certain occupations and are named accordingly; for instance, prepatellar bursitis is also known as housemaid's knee and superficial infrapatellar bursitis is synonymous with clergyman's knee.^[4]

Bursae around the knee can be grouped as those that occur around the patella and those that occur elsewhere.^[1] Bursae around the patella include the prepatellar bursa, the superficial and deep infrapatellar bursae, and the suprapatellar bursa. Bursae that are not anatomically close to the patella include the pes anserine bursa, the iliotibial bursa, the tibial and fibular collateral ligament bursae

and the gastrocnemius-semimembranosus bursa. On MRI imaging, bursitis appears as an oblong fluid collection in its expected anatomical location.

Prepatellar Bursitis

The prepatellar bursa is located between the patella and the overlying subcutaneous tissue. Chronic trauma in the form of prolonged or repeated kneeling leads to inflammation and hemorrhagic bursitis. Clinically, patients may present with pain and swelling over the patella.^[5]

On MRI, prepatellar bursitis appears as an oval fluid-signal-intensity lesion between the subcutaneous tissue and the patella [Figure 1]. Hemorrhagic lesions show T2 shortening on gradient-echo (GRE) images.

Infrapatellar Bursitis

Infrapatellar bursae can be superficial or deep. The superficial infrapatellar bursa is located between the tibial tubercle and the overlying skin, whereas the deep infrapatellar bursa is located between the posterior aspect of the patellar tendon and the tibia.^[4]

Superficial Infrapatellar Bursitis

Superficial infrapatellar bursitis, also called clergyman's knee, is due to inflammation and fluid accumulation resulting from chronic stress. Clinically, there is a palpable swelling inferior to the patella.^[6] On MRI, it appears as a loculated collection that projects exophytically, anterior to the patellar tendon, forming a swelling [Figure 2]. On imaging, it should be differentiated from subcutaneous edema: edema is seen as a diffuse fluid collection seen

Access this article online

Quick Response Code:



Website:
www.ijri.org

DOI:
10.4103/0971-3026.95400

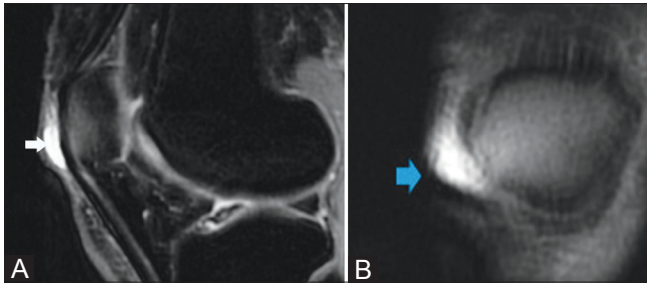


Figure 1 (A,B): Prepatellar bursitis. A 44-year-old female presented with anterior knee pain. Axial (A) and coronal (B) T2W fat saturated images showing a distended pre patellar bursa (arrows)

all over the anterior aspect of the knee, whereas bursitis appears as a localized collection with well-defined borders.

Deep Infrapatellar Bursitis

On MRI, deep infrapatellar bursitis appears as a triangular fluid collection posterior to the patellar tendon [Figure 3]. When found in adolescents, it should be differentiated from Osgood–Schlatter disease [Figure 4].^[7] Osgood–Schlatter disease is associated with thickening and hyperintense signal intensity of the patellar tendon, but these findings are absent in deep infrapatellar bursitis. In addition, cases of Osgood–Schlatter disease, on clinical examination, display pain and tenderness at the insertion of the patellar tendon.

Suprapatellar Bursitis

The suprapatellar bursa is located between the quadriceps tendon and the femur. Failure of regression of the transverse septum formed in embryonic life between the suprapatellar plica and the knee joint fluid leads to the formation of this bursa.^[8] Accumulation of fluid in this bursa leads to bursitis. It may be found incidentally [Figure 5] or, when large and loculated, it may present as a mass above the knee joint.

Pes Anserine Bursitis

The pes anserine bursa separates the pes anserine tendons, consisting of the distal sartorius, gracilis, and semitendinosus tendons, from the subjacent distal portion of the tibial collateral ligament and the bony surface of the medial tibial condyle.^[9] Anserine bursitis results from overuse, especially in runners.^[3]

On MRI, pes anserine bursitis appears as an oblong multiloculated fluid collection seen along the anserine tendons on the posteromedial aspect of the knee [Figure 6]. This is best appreciated on T2W axial images. It is commonly confused with a popliteal cyst; the pes anserine bursa is located posteriorly and medially along the semitendinosus, whereas the popliteal cyst is located more often in the

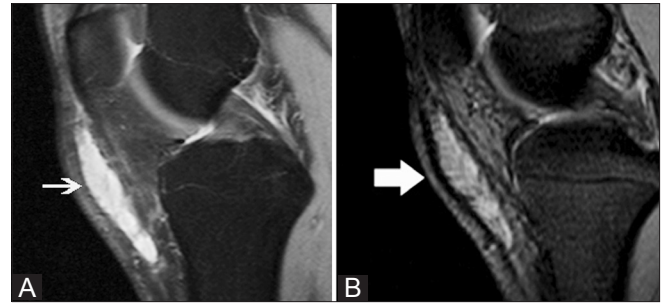


Figure 2 (A,B): Superficial infrapatellar bursitis. A 42-year-old female presented with an anterior knee swelling. Sagittal proton-density fat saturated (A) and sagittal gradient-echo T2W (B) images show a distended superficial infrapatellar bursa (arrows)

midline posteriorly.^[10] Also, pes anserine bursae are small in size; they do not extend into the thigh and never show communication with the knee joint,^[11] whereas a popliteal cyst can extend into the thigh and may or may not communicate with the knee joint.

Medial Collateral Ligament Bursitis

The medial collateral ligament bursa is located between the superficial and deep layers of the medial collateral ligament.^[12] Clinically, fluid collection in this bursa mimics a medial meniscus tear and/or medial collateral ligament tear.

On MRI, medial collateral ligament bursitis appears as a T2 hyperintensity between the superficial and deep fibers of the medial collateral ligament [Figure 7]. It must be differentiated from meniscocapsular separation. In meniscocapsular separation, in addition to fluid collection between the superficial and deep fibers of the medial collateral ligament, there is a tear of the peripheral corner of the medial meniscus and meniscal displacement from the outer cortical margin of the tibia.^[13]

Iliotibial Bursitis

The iliotibial bursa is located between the distal part of the iliotibial band near its insertion on Gerdy tubercle and the adjacent tibial surface. Iliotibial bursitis and tendinitis are usually due to overuse and varus stress of the knee.^[14]

On MRI [Figure 8] iliotibial bursitis appears as a fluid collection near the insertion of the iliotibial tract in its distal part, close to the lateral aspect of the tibia. It must be differentiated from iliotibial tendinitis. On MRI, iliotibial tendinitis appears as a fluid collection encircling the tendon, whereas bursitis appears as a localized oblong fluid collection adjacent to the tendon.^[1]

Baker's Cyst

This is also called a popliteal cyst and typically involves

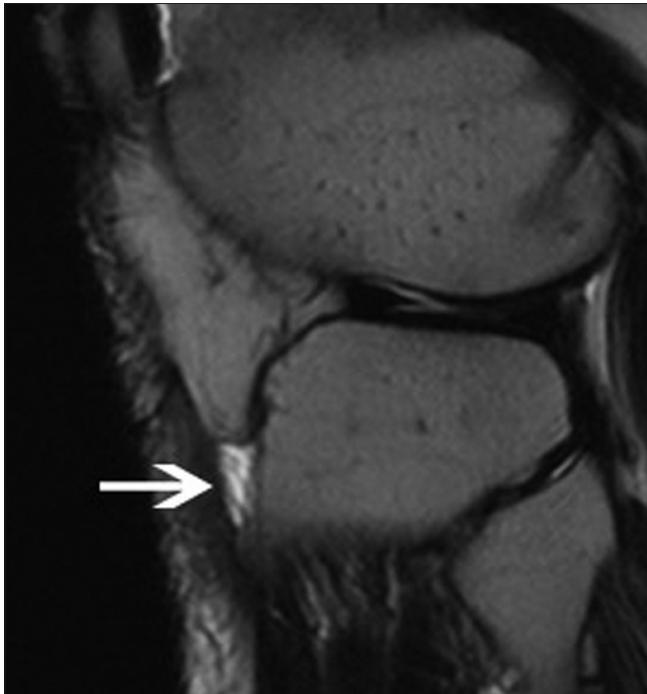


Figure 3: Deep infra patellar bursitis. A 27-year-old male presented with anterior knee pain: sagittal T2W image shows a distended deep infra patellar bursa (arrow)

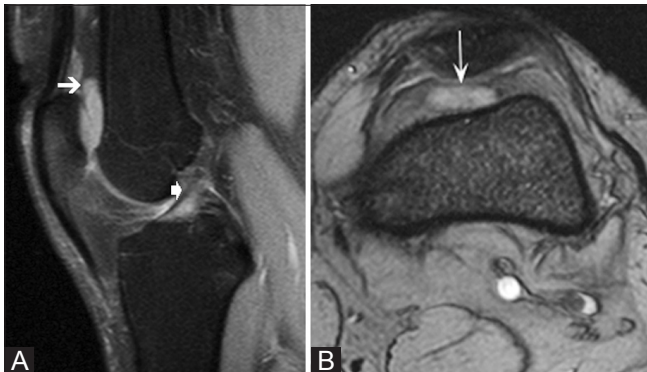


Figure 5 (A,B): Suprapatellar bursitis. A 29-year-old male presented with internal derangement of the knee: sagittal proton density fat saturated (A) and axial T2W gradient-echo (B) images show a distended suprapatellar bursa (arrows) and in addition, a partial tear of the anterior cruciate ligament (thick arrow in A)

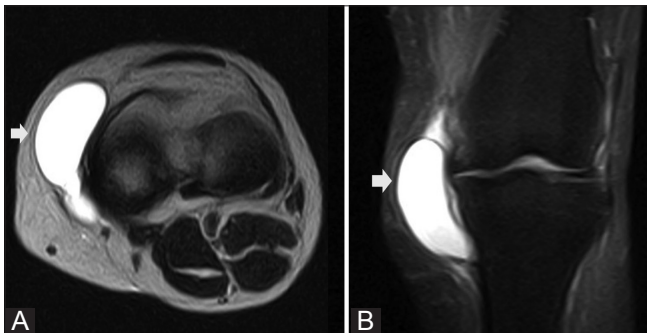


Figure 7 (A,B): Medial collateral ligament bursitis. A 54-year-old female presented with knee swelling: sagittal true inversion recovery magnitude (TIRM) (A) and axial T2W (B) images show a distended medial collateral ligament burse (arrows)

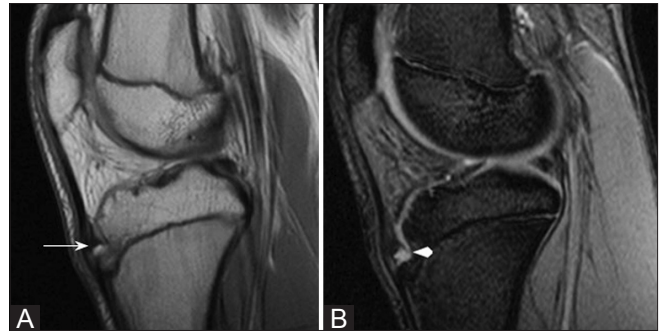


Figure 4 (A,B): Osgood–Schlatter disease. An 11-year-old male presented with anterior knee pain: sagittal proton density (A) and sagittal true inversion recovery magnitude (TIRM) (B) images show thickening of the patellar tendon at the tibial tuberosity (arrow) and a distended deep infrapatellar bursa (arrowhead)

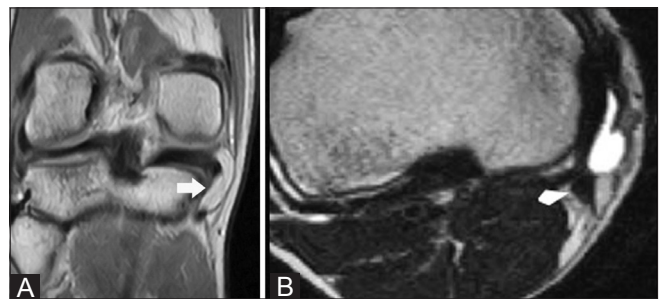


Figure 6 (A,B): Pes anserine bursitis. A 32-year-old female presented with pain along the posteromedial aspect of the knee: Coronal proton density (A) and axial T2W (B) images show a distended pes anserine bursa (arrows). The pes anserinus tendons (arrowhead in B) are seen inferior to the bursa

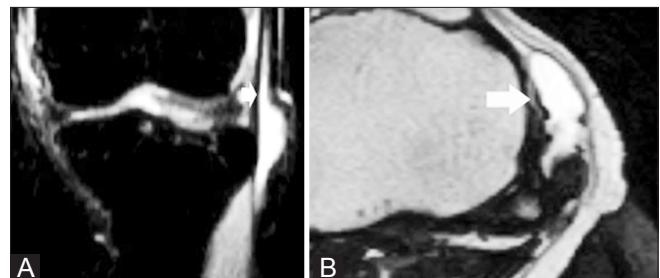


Figure 8 (A,B): Iliotibial bursitis. A 16-year-old female presented with lateral knee swelling: sagittal STIR (A) and axial T2W (B) images show a distended iliotibial bursa (arrows)

the gastrocnemius- semimembranosus bursa and is located between the medial femoral condyle, semimembranosus tendon and the medial head of the gastrocnemius.^[10] It may or may not communicate with the knee joint. It may rupture and extend inferiorly along the gastrocnemius muscle into the calf or extend superiorly into thigh along the semimembranosus.^[15] On MRI they appear as well-defined hyperintense lesions on T2W images at the characteristic location [Figure 9]. Axial images are the best to demonstrate the communication with the knee joint and also

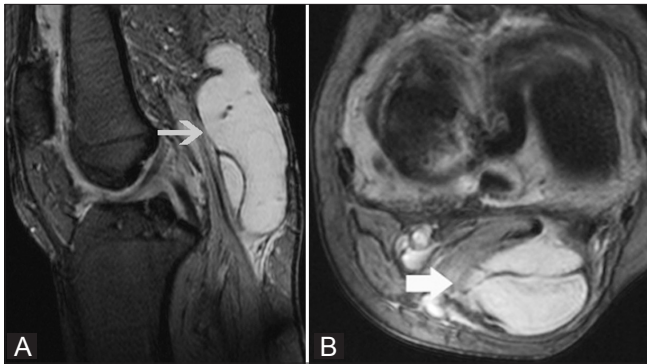


Figure 9 (A,B): Baker's cyst. A 48-year-old male presented with swelling in the popliteal fossa: sagittal (A) and axial (B) T2W gradient-echo images show a distended gastrocnemius--semimembranosus bursa (arrows)

the characteristic location between the semimembranosus tendon and medial head of gastrocnemius.^[6]

Conclusion

Many different types of bursae are seen around the knee joint. Thorough knowledge of the anatomy of the region is of utmost importance for arriving at a correct diagnosis. MRI helps in ruling out other conditions and internal derangements. The majority of cases with bursitis can be treated conservatively, but some may require surgical treatment. Awareness of the different types of lesions helps in arriving at the correct diagnosis which, in turn, helps in proper management.

References

1. Koh WL, Kwek JW, Quek ST, Peh WC. Clinics in diagnostic imaging (77). Pes anserine bursitis. *Singapore Med J* 2002;43:485-91.
2. Hirji Z, Hanjun JS, Choudur HN. Imaging of Bursae. *J Clin Imaging Sci* 2011;1:22.
3. McCarthy CL, McNally EG. The MRI appearance of cystic lesions

- around the knee. *Skeletal Radiol* 2004;33:187-209.
4. Lee P, Hunter TB, Taljanovic M. Musculoskeletal colloquialisms: How did we come up with these names? *Radiographics* 2004;24:1009-27.
5. Bhat AK, Bhaskaranand K. Massive prepatellar bursitis in post-polio residual paralysis: A case report. *J Orthop Surg (Hong Kong)* 2001;9:71-3.
6. De Miguel Mendieta E, Cobo Ibáñez T, Usón Jaeger J, Bonilla Hernán G, Martín Mola E. Clinical and ultrasonographic findings related to knee pain in osteoarthritis. *Osteoarthritis Cartilage* 2006;14:540-4.
7. Gholve PA, Scher DM, Khakharia S, Widmann RF, Green DW. Osgood Schlatter syndrome. *Curr Opin Pediatr* 2007;19:44-50.
8. Dorsey ML, Liu PT, Leslie KO, Beauchamp CP. Painful suprapatellar swelling: Diagnosis and discussion. *Skeletal Radiol* 2008;37:937-8, 951-2.
9. Rennie WJ, Saifuddin A. Pes anserine bursitis: Incidence in symptomatic knees and clinical presentation. *Skeletal Radiol* 2005;34:395-8.
10. Dhillon M, Prasad P, Goel A, Kar A. Giant osteochondral body in popliteal cyst. *Indian J Orthop* 2009;43:93-6.
11. Stacy GS, Heck RK, Peabody TD, Dixon LB. Neoplastic and Tumor like lesions detected on MR imaging of the knee in patients with suspected Internal derangement Entities. *AJR Am J Roentgenol* 2002;178:575-9.
12. De Maeseneer M, Shahabpour M, Van Roy F, Goossens A, De Ridder F, Clarijs J, *et al.* MR imaging of the medial collateral ligament bursa: Findings in patients and anatomic data derived from cadavers. *AJR Am J Roentgenol* 2001;177:911-7.
13. De Maeseneer M, Shahabpour M, Vanderdood K, Van Roy F, Osteaux M. Medial meniscocapsular separation: MR imaging criteria and diagnostic pitfalls. *Eur J Radiol* 2002;41:242-52.
14. Janzen DL, Peterfy CG, Forbes JR, Tirman PF, Genant HK. Cystic lesions around the knee joint: MR imaging findings. *AJR Am J Roentgenol* 1994;163:155-61.
15. Fritschy D, Fasel J, Imbert JC, Bianchi S, Verdonk R, Wirth CJ. The popliteal cyst. *Knee Surg Sports Traumatol Arthrosc* 2006;14:623-8.
16. Handy JR. Popliteal cysts in adults: A review. *Semin Arthritis Rheum* 2001;31:108-18.

Cite this article as: Chatra PS. Bursae around the knee joints. *Indian J Radiol Imaging* 2012;22:27-30.

Source of Support: Nil, **Conflict of Interest:** None declared.