



Contents lists available at ScienceDirect

## International Journal of Surgery Case Reports

journal homepage: [www.casereports.com](http://www.casereports.com)

# A neglected case of chronic abdominal pain due to Lapsi seeds: A unique foreign body at unusual location

Dhruba Kadel<sup>a,\*</sup>, Shashinda Bhujū<sup>a</sup>, Bikash Raj Thapa<sup>b</sup>, Sandeep Kumar Sah<sup>a</sup>

<sup>a</sup> Department of General Surgery, Scheer Memorial Adventist Hospital, Banepa, Kavre, Nepal

<sup>b</sup> Department of Radiology, National Academy of Medical Sciences, National Trauma Center, Nepal

## ARTICLE INFO

## Article history:

Received 17 July 2020

Received in revised form 25 August 2020

Accepted 25 August 2020

Available online 29 August 2020

## Keywords:

Foreign body

*Choerospondias axillaris*

Lapsi

Jejunal obstruction

## ABSTRACT

**INTRODUCTION:** Foreign body ingestion is less common in healthy adult population. Obstructive symptom caused by foreign body at unusual site of gastrointestinal (GI) tract is even rarer.

**PRESENTATION OF CASE:** A 60-year-old female presented to the surgery outpatient department (SOPD) with 40-years of non-specific abdominal pain. Over the years, at various health facilities, multiple abdominal and pelvic ultrasounds were performed. No etiology was identified. A contrast enhanced computed tomography (CECT) of the abdomen found a short segment stricture in distal jejunum and dilated proximal jejunum with multiple hyper dense foreign bodies within the distal part of dilated jejunum. An exploratory laparotomy revealed multiple seed stones of Nepali Hog Plum (Scientific name: *Choerospondias axillaris*; Nepali Language: Lapsi) resided freely within the dilated and inflamed distal jejunum along with two marked strictures and a narrowed lumen at 7 cm apart at the terminal part of unhealthy jejunum. The seeds were successfully removed and a jejunoileal bypass was performed. The patient had an uneventful postoperative recovery.

**DISCUSSION:** Lapsi seeds could reside in human gastrointestinal tract for prolonged period and are indigestible in human digestive system that could lead to various inflammatory changes in gastrointestinal tracts causing obstructive symptoms. Widely consumed fruits in Nepal, lapsi seeds when swallowed even by healthy individuals, could effect in gastrointestinal tract.

**CONCLUSION:** Lapsi seeds could act as foreign body and obstruct human gastrointestinal tract. Healthcare professionals must approach mystery cases with diligence and thoroughness and timely referral to well equipped center could prevent significant morbidity.

© 2020 The Author(s). Published by Elsevier Ltd on behalf of IJS Publishing Group Ltd. This is an open access article under the CC BY-NC-ND license (<http://creativecommons.org/licenses/by-nc-nd/4.0/>).

## 1. Introduction

*Choerospondias axillaris* (also called as Nepali hog plum, “Lapsi” in native Nepali language) is large, deciduous, dioecious and edible subtropical fruit tree of the family *Anacardiaceae* [1,2]. The fruit is consumed fresh, pickled, or as a processed ingredient in a variety of sweet and sour products. Lapsi is rich in vitamin C, essential amino acids, and minerals [3,4]. The fruit contains an external edible portion comprising of peel and pulp (71% (w/w)), and an internal, non-edible, seed stone (29% (w/w)) [1]. The Lapsi seed stone is generally not ingested. If it is eaten, it passes the healthy gastrointestinal (GI) tract uneventfully. What effect GI secretions have on Lapsi seed stone, when seeds resided within GI tract for longer durations, hasn't been studied in humans. In the frugivorous mammals, such as *Muntiacus muntjak vaginalis* (Muntjac), the whole fruit and

seed stone is engulfed and then regurgitated at different locations; this is the primary method of dispersal of *C. axillaris* [5].

Foreign body ingestion is more frequently observed in children. Significant morbidity and mortality could be observed if sharp or foreign body is ingested and diagnosis is delayed. In general, foreign bodies are typically found impacted in pylorus, duodenum, duodeno-jejunal flexure, Mickel's diverticulum, ileo-caecal junction and previous surgical sites [6].

Foreign body obstruction at distal part of jejunum is uncommon [6]. To our knowledge this is the first case report of a Lapsi seed stones residing within the jejunal lumen, of otherwise healthy individual, causing various non-specific abdominal pains. The work has been reported in line with SCARE 2018 criteria [7].

## 2. Case presentation

A 60-year-old female, farmer, presented to the Surgical Outpatient Department (SOPD) at our facility in eastern Nepal with the complaint of abdominal pain for 40-years. She complained of intermittent abdominal distension with mild to moderate abdominal

\* Corresponding author.

E-mail addresses: [kal2dhruba@hotmail.com](mailto:kal2dhruba@hotmail.com)

(D. Kadel), [bhujush@yahoo.com](mailto:bhujush@yahoo.com) (S. Bhujū), [bikashrajthapa@gmail.com](mailto:bikashrajthapa@gmail.com) (B.R. Thapa), [vyahut.sam@gmail.com](mailto:vyahut.sam@gmail.com) (S.K. Sah).

pain. The pain was aggravated by eating and was associated with occasional nausea and vomiting of gastric contents. There was no reported change in bowel habits (frequency or consistency). She reported anorexia and gradual weight loss. Patient revealed unremarkable past history and family history, denied consuming any drug for long duration, denied alcohol intake and smoking and expressed irrelevant psychosocial history.

Prior to coming to our facility, the lady visited multiple hospitals and health care centers. She was treated for dyspepsia, gastritis, and other possible medical causes. A complete treatment history was difficult to obtain as the medical record had been destroyed in the 2015 earthquakes.

Apparently, she had undergone several ultrasounds, all were unrevealing—and no high-resolution imaging such as CT or MRI. No diagnostic or and therapeutic procedures were performed.

Her persistent, unrelenting, worsening of her symptoms prompted her to reestablish care at our facility.

At presentation, her general condition was fair. She was conscious, alert, fully oriented. Her vitals were recorded as: temperature, 98.6°F; blood pressure, 116/78 mmHg; heart rate, 85 beats per minute; and the oxygen saturation, 97%. The cardiac, chest, and lung examination were unrevealing as to the cause of her symptoms. On inspection, her abdominal examination revealed asymmetric bilateral iliac fossa with mild bulging in right, compared to the left, iliac fossa. There was no visible pulsations, surgical scars, striae, dilated veins, rashes and/or visible peristalsis observed at this location. Hypoactive bowel sound was noted on auscultation. She exhibited mild tenderness, without rebound tenderness, guarding, or rigidity, at umbilical and right iliac fossa region during abdominal palpation. Her rectal examination found an evacuated rectal vault with no blood.

The complete blood count, renal function, liver function, and coagulation studies were within normal limits. The ultrasonography of abdomen was repeated and it was unrevealing as to an etiology. A contrast enhanced computed tomography (CECT) of abdomen and pelvis showed: (1) Dilated segment of jejunum with circumferential submucosal edema and abrupt distal narrowed lumen suggestive of stricture. (2) Multiple round (in axial plane) to oval (longitudinal plane) hyperdense foreign bodies of nearly similar size with air attenuating areas and spoke wheel appearance was noted in the dilated bowel (Fig. 1A & B).

The patient had no recollection of eating foreign bodies. A literature review, looking for similar CT findings didn't describe any reports of this type of radiopaque object. Seeds of *Choerospondias axillaris* (Nepali hog plum, native language: lapsi) became the first suspicion after considering various possibilities. The CT image of lapsi seed stone in vitro showed the identical features as shown in vivo (Fig. 1C).

Our patient was scheduled for an exploratory laparotomy to assess the jejunal foreign body and the resulting chronic dilatation. The intraoperative findings were: dilated and inflamed distal jejunum (~40 cm length) located ~200 cm distal to ligament of treitz (Fig. 2A); two stricture sites at 7 cm apart were noted distal to inflamed jejunum (Fig. 2B & C); and, there was no evidence of bowel ischemia.

A 3.0 cm enterotomy was performed at the proximal end of the dilated and inflamed jejunum. Nineteen lapsi seed stones (each measuring ~2.5cm × 1.8cm × 1.8 cm) were removed (Fig. 2D). The bands around the stricture sites were released. A side-to-side anastomosis with 40 cm of bowel, including the inflamed portion, created a jejunoileal bypass. The hand-sewn anastomosis was performed as first layer was closed using full thickness vicryl suture and second layer was by using lambert seromuscular suture.

Postoperatively, patient was managed with intravenous fluid, prophylactic antibiotics and analgesics. The postoperative recovery

of patient was uneventful. She tolerated oral intake on the second post-operative day of surgery. Her discharged to home was on post-operative day 5. The operative wound was healing appropriately at her 1-week follow appointment. Thankfully her symptoms were also improving. By six months after the surgery, her abdominal symptoms were completely resolved and already returned to regular work expressing high satisfaction to surgery.

Interestingly, at the time of discharge she remembered eating a number of lapsi seed stones when she was 19–20-years-old. She never consumed these seeds in the intervening 40-years!

### 3. Discussion

To our knowledge, this is the first reported case of chronic partial jejunal obstruction caused by Lapsi seed stones. This is a very uncommon foreign body, at unusual location (distal part of jejunum), in otherwise healthy individual. Her symptoms resolved with an enterotomy, seed removal, and jejunoileal bypass.

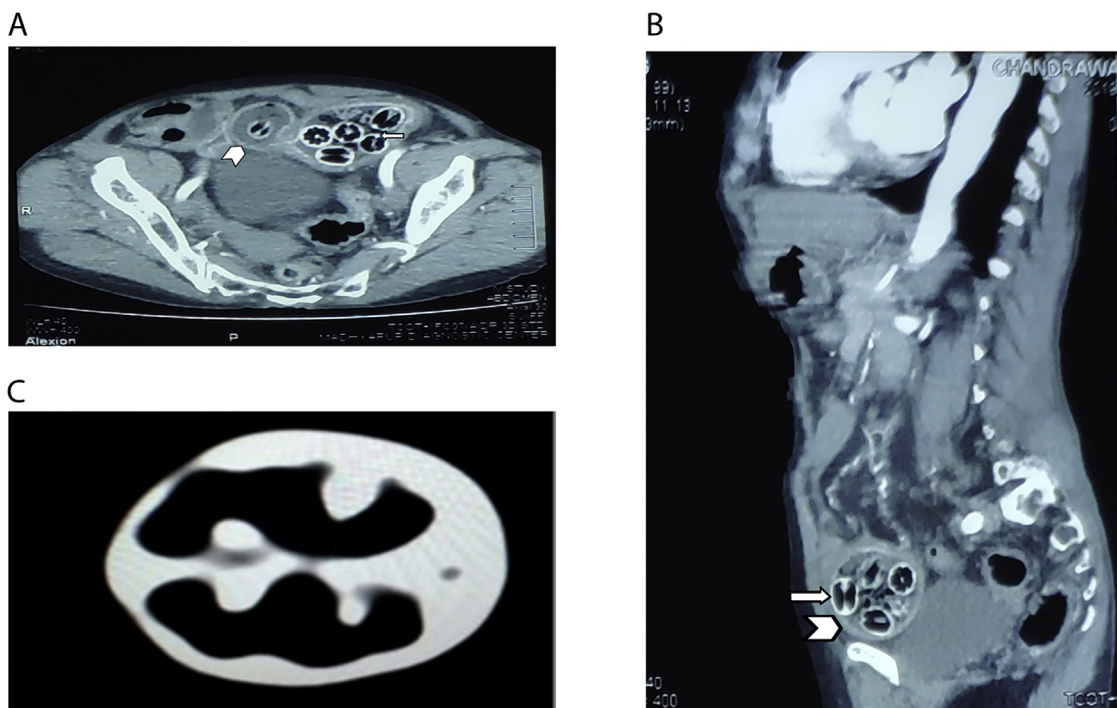
Lapsi seed stone as a foreign body is a unique entity. The partial obstruction by the seeds caused a chronic inflammatory stricture at the distal jejunum. There are many common objects ingested (e.g. coins, keys, toys, button batteries, pins, marbles, stones, nails and rings) and these typically passes in the stool or patients present with vomiting due to acute abdominal symptoms [8]. If an object is to impact, then the common locations of the GI tract are the pylorus, duodenum, duodeno-jejunal flexure, Mickel's diverticulum, ileo-caecal junction and any previous surgical site [6]. If an ingested foreign body transverses the pylorus, then it typically exits the GI tract. Risk factors for ingestion include: children (age 6-months to 3-years), psychiatric illness, bulimia, and binge alcohol drinkers [9–11].

While the complete biochemical and pathological impact of lapsi seed stone, as a foreign body in human GI tract, is unknown, our case demonstrates a chronic inflammatory response. A limitation of this study was that we couldn't measure any alteration of biochemical function in the GI tract. A strength of this study was to characterize the unique CT imaging features of lapsi seed stone and the gross pathological surgical findings.

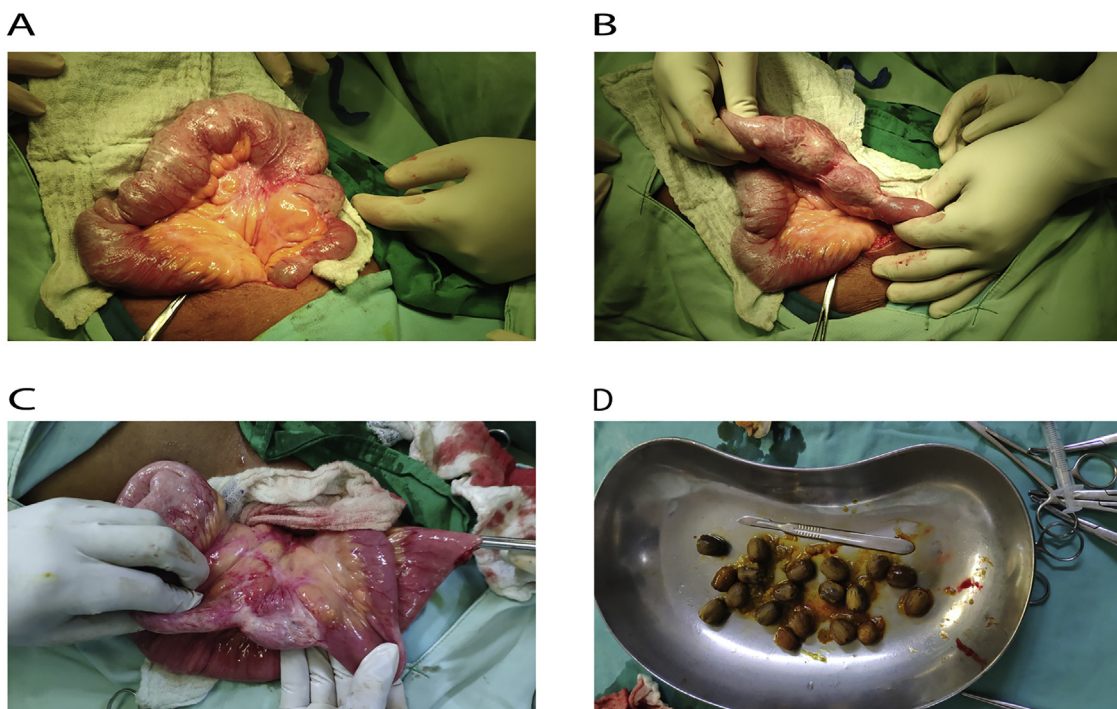
The delayed curative treatment for this patient is due to a late diagnosis. A confirmation bias – based on unremarkable abdominal ultrasound studies – would have been used by prior clinicians at prior encounters. This confirmation bias lead to significant morbidity for the patient.

Ultrasound is widely used in resource limited settings as it is fast, accessible, and comparatively inexpensive. Ultrasound waves do not penetrate bowel gas well and consequently the seeds were invisible to ultrasound waves. A key factor in the delay of ordering a CT, besides cost, is the reality of many health care providers in Nepal have limited training (e.g. certificate level). Algorithmic care can lead to the anchoring bias and a failure to re-evaluate the differential diagnosis when a patient doesn't respond to the care on algorithms. Algorithms are essential to delivery of care when the number of highly trained health professionals are limited to metropolitan areas. A study noted non-physicians and non-surgeons performing 46 types of surgical procedures beyond the recommendation of WHO in 41 low and middle income countries [12]. Most health care facilities lack CT scan technology, this is another factor in the delay of diagnosis. A study conducted in Nepal pointed out the limited but developing radiologic facilities within the country are located mostly in major cities [13]. No access to health insurance and unable to afford a CT scan are two additional barriers to receiving timely care.

Healthcare professionals must approach mystery cases with diligence and thoroughness. A re-review of a differential diagno-



**Fig. 1.** Multiple foreign bodies with “spoke wheel appearance” in small bowel. Contrast-enhanced CT scan image of abdomen (A) axial and (B) coronal reformatted images demonstrate multiple round-oval foreign bodies (arrow) in small bowel with circumferential wall edema (arrow head) of the small bowel. (C) Axial CT image of seed of Lapsi demonstrating hyperdense periphery; spoke wheel like appearances and air attenuating areas within.



**Fig. 2.** Diseased part of intestine. (A) Dilated and inflamed terminal jejunum due to prolonged reaction of foreign body resided within the lumen; Stricture sites noted in the distal inflamed jejunum (B) Anti-mesenteric side and (C) Mesenteric side; (D) Removed 19 Lapsi seed stones.

sis is essential to avoid anchoring biases. Diagnostic studies must be interpreted within the boundaries of their limitations so as to not commit a confirmation bias. Health care workers need to recognize Lapsi seed stones as potential foreign bodies that can cause chronic partial intestinal obstruction at any site of GI tract. Accu-

rate diagnosis is necessary for proper management. Patients should be referred to more skilled health care professions and centers with adequate diagnostic resources to prevent delays in treatment and the corresponding economic and morbidity burden to patients.

**Declaration of Competing Interest**

No conflict of interest.

**Funding**

The study has no funding source.

**Ethical approval**

According to Institutional Review Committee (IRC) of this institution, no ethical approval required for the publication of case report.

**Consent**

Written informed consent was obtained from the patient for publication of this case report and accompanying images. A copy of the written consent is available for review by the Editor-in-Chief of this journal on request.

**Author contribution**

Dr. Dhruba Kadel: Study concept design and writing paper.

Dr. Shashinda Bhujju and Dr. Bikash Raj Thapa: information regarding Lapsi seeds, Radiological interpretation on patient's finding and helping to write paper.

Dr. Sandeep Kumar Sha: Collecting patient's information, follow up of patient's condition, helping to write paper.

**Registration of research studies**

NA.

**Guarantor**

Dr. Dhruba Kadel.

**Provenance and peer review**

Not commissioned, externally peer-reviewed.

**Acknowledgements**

We would like to thank Dr. Jonathon Thorp, MD MBA FACP, for assisting us to edit this article and providing some important information associated with this case.

**References**

- [1] K.C. Paudel, R. Eder, E. Paar, K. Pieber, Chemical composition of Lapsi (*Choerospondias axillaris*) fruit from Nepal, *Mitt Klosterneubg.* 52 (2002) 46–53.
- [2] S. Karki, R. Shakya, V. P. Agrawal, A novel class of protease from *Choerospondias axillaris* (Lapsi) leaves Sudeep, *Int. J. Life Sci.* 3 (2009) 1–5.
- [3] K.C. Paudel, K. Pieber, R. Klumpp, M. Laimer, Evaluation of Lapsi tree (*Choerospondias axillaris*, Roxb.) for fruit production in Nepal, *Die Bodenkultur J. Land Manag. Food Environ.* 54 (1) (2014) 1–9.
- [4] Kc Poudel, Domestication of Lapsi *Choerospondias axillaris* (Roxb.) (B.L. Brutt & A.W. Hill) for fruit production in the middle mountain agroforestry systems in Nepal, *Him J. Sci.* 1 (1) (2003) 55–58.
- [5] J. Chen, X.-B. Deng, Z.-L. Bai, G.-Q. Chen, Y. Liu, Z.-Q. Liu, Fruit characteristics and *Muntingia muntjak vaginalis* (*Muntingia*) visits to individual plants of *Choerospondias axillaris*, *Biotropica* 33 (4) (2001) 718–722, Available from: <http://www.jstor.org/stable/3593176>.
- [6] Saunders W, Philadelphia, Nelson Textbook of Pediatrics, 1996, pp. 106–107.
- [7] R. Agha, M. Borrelli, R. Farwana, K. Koshy, A. Fowler, D. Orgill, et al., The SCARE 2018 statement: updating consensus Surgical Case Report (SCARE) guidelines, *Int. J. Surg.* 1 (October (60)) (2018) 132–136.
- [8] P. Sarwa, R.S. Dahiya, S. Anand, S. Gogna, D. Gupta, B. Arora, A curious case of foreign body induced jejunal obstruction and perforation, *Int. J. Surg. Case Rep.* 5 (9) (2014) 617–619, <http://dx.doi.org/10.1016/j.ijscr.2013.12.028>, CASE REPORT – OPEN ACCESS.
- [9] J.H. Chung, J.S. Kim, Y.T. Song, Small bowel complication caused by magnetic foreign body ingestion of children: two case reports, *J. Pediatr. Surg.* 38 (10) (2003) 1548–1550.
- [10] A.B. Van As, N. Toit, L. Wallis, D. Stool, X. Chen, H. Rode, The South African experience with ingestion injury in children, *Int. J. Pediatr. Otorhinolaryngol.* 67S1 (2003) 175–178.
- [11] W.A. Webb, Management of foreign bodies of the upper gastrointestinal tract: update, *Gastrointest. Endosc.* 41 (1) (1995) 39–51, [http://dx.doi.org/10.1016/S0016-5107\(95\)70274-1](http://dx.doi.org/10.1016/S0016-5107(95)70274-1), Jan 1.
- [12] M. Hoyler, L. Hagander, R. Gillies, R. Riviello, K. Chu, S. Bergström, et al., Surgical Human Resources for Health Surgical care by non-surgeons in low-income and middle-income countries: a systematic review, *Lancet* 385 (2015) S42.
- [13] K. Subedi, P. Sharma, Development of radiology in Nepal: gearing up for mountainous challenges, *J. Am. Coll. Radiol.* 10 (February (25)) (2013).

**Open Access**

This article is published Open Access at [sciencedirect.com](https://www.sciencedirect.com). It is distributed under the [IJSCR Supplemental terms and conditions](#), which permits unrestricted non commercial use, distribution, and reproduction in any medium, provided the original authors and source are credited.