

IMAGES IN EMERGENCY MEDICINE

Infectious Disease

Woman with swollen eyelids

Alaina Brinley Rajagopal MD, PhD^{1,2} ¹California Institute of Technology, Pasadena, California, USA²Department of Emergency Medicine, Kaiser Permanente, Downey, California, USA**Correspondence**

Alaina Brinley Rajagopal, California Institute of Technology, Pasadena, CA, USA.

Email: abrinley@caltech.edu

1 | PATIENT PRESENTATION

A 29-year-old female with a past medical history of well-controlled eczema, latent herpes simplex infection, and 4 months postpartum presented to the emergency department with swelling and erythema of bilateral eyelids. Physical examination demonstrated clustered, vesicular rash to the left eyelid and right eyelid margin with mild conjunctival injection on the right (Figure 1). Slit lamp examination did not show any dendritic lesions. The patient had reactive titers to varicella zoster (previous vaccination) and negative human immunodeficiency virus (HIV) screening. The patient and partner had no history of genital herpes, but the patient did have a history of oral herpes simplex (cold sores).

2 | DIAGNOSIS: BILATERAL HERPES SIMPLEX EYELID INFECTION IN AN IMMUNOCOMPETENT PATIENT

The patient was diagnosed with herpes simplex infection of the bilateral eyelids. The patient was started on oral acyclovir and topical erythromycin ointment.¹ The patient had complete resolution of symptoms by the end of the acyclovir course. This presentation is rare given the bilateral presentation in an individual who is young and does not have a known immunocompromising condition.²⁻⁴

CONFLICT OF INTEREST STATEMENT

Dr. Rajagopal has ownership interest in Esperto Medical and Chromacode, Inc. She is a Board Director and Co-founder of Esperto Medical.

ORCID

Alaina Brinley Rajagopal MD, PhD  <https://orcid.org/0000-0002-2652-0309>

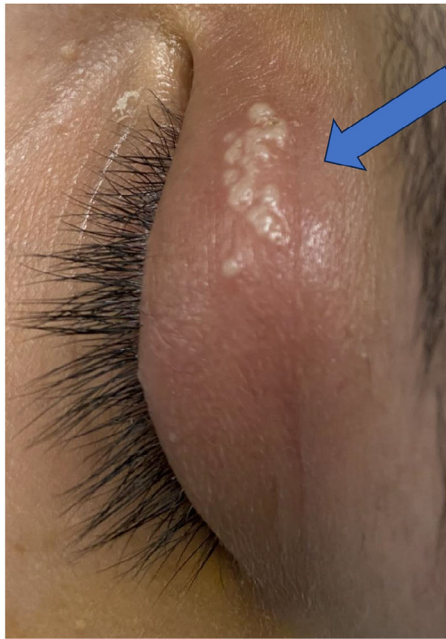REFERENCES

1. Margolis TP, Ostler HB. Treatment of ocular disease in eczema herpeticum. *Am J Ophthalmol*. 1990;110(3):274-279. doi:10.1016/s0002-9394(14)76344-76345
2. Liesegang Thomas JMD. Herpes Simplex Virus Epidemiology and Ocular Importance. *Cornea*. 2001;20(1):1-13.
3. Wishart MS, Darougar S, Viswalingam ND. Recurrent herpes simplex virus ocular infection: epidemiological and clinical features. *Br J Ophthalmol*. 1987;71(9):669-672. doi:10.1136/bjo.71.9.669
4. Wilhelmus KR, Falcon MG, Jones BR. Bilateral herpetic keratitis. *Br J Ophthalmol*. 1981;65(6):385-387. doi:10.1136/bjo.65.6.385

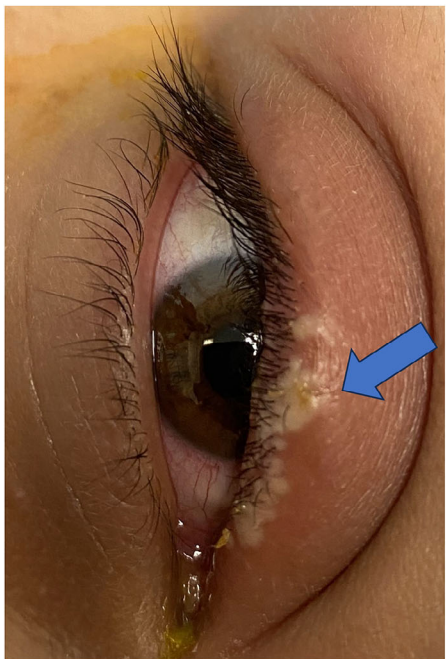
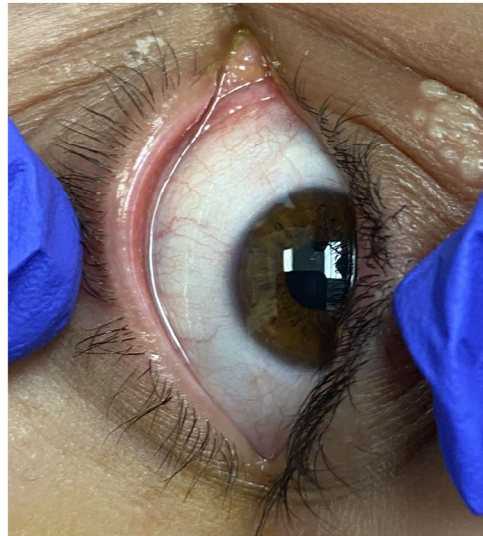How to cite this article: Brinley Rajagopal A. Woman with swollen eyelids. *JACEP Open*. 2024;5:e13277. <https://doi.org/10.1002/emp2.13277>

This is an open access article under the terms of the [Creative Commons Attribution-NonCommercial-NoDerivs](https://creativecommons.org/licenses/by-nc-nd/4.0/) License, which permits use and distribution in any medium, provided the original work is properly cited, the use is non-commercial and no modifications or adaptations are made.

© 2024 The Author(s). *Journal of the American College of Emergency Physicians Open* published by Wiley Periodicals LLC on behalf of American College of Emergency Physicians.



Left Eye



Right Eye

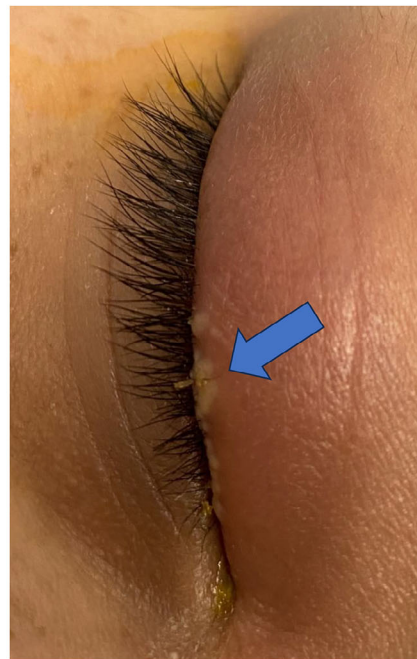

FIGURE 1 Images demonstrating clustered vesicular rash of bilateral eyelids.