



# A late diagnosis of myasthenia gravis at the respiratory practice: back to basics

Lisa Santy<sup>1</sup>, Wim Janssens <sup>1,2</sup> and Bertien Buyse<sup>1,2</sup>

<sup>1</sup>Respiratory Dept, University Hospital Leuven, Leuven, Belgium. <sup>2</sup>Laboratory of Respiratory Diseases and Thoracic Surgery (BREATHE), KU Leuven University, Leuven, Belgium.

Corresponding author: Lisa Santy (Lisa.santy@uzleuven.be)



Shareable abstract (@ERSpublications)

**Myasthenia gravis may affect respiratory muscles. To differentiate between other neuromuscular diseases, evaluation for muscle fatigability can be demonstrated by cardiopulmonary exercise testing and the maximal voluntary ventilation test.** <https://bit.ly/3qMeWfd>

**Cite this article as:** Santy L, Janssens W, Buyse B. A late diagnosis of myasthenia gravis at the respiratory practice: back to basics. *Breathe* 2022; 18: 210167 [DOI: 10.1183/20734735.0167-2021].

Copyright ©ERS 2022

*Breathe* articles are open access and distributed under the terms of the Creative Commons Attribution Non-Commercial Licence 4.0.

Received: 10 Nov 2021  
Accepted: 22 March 2022

A 56-year-old woman presented at the outpatient clinic with complaints of exertional dyspnoea. She was a former smoker (16 pack-years) with a history of idiopathic right trochlear nerve palsy, depression and arterial hypertension. Pulmonary function tests (PFTs) demonstrated normal spirometry (forced expiratory volume in 1 s (FEV<sub>1</sub>) of 1.94 L (82% predicted), forced vital capacity (FVC) of 2.41 L (87% predicted) and FEV<sub>1</sub>/FVC of 0.8), but moderate restrictive disease with total lung capacity (TLC) of 3.10 L (67% predicted), consistent with thoracic kyphoscoliosis seen on the chest radiograph, and abdominal obesity (body mass index (BMI) 30.8 kg·m<sup>-2</sup>) (figure 1a). A tentative diagnosis of asthma was made based on a mild positive challenge test for which treatment with high-dose fluticasone inhalation was started.

2 years later, she presented again for increasing breathlessness. Inhalers were stopped due to lack of clinical benefit. Clinical examination revealed normal lung auscultation. Body weight had increased (BMI 33.7 kg·m<sup>-2</sup>). PFTs revealed a considerable reduction in lung volumes (FEV<sub>1</sub> of 0.85 L (36%), FVC of 1.03 L (35%) and TLC of 2.42 L (53%)), but the results were disturbed by suboptimal performance (figure 1b). The patient was referred for a cardiopulmonary exercise test (CPET) to evaluate exercise capacity and the need for a rehabilitation programme (figure 2 and table 1).

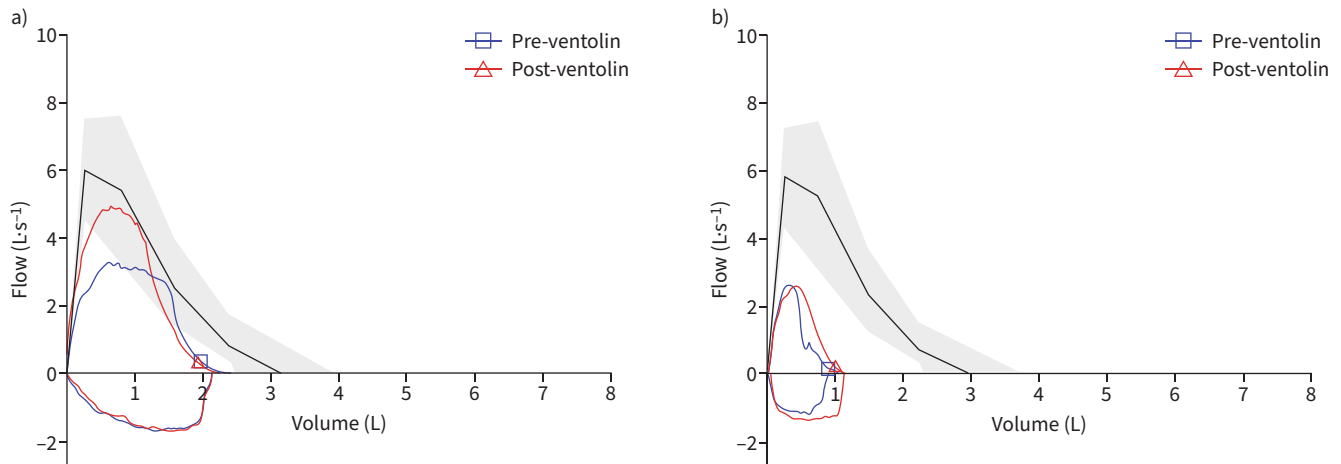
## Task 1

How would you interpret the CPET?

[Go to Answers >>](#)

The patient was advised to lose body weight and combination therapy with high-dose beclomethasone and formoterol was reintroduced. Despite this inhalation therapy, she presented a few weeks later at the emergency department because of progressive exertional dyspnoea, headache and sleepiness during the daytime. She denied productive cough or fever. There was no exposure to other noxious particles or a history of illicit drug abuse. On physical examination, her breathing frequency was 22 breaths per min, heart rate 103 beats per min and her oxygen saturation was 85% on room air. Blood pressure was normal. There were no signs of heart failure. Lung auscultation revealed bilateral hypoventilation without wheezing. Blood analyses were normal. Blood gas analysis (table 2) revealed combined hypoxia and hypercapnia, with elevated bicarbonate suggesting type II chronic respiratory failure. A computed tomography (CT) of the chest showed an important dextroconvex scoliosis and partial atelectasis of both lower lung lobes with symmetrical elevation of both domes of the diaphragm.





	Predicted	Pre-ventolin	% Pred	Post-ventolin
<b>Spirometry</b>				
FVC, L	3.18	2.41	87	2.27
FEV <sub>1</sub> , L	2.55	1.94	82	1.91
FEV <sub>1</sub> /FVC, %	80.47	80.73	101	84.11
PEF, L·s <sup>-1</sup>	6.02	4.31	71	4.93
<b>Lung volumes</b>				
RV, L	1.73	1.23	71	
TGV, L	2.62	1.65	63	
TLC, L	4.71	3.10	66	
<b>Diffusion</b>				
D <sub>LCO</sub> , mmol·min <sup>-1</sup> ·kPa <sup>-1</sup>	7.64	5.34	70	
K <sub>CO</sub> , mmol·min <sup>-1</sup> ·kPa <sup>-1</sup> ·L <sup>-1</sup>	1.65	1.44	87	

	Predicted	Pre-ventolin	% Pred	Post-ventolin
<b>Spirometry</b>				
FVC, L	2.97	1.03	35	1.11
FEV <sub>1</sub> , L	2.37	0.85	36	0.99
FEV <sub>1</sub> /FVC, %	80.06	82.88	104	89.03
PEF, L·s <sup>-1</sup>	5.79	2.62	45	2.61

**FIGURE 1** Flow-volume curves and pulmonary lung function test (PFT) results. a) First PFT with normal spirometry with moderate restrictive disease. b) Control spirometry 2 years later with considerable drop in forced expiratory volume in 1 s (FEV<sub>1</sub>) and forced vital capacity (FVC). Pred: predicted; PEF: peak expiratory flow; RV: residual volume; TGV: thoracic gas volume; TLC: total lung capacity; D<sub>LCO</sub>: diffusion capacity of the lung for carbon monoxide; K<sub>CO</sub>: transfer coefficient of the lung for carbon monoxide.

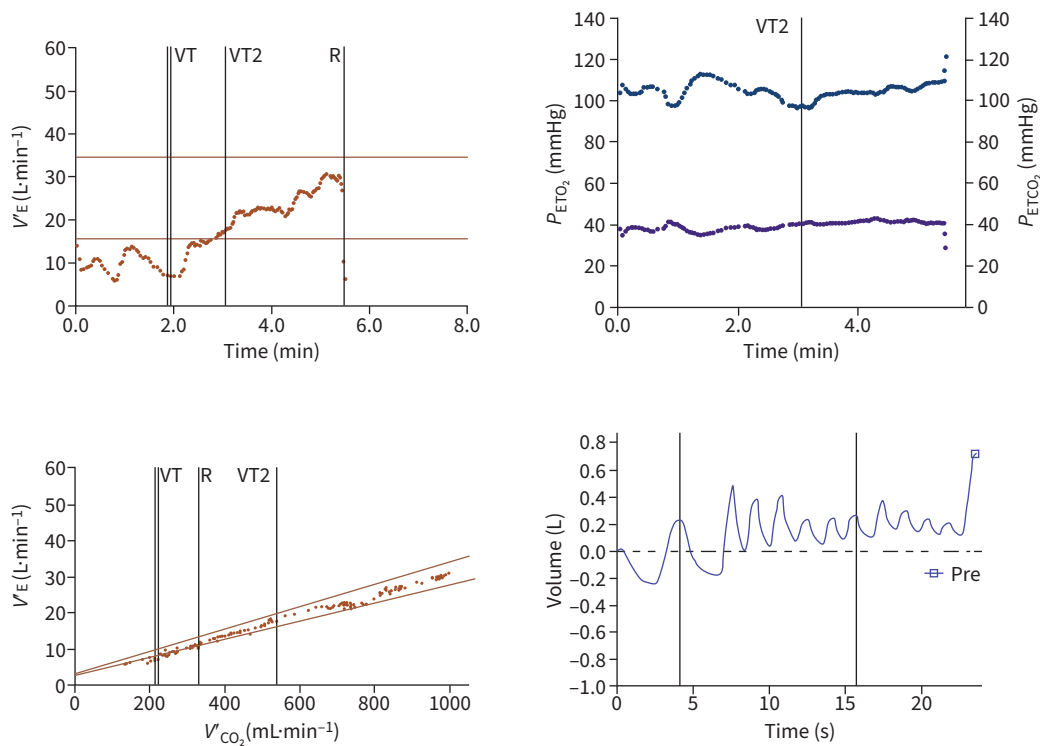
**Task 2**

What are the potential differential diagnoses?

- a) Interstitial lung disease (ILD)
- b) Neuromuscular disease (NMD)
- c) Chest wall deformation
- d) Obesity hypoventilation

[Go to Answers >>](#)

Because of this restrictive pattern and the radiographic suggestion of diaphragm weakness, an additional diaphragm fluoroscopy (also called a “sniff test”) was performed which demonstrated reduced but symmetrical movement of both domes, without paradoxical motion on sniffing. A nerve conduction study of phrenic nerves was considered normal. Hand grip force was measured by dynamometry and was only modestly reduced to 220 Newton (85% predicted). In contrast, measurement of respiratory muscle forces with maximal inspiratory and expiratory mouth pressures (MIP and MEP tests) were severely reduced: 28 cmH<sub>2</sub>O (36% predicted; predictive values based on SCLAUSER PESSOA *et al.* [1]) and 57 cmH<sub>2</sub>O (45% predicted; predictive values based on ROCHESTER *et al.* [2].), respectively.



**FIGURE 2** Cardiopulmonary exercise test. Peak ventilator responses showed a minute ventilation ( $V_E$ ) of  $30\text{ L}\cdot\text{min}^{-1}$ , without clear signs of disturbed gas exchange. Pay attention to the maximum voluntary ventilation and the fainting amplitude of the tidal breaths severely over the testing period. Cardiopulmonary exercise test data are presented in table 1. VT: ventilatory threshold;  $P_{\text{ET}\text{O}_2}$ : end-tidal partial pressure of oxygen;  $P_{\text{ET}\text{CO}_2}$ : end-tidal partial pressure of carbon dioxide;  $V_{\text{CO}_2}$ : carbon dioxide production.

**TABLE 1** Cardiopulmonary exercise test

	Maximum	% Pred	AT	AT % Max
<b>Peak cardiovascular responses</b>				
$V_{\text{O}_2}$ per kg, $\text{mL}\cdot\text{min}^{-1}\cdot\text{kg}^{-1}$	12.2	67	9.4	77
$V_{\text{CO}_2}$ , $\text{mL}\cdot\text{min}^{-1}$	974		540	55
Work, Watts	40	48	20	50
$V_{\text{O}_2}/\text{HR}$	8.9	97	8.1	9.2
Lactate, $\text{mmol}\cdot\text{L}^{-1}$			4.4	
<b>Peak ventilatory responses</b>				
$V_E$ , $\text{L}\cdot\text{min}^{-1}$	30	119	18	59
Breathing reserve, %	-19	-67	30	-159
<b>Gas exchange responses</b>				
$P_{\text{ET}\text{CO}_2}$ , mmHg	40.62		40.11	99
$P_{\text{ET}\text{O}_2}$ , mmHg	16.01		15.19	95
RER	0.97		0.70	
Saturation, %	95		95	
MVV, $\text{L}\cdot\text{min}^{-1}$	9.95	11		
Slope $V_E/V_{\text{O}_2}$	29.98			

The patient reached a maximal work rate of 40 Watts with a peak oxygen consumption ( $V_{\text{O}_2}$ ) of  $12.2\text{ mL}\cdot\text{min}^{-1}\cdot\text{kg}^{-1}$ . Peak ventilator responses showed a minute ventilation ( $V_E$ ) of 119% of her predicted maximum (normal value <80%) with no breathing reserve left. Maximum  $V_E$  also exceeded the maximum voluntary ventilation (MVV). Pred: predicted; AT: anaerobic threshold;  $V_{\text{CO}_2}$ : carbon dioxide production;  $V_{\text{O}_2}/\text{HR}$ : oxygen consumed per heartbeat;  $P_{\text{ET}\text{CO}_2}$ : end-tidal partial pressure of carbon dioxide;  $P_{\text{ET}\text{O}_2}$ : end-tidal partial pressure of oxygen; RER: respiratory exchange ratio;  $V_E/V_{\text{O}_2}$ : ventilator equivalents for carbon for oxygen.

TABLE 2 Blood gas analysis		
Test	Value	Reference value
pH	7.35	7.37–7.45
$P_{CO_2}$ , mmHg	58.5	32.0–45.0
$P_{O_2}$ , mmHg	49.9	80.0–108.0
Bicarbonate, mmol·L <sup>-1</sup>	32.2	22.0–29.0

$P_{CO_2}$ : carbon dioxide tension;  $P_{O_2}$ : oxygen tension.

Considering the chronic hypoxic hypercapnic respiratory failure, the patient was referred to the sleep disorder centre for polysomnographic evaluation. Diagnostic hypnogram with a full night tracing and a 4-min tracing are displayed in figure 3a and b, respectively. Apnoea–hypopnoea index (AHI) was 20.5 events per h, of which 18.3 events per h were scored as obstructive. Mean saturation during the night was 68.8%, mean transcutaneous partial pressure of carbon dioxide was 67.2 mmHg. There were no cardiac events, no periodic limb movements and no Cheyne–Stokes breathing.

**Task 3**

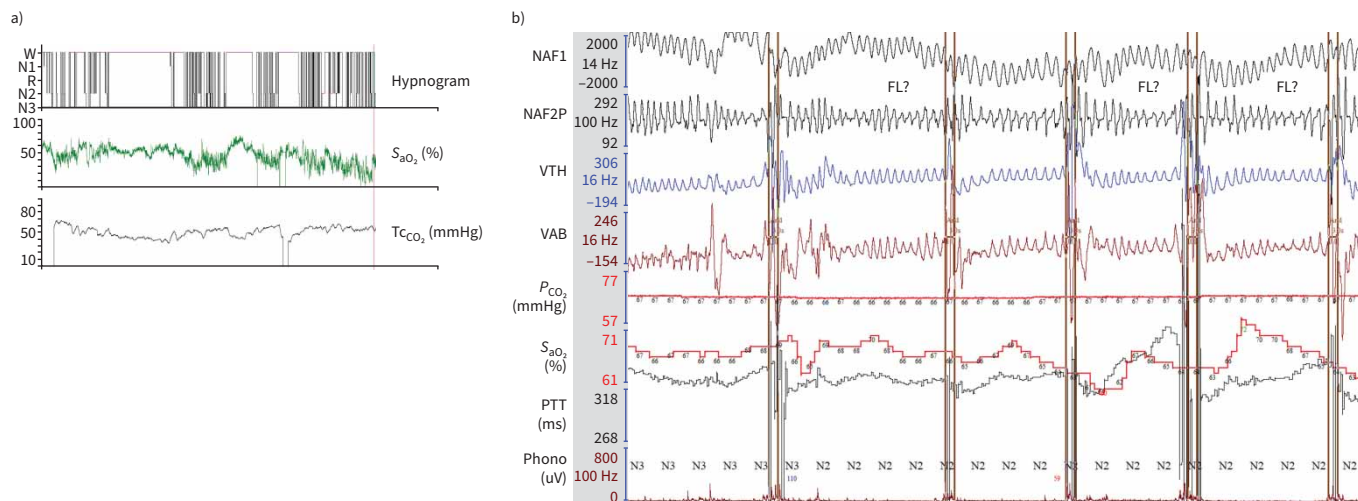
What would be your treatment?

- a) Weight reduction
- b) Continuous positive airway pressure (CPAP)
- c) CPAP in combination with oxygen therapy
- d) Noninvasive ventilation

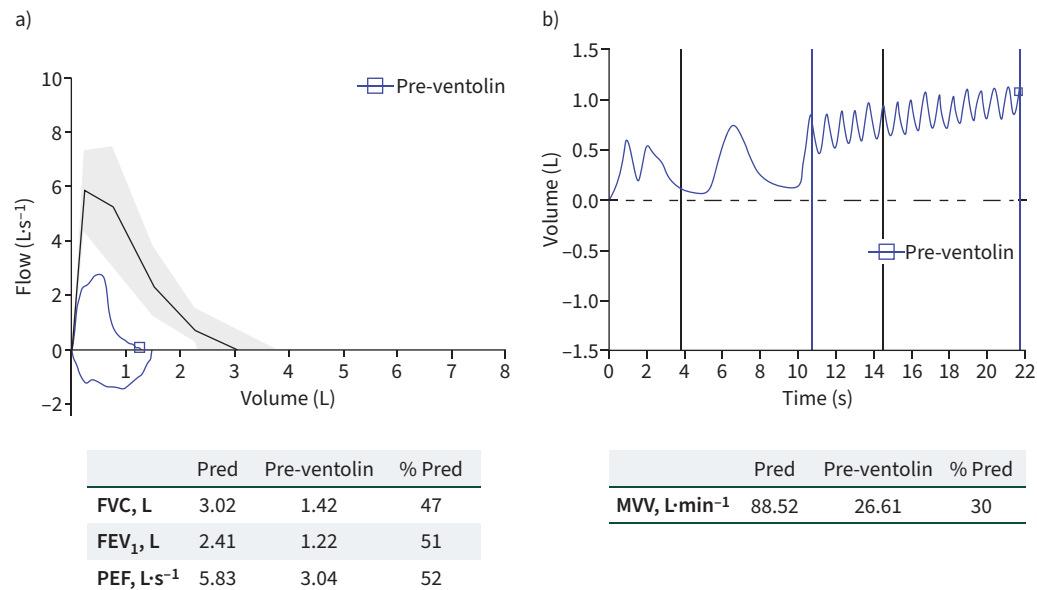
[Go to Answers >>](#)

Noninvasive ventilation was started with bilevel positive airway pressure, with a spontaneous/timed mode (inspiratory positive airway pressure 12 cmH<sub>2</sub>O/expiratory positive airway pressure 4 cmH<sub>2</sub>O, back-up rate 10 per min, inspiratory time 1.4 s). Saturation during the night improved (90–94%) and carbon dioxide tension decreased to 49 mmHg. Complaints of tiredness and headache reduced.

All these findings together raised suspicion for a NMD for which a new neurological evaluation was requested. Magnetic resonance imaging of the brain, cerebrospinal puncture and screening electromyography of the extremities did not reveal any obvious diagnosis. Eventually, an electromyography with repetitive nerve stimulation demonstrated decrement in nerve conduction at the M. nasalis suggestive for a postsynaptic



**FIGURE 3** a) Full night tracing diagnostic hypnogram and b) 4-min tracing. The persistent hypercapnia cannot be explained by sleep apnoea alone. There are many episodes of hypoventilation, interrupted by arousal. W: wake; N1: non-rapid eye movement (REM) stage; R: REM; N2: non-REM stage 2; N3: non-REM stage 3; NAF1: oronasal flow measured with temperature gradient; NAF2P: oronasal flow measured with pressure gradient; VAB and VTH are recordings of abdominal and thoracic circumference; TcCO<sub>2</sub>: transcutaneous carbon dioxide; S<sub>aO<sub>2</sub></sub>: oxygen saturation; P<sub>CO<sub>2</sub></sub>: carbon dioxide tension; PTT: pulse transit time; Phono: sound recording; FL: flow limitation.



**FIGURE 4** a) Flow–volume curves and pulmonary function test results. b) Maximum voluntary ventilation (MVV) curve and function test results. Re-evaluation 3 months after treatment with corticosteroids and pyridostigmine. Spirometry and MVV showed a clear improvement. MVV raised to 26.61 L (30%) and no longer showed a fainting amplitude. Pred: predicted; FVC: forced vital capacity; FEV<sub>1</sub>: forced expiratory volume in 1 s; PEF: peak expiratory flow.

neuromuscular junction disorder. Screening for antibodies was positive for muscle-specific serum kinase (MuSK). CT chest excluded an underlying thymoma. The diagnosis of seropositive MuSK-myasthenia gravis was made and treatment with high-dose corticosteroids and pyridostigmine was started.

Re-evaluation 3 months later by CPET and lung function (figure 4a) demonstrated a clear improvement. MVV raised to 26.61 L (30%) and did not show a fainting amplitude anymore (figure 4b). Peak work rate improved by 10 Watts (50 Watts, 60% of her predicted maximum) and  $\dot{V}_{O_2}$  peak by 990 mL·min<sup>-1</sup> (67% predicted), FVC and FEV<sub>1</sub> recovered to 1.42 L (47% predicted) and 1.22 L (51% predicted), respectively. Use of noninvasive ventilation was successful: the patient mentioned less fatigue, and daytime arterial carbon dioxide tension was normalised to 37 mmHg. With effective treatment of the myasthenia gravis, the noninvasive ventilation could be stopped. The patient was referred to a rehabilitation programme and further follow-up was provided by the neurological department.

### Discussion

Myasthenia gravis is a chronic autoimmune disease in which antibodies cause impairment of neuromuscular transmission at the postsynaptic membrane of voluntary muscles [3]. MuSK myasthenia gravis affects only 5–8% of all myasthenia gravis patients. MuSK has an important role in postsynaptic differentiation and clustering of the acetylcholine receptor, which is interfered with in the case of MuSK-antibodies. The typical clinical picture of this subtype is rapid onset and progression, with bulbar or ocular muscles being affected in 80% of cases. Generalised fatigue with axial muscle weakness and muscle atrophy has also been described [4]. Few case reports mention isolated respiratory insufficiency as the sole presentation [5].

In this case the patient presented with dyspnoea for 2 years before the diagnosis was made. An initial work-up included normal spirometry and a mild positive challenge test, suggestive for asthma. It is not clear whether these symptoms were the first manifestation of the underlying myasthenia gravis, but this seems rather unlikely given the rapid progression of a MuSK-related myasthenia gravis disease.

As there was progressive exertional dyspnoea, CPET was performed showing ventilatory limitation (peak  $\dot{V}_E$  (30 L·min<sup>-1</sup>) exceeding the MVV). MVV was notably reduced with a striking discrepancy between the measured MVV (9.95 L·min<sup>-1</sup>) and the predicted MVV (34 L·min<sup>-1</sup>, or 40×0.85 L) which was left unrecognised and interpreted as a poorly conducted manoeuvre. As one of the key characteristics of myasthenia gravis is progressive muscular weakness by repetitive activity, the sustained MVV is more likely to demonstrate respiratory muscle fatigue. Additionally, as a typical myasthenic pattern [6], the curve

of the MVV showed a progressive reduction of inspiratory and expiratory volumes during the exercise, analogous to the decrement observed with repetitive nerve stimulation. Even in patients without respiratory complaints, a reduction in inhaled and exhaled volumes during MVV has been noticed [7].

Because of sudden type II respiratory failure, repeat PFTs were performed. Spirometry revealed a restrictive pattern with reduced FVC and FEV<sub>1</sub> with a normal FEV<sub>1</sub>/FVC ratio. Both MIP and MEP were reduced, and diaphragm fluoroscopy demonstrated diminished but symmetrical movement of both domes. Although MIP and MEP tests should be considered single concentric muscular contractions and rather insensitive to detect muscle fatigue, the observed reduction of inspiratory muscle strength may fit within the progressive myasthenia gravis-related muscular atrophy. It resulted in hypopnoeas, apnoeas and eventually type II respiratory failure. As MuSK-related myasthenia gravis does not primarily affect the distal limb muscles, repetitive nerve stimulation of the proximal muscle groups is preferred in the case of MuSK-related myasthenia gravis suspicion [4].

### Conclusion

This case illustrates the insidious onset and progression of MuSK myasthenia gravis, initially unrecognised despite clear early signs on CPET and spirometry. Myasthenia gravis or other NMD should be considered if PFTs reveal a decreased vital capacity with normal or high RV, without signs of underlying ILD. Diagnosis can be supported with reduced MIP/MEP, which are maximal isometric contractions. More sensitive assessments to address muscle fatigue are endurance manoeuvres such as the MVV. These assessments may support a faster diagnosis and initiation of adequate therapy.

#### Answer 1

The patient reached a maximal work rate of 40 Watts (48% of her predicted maximum of 84 Watts). She achieved a peak oxygen consumption ( $V_{O_2}$ ) of 12.2 mL·min<sup>-1</sup>·kg<sup>-1</sup> (67% of her predicted maximum). The study showed a maximal effort evidenced by the patient's exhaustion (high Borg scores). Peak ventilatory responses demonstrated a minute ventilation ( $V_E$ ) of 30 L·min<sup>-1</sup>; 119% of her predicted maximum (normal value <80%) with no breathing reserve left. Maximum  $V_E$  also exceeded the maximum voluntary ventilation (MVV) which was judged to be badly performed as the amplitude of the tidal breaths severely reduced over the testing period. Heart rate (HR) increased with increasing loads, with a large residual cardiac reserve (HR only 69% of predicted maximal HR, normal >90% predicted) at peak exercise. There were no signs of disturbed gas exchange, with a  $V_E/V_{O_2}$  ratio of 0.23 at anaerobic threshold, a stable peripheral oxygen saturation (95%) and a progressive rise of end-tidal partial pressure of carbon dioxide ( $P_{ETCO_2}$ ) with normal  $V_E$ /carbon dioxide production ( $V_{CO_2}$ ) slope. Respiratory exchange ratio remained below 1.0 and capillary lactate at the end of the test was 4.4 mmol·L<sup>-1</sup>. The exercise test was stopped because of combined dyspnoea and leg fatigue (Borg dyspnoea scale 8/10, Borg fatigue scale 8/10). In summary, the exercise capacity was primarily impaired by a ventilatory limitation.

<< Go to Task 1

#### Answer 2

b and c. In cases of restrictive PFTs, a distinction should be made between ILD, NMD and chest wall restriction. In cases of ILD, in which elastic recoil is increased, peak expiratory flow (PEF) is often disproportionately high with a steeper slope of the descending limb of the flow–volume curve and an increased FEV<sub>1</sub>/FVC ratio. The functional residual capacity (FRC) and residual volume (RV) are generally decreased. This contrasts with the findings in patients with NMD, obesity or chest wall deformation with no increased elastic recoil, resulting in a normal or slightly reduced FRC, lower TLC because of impaired inspiratory capacity and normal RV (the latter is sometimes increased in case of expiratory muscle weakness). In cases of NMD, PEF is typically decreased, and the curve is rather convex in shape and parallel to the predicted one. Because of reduced alveolar ventilation ( $V_A$ ) diffusion capacity ( $D_{LCO}$ ) will be impaired in any of the diseases, with a reduced  $D_{LCO}/V_A$  for ILD (impaired alveolar-capillary network) and a normal to increased  $D_{LCO}/V_A$  in cases of NMD or chest wall disease (normal alveolar-capillary network and if no atelectasis).

<< Go to Task 2

#### Answer 3

d. The full night tracing shows a fragmented sleep pattern with long periods of wakefulness. Although some events suggest flow limitation, the persistent grade of significant desaturation and hypercapnia was not linked to preceding reductions of amplitude of flow and sleep apnoea. The events observed on the 4-min tracing are mainly hypoventilation episodes, interrupted by arousal. Noninvasive ventilation is the first treatment of choice for this severe (obstructive) hypoventilation.

<< Go to Task 3

Conflict of interest: The authors have nothing to disclose.

### References

- 1 Sclauser Pessoa IM, Franco Parreira V, Fregonezi GA, *et al.* Reference values for maximal inspiratory pressure: a systematic review. *Can Respir J* 2014; 21: 43–50.
- 2 Rochester DF, Arora NS. Respiratory muscle failure. *Med Clin North Am* 1983; 67: 573–597.
- 3 Gilhus NE, Tzartos S, Evoli A, *et al.* Myasthenia gravis. *Nat Rev Dis Primers* 2019; 5: 30.
- 4 Rodolico C, Bonanno C, Toscano A, *et al.* MuSK-associated myasthenia gravis: clinical features and management. *Front Neurol* 2020; 11: 660.
- 5 Tsai C, Howard JF Jr, Mehrabyan A. A case of MuSK myasthenia gravis presenting with persistent respiratory insufficiency. *J Clin Neuromuscul Dis* 2021; 23: 39–42.
- 6 Oliveira EF, Nacif SR, Urbano JJ, *et al.* Sleep, lung function, and quality of life in patients with myasthenia gravis: a cross-sectional study. *Neuromuscul Disord* 2017; 27: 120–127.
- 7 Heliopoulos I, Patlakas G, Vadikolias K, *et al.* Maximal voluntary ventilation in myasthenia gravis. *Muscle Nerve* 2003; 27: 715–719.