

Reverse distal femoral locking compression plate a salvage option in nonunion of proximal femoral fractures

Sampat S Dumbre Patil, Sachin S Karkamkar, Vaishali S Dumbre Patil, Shailesh S Patil, Abhijeet S Ranaware

ABSTRACT

Background: When primary fixation of proximal femoral fractures with implants fails, revision osteosynthesis may be challenging. Tracts of previous implants and remaining insufficient bone stock in the proximal femur pose unique problems for the treatment. Intramedullary implants like proximal femoral nail (PFN) or surface implants like Dynamic Condylar Screw (DCS) are few of the described implants for revision surgery. There is no evidence in the literature to choose one implant over the other. We used the reverse distal femur locking compression plate (LCP) of the contralateral side in such cases undergoing revision surgery. This implant has multiple options of fixation in proximal femur and its curvature along the length matches the anterior bow of the femur. We aimed to evaluate the efficacy of this implant in salvage situations.

Materials and Methods: Twenty patients of failed primary proximal femoral fractures who underwent revision surgery with reverse distal femoral locking plate from February 2009 to November 2012 were included in this retrospective study. There were 18 subtrochanteric fractures and two ipsilateral femoral neck and shaft fractures, which exhibited delayed union or nonunion. The study included 14 males and six females. The mean patient age was 43.6 years (range 22–65 years) and mean followup period was 52.1 months (range 27–72 months). Delayed union was considered when clinical and radiological signs of union failed to progress at the end of four months from initial surgery.

Results: All fractures exhibited union without any complications. Union was assessed clinically and radiologically. One case of ipsilateral femoral neck and shaft fracture required bone grafting at the second stage for delayed union of the femoral shaft fracture.

Conclusions: Reverse distal femoral LCP of the contralateral side can be used as a salvage option for failed fixation of proximal femoral fractures exhibiting nonunion.

Key words: Reverse distal femur locking compression plate, ipsilateral femoral neck and shaft fracture, nonunion fracture proximal femur, proximal femur fracture

MeSH terms: Osteosynthesis, bone plates, subtrochanteric fractures, orthopedic equipment

INTRODUCTION

Surface implants (extramedullary) like a dynamic hip screw (DHS), dynamic condylar screw (DCS), proximal femoral locking compression plate (LCP), or intramedullary implants such as proximal femoral nail (PFN) are commonly used for the fixation of proximal femoral fractures. When primary fixation with these

implants fails, revision surgery is a challenge because of tracts of previous implants and inadequate purchase.

Over a period of 4 years, we have used reverse distal femur (DF) LCP of the contralateral side undergoing revision surgery. In this study, we aimed to evaluate the results of this implant in salvage conditions.

MATERIALS AND METHODS

20 patients (14 men and 6 women) with failed primary

Department of Orthopaedics, Noble Hospital, Hadapsar, Pune, Maharashtra, India

Address for correspondence: Dr. Sampat S Dumbre Patil, Department of Orthopaedics, Noble Hospital, 153, Magarpatta City Road, Hadapsar, Pune - 411 013, Maharashtra, India. E-mail: sampatdumbre@gmail.com

Access this article online	
Quick Response Code:	Website: www.ijoonline.com
	DOI: 10.4103/0019-5413.185598

This is an open access article distributed under the terms of the Creative Commons Attribution-NonCommercial-ShareAlike 3.0 License, which allows others to remix, tweak, and build upon the work non-commercially, as long as the author is credited and the new creations are licensed under the identical terms.

For reprints contact: reprints@medknow.com

How to cite this article: Dumbre Patil VS, Karkamkar SS, Patil V, Patil SS, Ranaware AS. Reverse distal femoral locking compression plate a salvage option in nonunion of proximal femoral fractures. Indian J Orthop 2016;50:374-8.

proximal femoral fractures were treated using reverse distal femoral LCP of the contralateral side, from February 2009 to November 2012. There were 18 subtrochanteric fractures and two ipsilateral femoral neck and shaft fractures, which exhibited delayed union or nonunion. The mean age was 43.6 years (range 22–65 years). All patients were examined pre- and postoperatively by two senior orthopedic surgeons at a Level I trauma center. Reverse distal femoral LCP was used for revision surgery in all cases of failed proximal femoral fractures [Table 1]. All of these cases either exhibited delayed or nonunion following the primary treatment.

Cases of intertrochanteric fractures (including those with fresh fractures and those exhibiting nonunion) were not treated with this implant.

The surgery was performed at an average of 7.5 months (range 4–18 months) after the initial surgery. Among these cases, five patients had already undergone multiple operations with conventional intramedullary or surface implants, although clinical or radiological union was not achieved. Of the 20 cases undergoing revision surgery, initial fixation was performed with intramedullary implants (PFN) in 17 and surface implants (DHS) in three.

In one case of nonunion ipsilateral neck and shaft femur, we used autologous fibula graft in the neck femur for adequate purchase of screws. In 14 cases of subtrochanteric delayed union corticocancellous bone graft was used.

Table 1: Distribution of nonunion cases according to the type of fracture

Type of fracture	Nonunion without implant failure	Nonunion with implant failure
Subtrochanteric	11	7
Ipsilateral neck with shaft femur	0	2

Operative procedure

All patients were operated in a lateral position on a radiolucent table under epidural anesthesia. The previous implant was removed. Closed reduction in five cases was achieved by manipulation with tens nail of appropriate size. In nonunion cases, fracture site was exposed, freshening of bony ends was done, and then fixation under compression mode was achieved with the plate.

While fixing the plate, first unicortical screw was inserted in the distal fragment and kept loose to allow the plate to flip and allow insertion of the proximal screw in desired anteversion. This trick also helps to insert the plate according to the anterior bowing of the shaft femur. While inserting proximal screws, C-arm is used to confirm their placement in the neck in anteroposterior and lateral views. Depending on the orientation of the plate, previous screw tracts, and bone stock, appropriate screw hole is chosen to insert the screw which is locking most of the times. However on some occasions, we have also used nonlocking screws into these proximal holes to get purchase in good bone.

RESULTS

All the twenty patients were followed up clinically and radiologically over a mean period of 52.1 months (range 27–72 months). In 14 cases of subtrochanteric fractures with delayed or nonunion, we performed autologous iliac crest bone grafting during osteosynthesis with distal femoral LCP. In one case of ipsilateral femoral neck and shaft fracture, the autologous fibula was inserted into the head and neck of the femur and autologous iliac crest bone grafting was performed for the femoral shaft fracture. In this case, autologous iliac crest bone grafting was performed again after 5 months, due to delayed union of the femoral shaft.

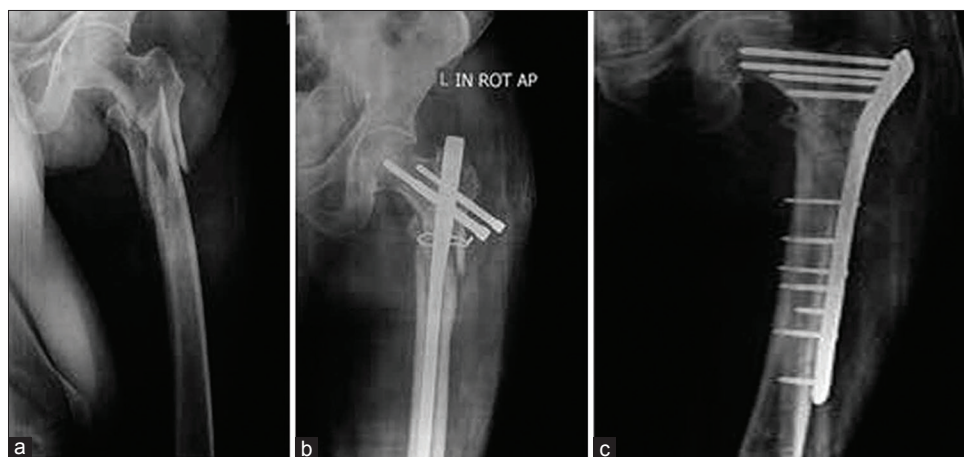


Figure 1: (a) X-ray left hip joint with thigh anteroposterior view showing comminuted subtrochanteric fracture femur (b) long proximal femoral nail with nonunion at 9 months after primary fixation. (c) The implant was removed and revision fixation was performed in the compression mode with reverse distal femoral locking compression plate. The radiographs show union at the 4-month followup

All twenty cases had union without any complications. None of the case required revision fixation.

DISCUSSION

Subtrochanteric, ipsilateral neck and femoral shaft fractures are high-energy injuries in young patients. The overall incidence of nonunion or delayed union of subtrochanteric fractures and subsequent failure for any type of fixation varies from 7% to 20%.¹⁻³ Saarenpää *et al.* (2009) reported a reoperation rate of 8.2% with the use of DHS.⁴ Moreover, various studies have reported that the failure rate of gamma nails ranges between 12.7% and 15%.^{4,5} In addition, with regard to the use of PFN, Uzun *et al.*⁶ (2009) reported a nonunion rate of 5.7% and a reoperation rate of 14.3%, whereas Takigami *et al.*⁷ (2008) reported a reoperation rate of 4%.

In cases where primary fixation with conventional implants fails, revision osteosynthesis may prove to be challenging for the operating surgeon due to several reasons. First, the entry point and reamed canal of the previous intramedullary implant may pose problems for the insertion of a new intramedullary implant with better angulation and alignment. Second, there may be insufficient bone stock in the proximal femur due to the previous surgeries. In such cases, revision surgery

with surface implants such as DHS/DCS may also be difficult due to inadequate purchase of the screw in the femoral head. Third, in cases of nonunion, fixation in compression mode is desirable. The distal femoral LCP has combiholes. One part of combihole is for locking screw and another for conventional nonlocking screw. The nonlocking screw is inserted in nonlocking part of combihole to achieve compression. Nevertheless, in cases that have undergone multiple operations, it is difficult to achieve compression with conventional intramedullary implants. Implants such as PFN, DHS, or DCS can be used for revision surgery in such challenging cases. However, distal femoral LCP can be used to achieve stable fixation in compression mode [Figure 1a and b]. We preferred to use reverse DF LCP of the contralateral side due to the unique features.

There are multiple options for screw insertion in the proximal femur LCP. The proximal screws of the distal femoral LCP are at different angles as compared with the screws used in previous fixation methods such as PFN, DHS or DCS. Hence, better purchase can be obtained in the remaining bone stock of the proximal femur. The curvature of the distal femoral plate, designed for the contralateral side, corresponds satisfactorily with the anterior bow of the proximal femur [Figure 2]. Fixation using a long plate may be obtained by a minimally invasive surgical approach [Figure 3].

Although proximal femoral LCP was available for use as a fixation option, we chose not to use this method due to the lack of anterior curvature, as well as the limited options available for inserting screws in the proximal femur.

In our series, we had a case of ipsilateral neck femur with shaft femur. This 22 year male was operated four times and exhibited nonunion of neck as well as shaft femur with implant failure. We removed the broken PFN and inserted

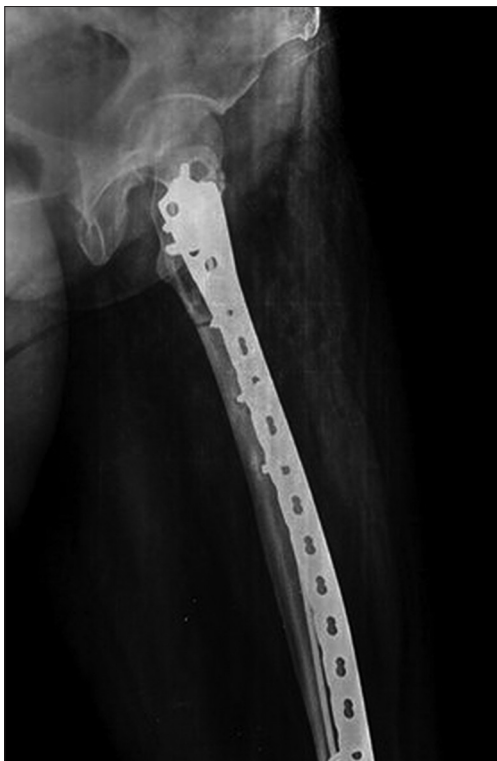

Figure 2: Lateral radiograph of the femur with hip joint showing the anterior curvature of the distal femoral locking compression plate, which matched the anterior bow of the femur

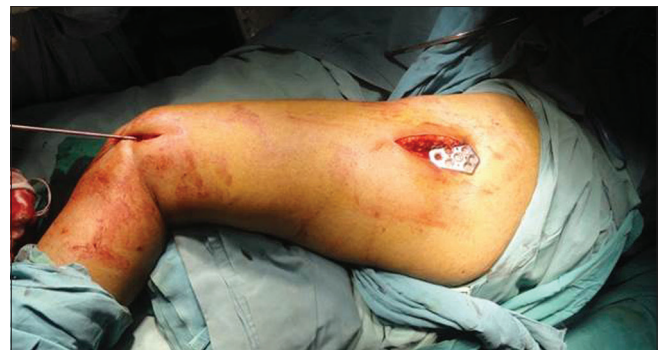

Figure 3: Clinical photograph showing primary fixation performed via a minimally invasive surgical approach. An elastic titanium nail with a diameter of 3 mm was used for reduction, and the plate was passed in minimally invasive manner

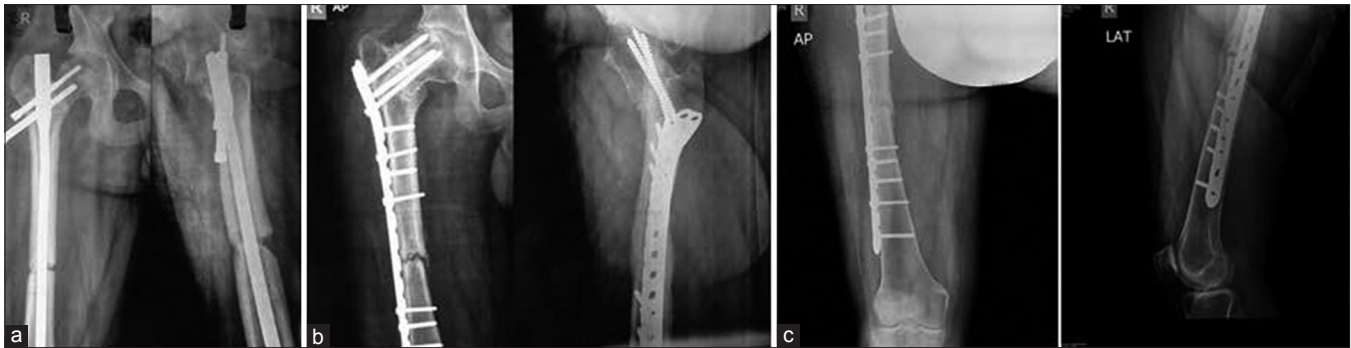


Figure 4: (a) Anteroposterior and lateral radiographs of a 22-year-old man showing nonunion of ipsilateral femoral neck and shaft fracture following four previous surgeries using a dynamic hip screw and a long proximal femoral nail. Due to repeated surgeries, the proximal femoral bone stock was inadequate. (b) After removal of the implant, autologous fibula bone grafting was performed in the femoral neck, followed by fixation with a reverse distal femoral locking compression plate. Radiographs at the 4-month followup show the union of the femoral neck fracture. However, the femoral shaft fracture shows delayed union. (c) Radiographs demonstrating union of the femoral shaft fracture at 3 months after bone grafting

autologous fibula into the neck to fill the large voids created by previous implants. Then fixation with reverse distal femoral LCP was done [Figure 4a-c]. The femoral neck fracture exhibited union within 4 months, whereas the femoral shaft fracture required bone grafting for delayed union at a second stage.

Some reports of the successful use of reverse DF LCP for proximal femoral fractures have been published.⁸⁻¹¹ Ma *et al.*⁹ recommended the use of a reverse, less-invasive stabilization system-DF (LISS-DF) plate for proximal femoral fractures that are unsuitable for femoral nailing. In their case series, they reported that complete union was achieved in twenty patients treated with reverse LISS, with an average followup of 24 months.

Furthermore, a comparative study of 46 patients with osteotomies for young adult hip pathology indicated that the reverse distal femoral LCP was stiffer, was easier to use, and provides increased screw placement options as compared to the standard proximal femoral locking plates.¹² A few comparative studies have evaluated the effectiveness of PFN and reverse LISS-DF plates for proximal femoral fractures. Han *et al.*¹³ concluded that the use of reverse LISS DCP more effectively avoided coxa vara and recommended its use for patients with very severe osteoporosis. Moreover, Haq *et al.*¹⁴ (2014) concluded that PFN was a better implant as compared to reverse distal femoral LCP for intertrochanteric fractures with a compromised lateral wall.

A limiting factor of the distal femoral plate is that the locking screw holes are oriented according to the distal femoral bone anatomy; hence, while inserting screws in the anteverted femoral neck, the lateral radiograph should be carefully evaluated intraoperatively. We recommend that the plate should be fixed first with unicortical conventional

screws in the distal fragment, which will allow the plate to be flipped in the coronal plane to facilitate the insertion of screws with the correct femoral neck anteversion. Thus, this limitation can be overcome by first applying the plate loosely to the bone, and then selecting an appropriate locking hole from one of the many options available for the proximal screw insertion. The different orientation of the screws helped us obtain good purchase in previously operated cases.

The limitation of our study is that it is a retrospective study with no control group and small number of patients.

To conclude, reverse distal femoral LCP of the contralateral side can be used as a salvage option for failed fixation of proximal femoral fractures exhibiting nonunion.

Financial support and sponsorship

Nil.

Conflicts of interest

There are no conflicts of interest.

REFERENCES

1. Sims SH. Subtrochanteric femur fractures. *Orthop Clin North Am* 2002;33:113-26, viii.
2. Craig NJ, Sivaji C, Maffulli N. Subtrochanteric fractures. A review of treatment options. *Bull Hosp Jt Dis* 2001;60:35-46.
3. de Vries JS, Kloen P, Borens O, Marti RK, Helfet DL. Treatment of subtrochanteric nonunions. *Injury* 2006;37:203-11.
4. Saarenpää I, Heikkinen T, Ristiniemi J, Hyvönen P, Leppilahti J, Jalovaara P. Functional comparison of the dynamic hip screw and the Gamma locking nail in trochanteric hip fractures: A matched-pair study of 268 patients. *Int Orthop* 2009;33:255-60.
5. Sehat K, Baker RP, Pattison G, Price R, Harries WJ, Chesser TJ. The use of the long gamma nail in proximal femoral fractures. *Injury* 2005;36:1350-4.

6. Uzun M, Ertürer E, Oztürk I, Akman S, Seçkin F, Özçelik IB. Long term radiographic complications following treatment of unstable intertrochanteric femoral fractures with the proximal femoral nail and effects on functional results. *Acta Orthop Traumatol Turc* 2009;43:457-63.
7. Takigami I, Matsumoto K, Ohara A, Yamanaka K, Naganawa T, Ohashi M, *et al.* Treatment of trochanteric fractures with the PFNA (proximal femoral nail antirotation) nail system – Report of early results. *Bull NYU Hosp Jt Dis* 2008;66:276-9.
8. Pryce Lewis JR, Ashcroft GP. Reverse LISS plating for proximal segmental femoral fractures in the polytrauma patient: A case report. *Injury* 2007;38:235-9.
9. Ma CH, Tu YK, Yu SW, Yen CY, Yeh JH, Wu CH. Reverse LISS plates for unstable proximal femoral fractures. *Injury* 2010;41:827-33.
10. Ehlinger M, Brinkert D, Besse J, Adam P, Arlettaz Y, Bonnomet F. Reversed anatomic distal femur locking plate for periprosthetic hip fracture fixation. *Orthop Traumatol Surg Res* 2011;97:560-4.
11. Ebraheim NA, Gomez C, Ramineni SK, Liu J. Fixation of periprosthetic femoral shaft fractures adjacent to a well-fixed femoral stem with reversed distal femoral locking plate. *J Trauma* 2009;66:1152-7.
12. MacLean SB, Evans S, O'Hara JN. A comparison of reversed locking compression-distal femoral plates and blade plates in osteotomies for young adult hip pathology. *Hip Int* 2013;23:565-9.
13. Han N, Sun GX, Li ZC, Li GF, Lu QY, Han QH, *et al.* Comparison of proximal femoral nail antirotation blade and reverse less invasive stabilization system-distal femur systems in the treatment of proximal femoral fractures. *Orthop Surg* 2011;3:7-13.
14. Haq RU, Manhas V, Pankaj A, Srivastava A, Dhammi IK, Jain AK. Proximal femoral nails compared with reverse distal femoral locking plates in intertrochanteric fractures with a compromised lateral wall; a randomised controlled trial. *Int Orthop* 2014;38:1443-9.