

Correlation between cervical lordosis and cervical disc herniation in young patients with neck pain

Kun Gao, MD^a, Jiliang Zhang, MS^b, Jinquan Lai, MS^b, Weidong Liu, MS^a, Hanqing Lyu, MS^a, Yihong Wu, MS^b, Zhanpeng Lin, MS^b, Yafei Cao, MD^{a,*}

Abstract

Abnormal cervical curvature and cervical disc herniation are closely related to neck pain and should be taken into account before any treatment. However, studies have rarely reported on the correlation between cervical lordosis and cervical disc herniation in patients with neck pain. Therefore, in this study, we collect young neck pain patients with abnormal cervical curvature to evaluate the relationship between cervical lordosis and cervical disc herniation.

Three hundred patients below 40 years old with neck pain were enrolled. Patient sex, age, apical vertebra, segment of intervertebral disc protrusion, sagittal diameter of spinal duramater, sagittal diameter of spinal canal, height of disc space were recorded, and the cervical curvature, and degree of cervical spinal cord compression (G/F ratio) were calculated. The change of degree of disc herniation and degree of cervical spinal cord compression were analyzed in different cervical curvature groups. Further more, collected these patients who had improved cervical curvature over a period of time, to compare the changes of degree of disc herniation, G/F ratio, and height of disc space.

The median age of patients with kyphosis was lower than those with lordosis and straight cervical spine. The degree of disc herniation was higher in the straight and kyphosis groups compared to the lordosis group. Cervical lordosis was inversely correlated with the degree of disc herniation and positively with G/F ratio. Cervical curvature was significantly affected by sex, age, and the degree of disc herniation. With the improvement of cervical lordotic curvature, the degree of disc herniation decreased and height of disc space increased.

The degree of disc herniation and cervical spinal cord compression are inversely correlated to cervical lordosis in young neck pain patients, and the degree of disc herniation and height of disc space can recover with the recovery of cervical lordotic curvature. These findings may indicating a link between cervical curvature and degenerative changes which have important clinical implications.

Abbreviations: G/F ratio = degree of cervical spinal cord compression, MRI = magnetic resonance imaging.

Keywords: cervical disc herniation, cervical lordosis, correlation, neck pain

1. Introduction

Chronic neck pain is a common affliction in middle-aged and elderly patients with 30% to 50% prevalence, and seriously affects their quality of life. The etiology of neck pain is complex

and possibly related to disc herniation, facet joints, muscles, and ligaments.^[1-2] Due to excessive movement of the cervical spine, long-term bad posture and lifestyle choices, and soft tissue damage in the neck, cervical stability gradually decreases and can lead to the loss of cervical lordosis.^[3]

Abnormal cervical curvature, including excessive or meagre cervical lordosis, loss of cervical curvature, kyphosis, and complex cervical curvature, is an early manifestation of degenerative changes in the spine.^[4] The normal cervical curvature is essential for maintaining balance and motor function, and any of the aforementioned abnormalities can destroy cervical spine structure, leading to biomechanical dysfunction, bone hyperplasia, cervical muscle injury, and ultimately cervical spondylosis.^[5-7] Therefore, it is very important to restore the normal cervical curvature while treating cervical spondylosis.

Cervical disc herniation should also be taken into account before any treatment since many patients with abnormal cervical curvature have accompanying disc herniation. In addition, the prevalence of disc herniation is reportedly 2% to 23% (median 11%) among asymptomatic volunteers.^[8] However, little is known regarding a potential relationship between cervical curvature abnormalities and disc herniation, or whether they affect each other. Therefore, the aim of this study was to evaluate the correlation between cervical lordosis and cervical disc herniation in patients with neck pain. Early observation of the severity of disc herniation can better guide clinical diagnosis and treatment, and prevent the aggravation of neck pain.

Editor: Anish Thachangattuthodi.

Shenzhen Science and Technology Project (JCYJ20150529150715499).

Sanming Project of Medicine in Shenzhen (NO.SZSM201812066).

All procedures performed in studies involving human participants were in accordance with the ethical standards of the institutional and/or national research committee and with the 1964 Helsinki declaration and its later amendments or comparable ethical standards.

The authors have no conflicts of interest to disclose.

^a Shenzhen Traditional Chinese Medicine Hospital, ^b The Fourth Clinical Medical College of Guangzhou University of Chinese Medicine, Shenzhen, China.

* Correspondence: Yafei Cao, Department of Orthopedics and Traumatology, Shenzhen Traditional Chinese Medicine Hospital, Shenzhen, 518033, China (e-mail: Caoyafei64@163.com).

Copyright © 2019 the Author(s). Published by Wolters Kluwer Health, Inc. This is an open access article distributed under the terms of the Creative Commons Attribution-Non Commercial-No Derivatives License 4.0 (CCBY-NC-ND), where it is permissible to download and share the work provided it is properly cited. The work cannot be changed in any way or used commercially without permission from the journal.

Medicine (2019) 98:31(e16545)

Received: 7 January 2019 / Received in final form: 9 June 2019 / Accepted: 28 June 2019

<http://dx.doi.org/10.1097/MD.00000000000016545>

2. Patients and methods

2.1. Patient characteristics

Three hundred patients (139 males and 161 females, mean age 31.44 ± 5.02 years, age range 16–40 years) with neck pain who were treated at the Department of Orthopedics, Shenzhen Hospital of Traditional Chinese Medicine between January 1, 2014 and August 31, 2018 were included in this cross-sectional study. Patients with congenital dysplasia, trauma, pathology, tumor, severe osteoporosis, and cervical spine surgery were excluded. In this study, written or verbal consent was obtained from all the patients. The study was approved by the ethics committee (EC) office of Guangzhou University of Chinese Medicine, and the rights of the subjects were protected.

2.2. Imaging and clinical assessment

All patients underwent cervical X-ray and magnetic resonance imaging (MRI) detection at the Medical Imaging Center, Shenzhen Hospital of Traditional Chinese Medicine. The X-rays were taken with the patients in a standing but comfortably neutral resting position. The following lines were drawn on the lateral radiographs of cervical vertebrae according to Borden's method^[4]: A—between posterior superior marginal of C2 odontoid process and posterior inferior edge of C7 vertebra, B—along the trailing edge of the cervical vertebrae, C—the longest distance between line A and B as the cervical curvature value, and D—apical vertebra (Fig. 1A). To determine the disc space heights in MRI, the following lines were drawn: E—between the inferior and superior end plate, F—the sagittal diameter of spinal canal, and G—the sagittal diameter of spinal dura mater (Fig. 1B). The degree of cervical spinal cord compression was calculated in terms of the G/F ratio. Finally, the line H was drawn on the transverse MRI section to determine the degree of disc herniation (Fig. 1C).

Based on the assessment of X-rays and MRIs, the apical vertebra, segment of intervertebral disc protrusion, the sagittal

diameter of spinal dura mater, the sagittal diameter of spinal canal, height of disc space, cervical curvature, and G/F ratio were calculated. Patients were then divided into 3 groups on the basis of cervical curvature: kyphotic: $C \leq 0$ mm, straight: $0 \text{ mm} < C \leq 7$ mm, and lordotic: $C > 7$ mm.

2.3. Statistical analysis

SPSS 19.0 software (SPSS Inc., Chicago, IL) was used for statistical analysis. Continuous data were expressed as the mean \pm standard deviation. Data with non-normal distribution were converted to the logarithmic form and compared by Mann–Whitney *U* tests. Normally distributed data were compared by independent Student *t* test. Categorical data were expressed in percentages and compared by chi-square test. Correlation between variables was determined by Pearson correlation and multivariate linear regression analysis. *P* values $< .05$ were considered statistically significant.

3. Results

3.1. Basic characteristics of all patients

The clinical characteristics of the patients are summarized in Table 1. Based on the cervical curvature, the patients were classified into the lordosis ($n = 96$), straight ($n = 99$) and kyphosis ($n = 105$) groups (Fig. 2). There were 201 segments of intervertebral disc herniation, including C3/4 (13), C4/5 (53), C5/6 (121), and C6/7 (14), and the apical vertebra were C4 (72), C5 (210), and C6 (18).

3.2. The degree of disc herniation was higher in loss lordosis patients

The median age of the kyphosis patients was lower compared to the lordosis and straight spine groups (30.38, 31.30, and 32.69 respectively). In addition, a higher number of female patients

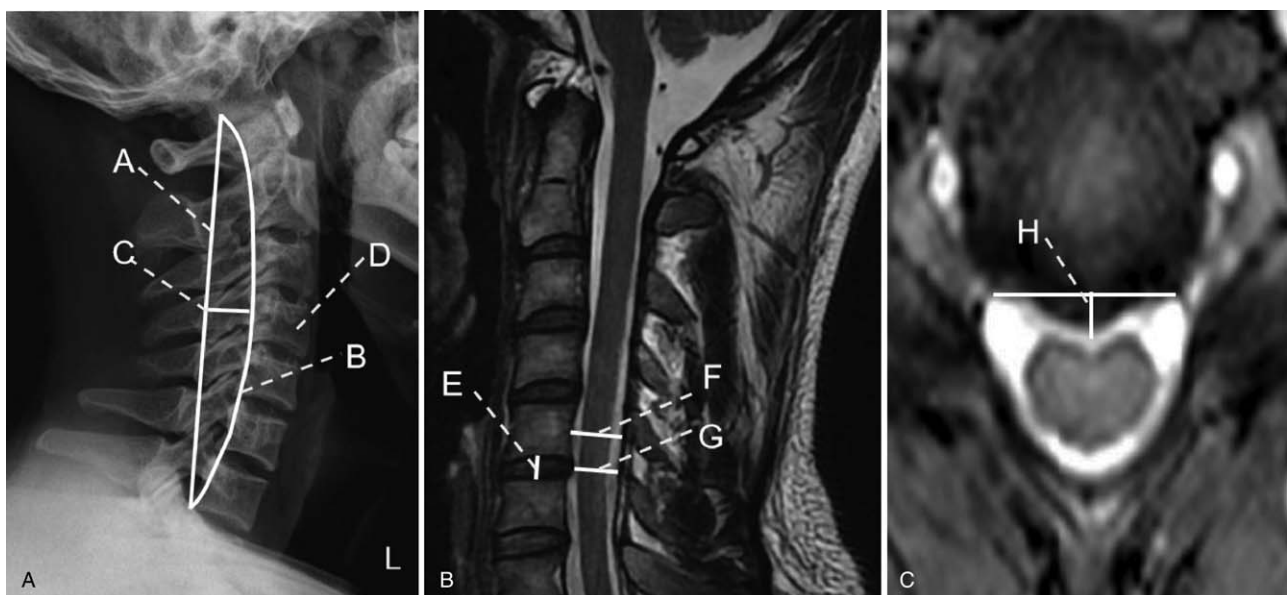


Figure 1. The lines drawn on each cervical spine radiograph. (A) lateral radiograph. (B) MRI at the sagittal position. (C) MRI of transverse section. MRI=magnetic resonance imaging.

Table 1
Basic clinical characteristics of all patients.

	Total (n=300)
Age, yr	31.44 ± 5.02
Gender (male/female)	139/161
Cervical curvature, n	
Lordosis	96
Straight	99
Kyphosis	105
Segment of intervertebral disc herniation, n	201
C3/4	13
C4/5	53
C5/6	121
C6/7	14
Apical vertebra	
C4	72
C5	210
C6	18

were seen in the straight (61.6%) and kyphosis groups (61.9%) compared to the lordosis group (36.5%). The degree of disc herniation in the straight (1.58 ± 1.49) and kyphosis (3.31 ± 1.50) groups were higher than that in the lordosis group (0.88 ± 1.31). The G/F ratio, which reflects the degree of cervical spine compression, showed a tendency to decrease with decreased cervical lordosis (median, 0.72 vs 0.66 vs 0.64, $P < .001$) (Table 2).

3.3. Correlation of cervical curvature with clinical variables

The correlation between the cervical curvature and clinical variables is summarized in Table 3, and shows an inverse correlation with the degree of disc herniation, and positive with G/F ratio ($r = -0.583$ and 0.315 , $P < .001$ and $< .001$ respectively). Multivariate linear regression analysis showed that cervical curvature was affected by sex, age, and the degree of disc herniation. The regression equation was $Y = 2.033 - 1.790X1 + 0.194X2 - 1.913X3$ ($R = -0.613$, $F = 29.333$, $P < .001$).

3.4. The degree of disc herniation and height of disc space recovered with the recovery of cervical curvature

We followed up the patients who showed improved cervical lordosis over a period of time and compared the different clinical variables between the first and last visits. It showed that a decreased degree of disc herniation was observed along with increased cervical lordosis (median, 2.58 vs 1.51, $P = .003$). Height of disc space in last visit (8.71 ± 9.59) were increased compared to that at the first visit (6.79 ± 1.06) ($P = .013$, Table 4). There was no significant change in the G/F ratio.

4. Discussion

Cervical lordosis is the first physiological curvature of the human spine, and due to its load-bearing function, a predominant site of disc herniation. It maintains the stability of the spine and is an important part of normal spinal biomechanics,^[8,9-10] in addition to cushioning the vibrations.^[11] In recent years, the lifestyle of the younger demography has become increasingly sedentary, with students and office workers spending long hours sitting in front of their computers, resulting in higher incidence of cervical

curvature abnormalities. Zhou studied 2106 Chinese teenagers with neck pain and reported 37 (61.67%), 430 (71.67%) and 1105 (76.42%) cases of abnormal cervical curvature in the 6 to 15 years, 16 to 25 years, and 26 to 35 years age groups respectively.^[12] Cui et al randomly selected 4681 students for cervical spine examination,^[13] and noted 1362 cases (29.1%) with abnormal curvature. Kang et al imaged 3261 patients with cervical spondylosis and found 1886 (57.81%) with abnormal cervical curvature.^[14] The latter can be measured by various means, such as Borden measurement, cervical curvature index (CCI), Cobb angle measurement, and tangent angle measurement of posterior edge of vertebral body.^[4] Since Borden measurement is the most widely used method at present and has the advantage of reproducibility in multiple operations,^[15] we used this method in our study as well. Although several studies have reported a relationship between sagittal alignment and intervertebral discs during cervical spine surgery, little is known regarding the degenerative changes of the cervical spine.^[16-19] In patients with high cervical lordosis, anterior cervical discectomy without fusion affects the sagittal alignment of the entire spine. Normalizing the angle of cervical lordosis can lead to reciprocal changes in pelvic tilt and sacral slope.^[16]

The main finding of this study was the inverse correlation between the degree of disc herniation and extent of cervical lordosis in neck pain patients, with smaller herniation accompanying increased lordosis. In addition, the degree of cervical spinal cord compression also increased with the decrease in cervical lordosis. This is the first report on such a correlation between cervical curvature and disc herniation in young patients. No study so far has been able to demonstrate whether the degenerative changes in the spine are the cause or effect of kyphosis. Han Jo Kim study found no correlation between cervical lordosis and cervical degeneration.^[18] During a 10-year follow-up study by Okada et al, posterior disk protrusion and decrease in the signal intensity of spinal discs were observed.^[20] In addition, subjects older than 40 years with non-lordosis type of sagittal alignment showed more frequent posterior disk protrusion. However, no significant correlation was detected between the sagittal alignment of the cervical spine and clinical symptoms.^[21-22] In contrast, we confirmed a strong correlation between cervical lordosis and disc herniation, which can greatly improve the diagnosis of cervical spondylosis (Table 3).

Interestingly, females tended to have less cervical lordosis compared males, although without any statistical significance, as reported by Ella Been et al^[23] Gender differences in the cervical lordosis are already apparent in children. Yukawa et al^[24] and Been et al^[25] found greater lower cervical lordosis (C2-C7) in males compared with females. Differences in the cervical lordosis angles might be related to gender differences in skull morphology, larynx, or thorax shape and size. In addition, the median age of the kyphosis patients was lower than the other groups, indicating that younger people are more likely to have severe loss of cervical lordosis. This contradicts studies reporting lack of any significant association between age and cervical lordotic curvature.^[19] The reason for this discrepancy could be the overall younger age of our cohort. Iorio et al reported a significant age-related increase in C2-C7 lordosis, C0-C7 lordosis and T1 slope, especially in subjects older than 55 years.^[26] Previous research found that the cervical lordosis is related to age. As reported that cervical lordosis becomes most pronounced with the development of the sitting position at age 9 months,^[27,28] and that the C3-C7

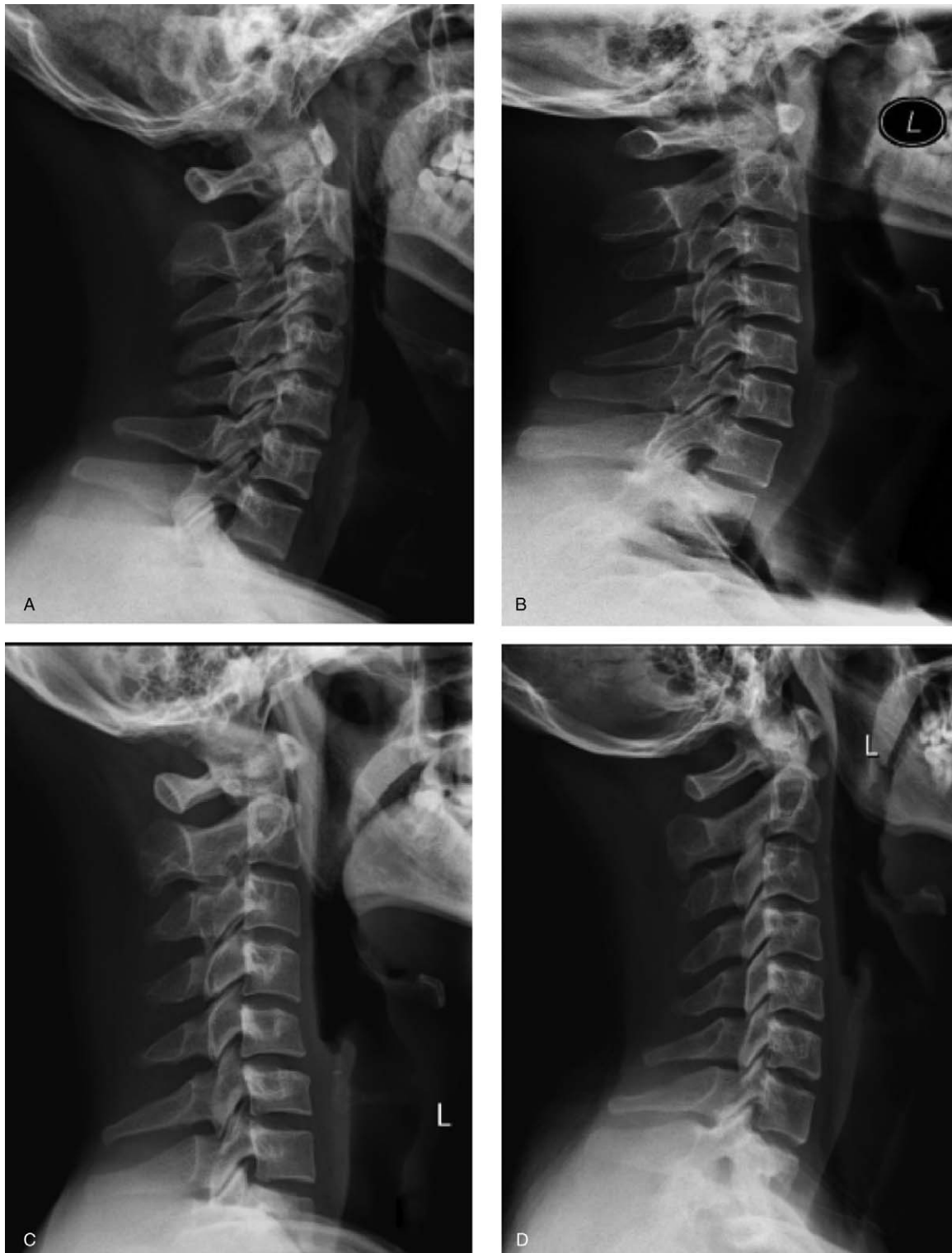

Figure 2. The type of cervical curvature according to the lateral cervical spine radiograph: (a) lordosis, (b) straight, (c) kyphosis, and (d) sigmoid.

lordosis angle reach adult like angles at age 14 to 15.^[29] Children had more lordotic C1–C7 angle and more kyphotic FM–C1 angle. As for the correlation between the cervical lordosis and degree of disc herniation. The physiological relationship of sex, age, degree of disc herniation needs further exploration. We

performed correlate analysis for age, gender, and degree of disc herniation. Single linear regression and bivariate correlation analysis all showed that degree of disc herniation was not significantly correlate with age and sex. We will discuss these aspects in the discussion of this article.

Table 2**Demographic findings of patients with lordosis, straight cervical spine and kyphosis.**

	lordosis (n=96)	straight (n=99)	kyphosis (n=105)	P
Age, yr	31.30±3.52	32.69±6.33	30.38±4.55	.014*
Gender (male/female)	61/35	38/61	40/65	.927
Cervical curvature, mm	8.04±1.36	2.32±2.28	-4.71±1.98	<.001*
Degree of disc herniation, mm	0.88±1.31	1.58±1.49	3.31±1.50	<.001*
G/F ratio	0.72±0.15	0.66±0.09	0.64±0.12	<.001*

* P<.05.

Table 3**The correlation of cervical curvature with age, sex, degree of disc herniation, G/F ratio, and disc space heights.**

Cervical curvature, mm	Age, yr		Sex (male/female)		Degree of disc herniation, mm		G/F ratio		Height of disc space	
	r	P	r	P	r	P	r	P	r	P
	0.141	.015*	-0.181	.002*	-0.583	.000*	0.315	<.001*	-0.165	.011*

* P<.05.

Table 4**Multivariate linear regression analysis of factors influencing cervical curvature.**

	B	SE	Beta	t	P	95% CI
Gender (male/female)	2.033	8.371		0.243	.808	-14.442-18.507
Age, yr	-1.790	0.534	-0.160	-3.351	.001	-2.481-0.739
Degree of disc herniation, mm	0.194	0.054	0.174	3.610	<.001	0.088-0.300
Sagittal diameter of spinal duramater, mm	-1.913	0.202	-0.607	-9.487	<.001	-2.310-1.516
Sagittal diameter of spinal canal, mm	0.144	0.668	0.037	0.216	.829	-1.171-1.460
G/F ratio	-0.600	0.910	-0.192	-0.660	.510	-2.391-1.191
G/F ratio	5.352	10.827	0.123	0.494	.621	-15.957-26.661

The heights of disc space in the straight cervical spine group were greater compared to the other groups, which could be due to the fact that we measured the central position of the upper and lower endplates. We also observed that some patients showed improvements in cervical kyphosis after treatment, rest or exercise, and found that the degree of disc herniation was decreased and the heights of disc space were increased after their last follow-up compared to the first visit (Table 5). These results strongly indicate that restoring the cervical curvature is vital for improving cervical disc herniation.

The mechanism of the loss of cervical lordosis remains unclear, although some studies hint at the association between the neck muscles and disc compression.^[30-31,22] Alpayci et al found that the loss of cervical lordosis severely affected neck extensors more than the neck flexors in neck pain patients, although it is not possible to determine the timing of abnormal curvature and disc herniation.^[30] The degenerative cascade can cause desiccation of the intervertebral disc resulting in height loss. If the load balance

and lordosis are not restored, the altered cervical curvature will eventually progress to kyphosis.^[32-33]

Our study has several limitations that should be addressed. First, we did not analyze the mechanism underlying the correlation between abnormal cervical curvature and cervical disc herniation, and second, this was a single center study on a small patient cohort. Our findings, therefore, need to be validated in multicenter studies with larger cohorts. In addition, longitudinal and molecular studies are needed to further explore the mechanism of abnormal cervical curvature and cervical disc herniation.

In conclusion, our study is the first to show that the degree of disc herniation and cervical spinal cord compression are inversely correlated to cervical lordosis in young neck pain patients, and the degree of disc herniation and height of disc space can recover with the recovery of cervical curvature. These findings provide new insights into the relationship between cervical curvature and spinal degeneration and can improve the clinical management of chronic neck pain.

Table 5**Comparison of variables between first visit and last visit.**

	First visit (n=47)	Last visit (n=47)	P
Cervical curvature, mm	-0.47±3.49	1.49±3.14	.006*
Degree of disc herniation, mm	2.58±1.64	1.51±1.55	.003*
G/F ratio	0.62±0.12	0.67±0.10	.062
Height of disc space	6.79±1.06	8.71±9.59	.013*

* P<.05.

Author contributions**Conceptualization:** Yafei Cao.**Data curation:** Kun Gao, Jiliang Zhang, Jinquan Lai, Weidong Liu, Hanqing Lyu, Yihong Wu, Zhanpeng Lin.**Formal analysis:** Kun Gao, Hanqing Lyu.**Investigation:** Kun Gao, Jiliang Zhang, Jinquan Lai, Weidong Liu, Yihong Wu, Zhanpeng Lin.**Methodology:** Kun Gao.

Project administration: Yafei Cao.

Supervision: Yafei Cao.

Writing – original draft: Kun Gao.

Writing – review & editing: Kun Gao.

Yafei Cao orcid: 0000-0001-9193-376X.

References

- [1] Cohen SP. Epidemiology, diagnosis, and treatment of neck pain. *Mayo Clin Proc* 2015;90:284–99.
- [2] Cohen SP, Hooten WM. Advances in the diagnosis and management of neck pain. *BMJ* 2017;358:j3221.
- [3] McAviney J, Schulz D, Bock R, et al. Determining the relationship between cervical lordosis and neck complaints. *J Manip Physiol Ther* 2005;28:187–93.
- [4] Borden AG, Rechtman AM, Gershon-Cohen J. The normal cervical lordosis. *Radiology* 1960;74:806–9.
- [5] Ferracini GN, Chaves TC, Dach F, et al. Analysis of the cranio-cervical curvatures in subjects with migraine with and without neck pain. *Physiotherapy* 2017;103:392–9.
- [6] Godlewski B, Stachura MK, Czepko RA, et al. Analysis of changes in cervical spinal curvature and intervertebral disk space height following ACDF surgery in a group of 100 patients followed up for 12 months. *J Clin Neurosci* 2018;52:92–9.
- [7] Grob D, Frauenfelder H, Mannion AF. The association between cervical spine curvature and neck pain. *Eur Spine J* 2007;16:669–78.
- [8] Matsumoto M, Fujimura Y, Suzuki N, et al. MRI of cervical intervertebral discs in asymptomatic subjects. *J Bone Joint Surg Br* 1998;80:19–24.
- [9] Guo G, Li J, Diao Q, et al. Cervical lordosis in asymptomatic individuals: a meta-analysis. *J Orthop Surg Res* 2018;13:147.
- [10] Lee TH, Kim SJ, Lim SM. Prevalence of disc degeneration in asymptomatic Korean subjects. Part 2: cervical spine. *J Korean Neurosurg S* 2008;8:420–8.
- [11] Ferrara LA. The biomechanics of cervical spondylosis. *Adv Orthoped* 2012;2012:1–5.
- [12] Shujuan Z, Songshan L, Kai X, et al. Clinical analysis of changes of cervical vertebral physiological curvature in adolescents of different ages. *Henan Trad Chin Med* 2017;1398–401.
- [13] Lijin C, Yongfeng H, Guoyun Z, et al. Investigation on cervical spondylosis health of primary and secondary school students in central district of Wuhan. *J External Ther Trad Chin Med* 2011;3:48–50.
- [14] Yuguo Kang. Epidemiological study on abnormal cervical curvature. *Chin J Health Manag* 2011;05:361–2.
- [15] Chao W, Huiliang S, Zhao L, et al. Consistency between Borden's method and Harrison's method in measuring cervical curvature. *Chin J Spinal Cord* 2012;1:34–6.
- [16] Donk RD, Arnts H, Verhagen WIM, et al. Cervical sagittal alignment after different anterior discectomy procedures for single-level cervical degenerative disc disease: randomized controlled trial. *Acta Neurochir* 2017;159:2359–65.
- [17] Edwards CC, Riew KD, Anderson PA, et al. Cervical myelopathy: current diagnostic and treatment strategies. *Spine J* 2003;3:68–81.
- [18] Jagannathan J, Shaffrey CI, Oskouian RJ, et al. Radiographic and clinical outcomes following single-level anterior cervical discectomy and allograft fusion without plate placement or cervical collar. *J Neurosurg Spine* 2008;8:420.
- [19] Kim JH, Park JY, Yi S, et al. Anterior cervical discectomy and fusion alters whole-spine sagittal alignment. *Yonsei Med J* 2015;56:1060–70.
- [20] Kim HJM, Lenke LGM, Oshima YM, et al. Cervical lordosis actually increases with aging and progressive degeneration in spinal deformity patients. *Spine Deformity* 2014;2:410–4.
- [21] Okada E, Matsumoto M, Ichihara D, et al. Aging of the cervical spine in healthy volunteers: a 10-year longitudinal magnetic resonance imaging study. *Spine (Phila Pa 1976)* 2009;34:706–12.
- [22] Yoon SY, Moon HI, Lee SC, et al. Association between cervical lordotic curvature and cervical muscle cross-sectional area in patients with loss of cervical lordosis. *Clin Anat* 2018;31:710–5.
- [23] Been E, Shefi S, Soudack M. Cervical lordosis: the effect of age and gender. *The Spine Journal* 2017;17:880–8.
- [24] Yukawa Y, Kato F, Suda K, et al. Age-related changes in osseous anatomy, alignment, and range of motion of the cervical spine. Part I: radiographic data from over 1,200 asymptomatic subjects. *Eur Spine J* 2012;21:1492–8.
- [25] Been E, Shefi S, Zilka LR, et al. Foramen magnum orientation and its association with cervical lordosis: a model for reconstructing cervical curvature in archeological and extinct hominin specimens. *Advances Anthropol* 2014;4:133–40.
- [26] Iorio J, Lafage V, Lafage R, et al. The effect of aging on cervical parameters in a normative North American population. *Global Spine J* 2018;8:709–15.
- [27] Bagnall KM, Harris PF, Jones PR. A radiographic study of the human fetal spine. The development of the secondary cervical curvature. *J Anat* 1977;124:791–802.
- [28] Schnitzlein HN. Basic and clinical anatomy of the spine, spinal cord, and ANS. *Clin Anat* 2015;11:141–141.
- [29] Kasai T, Ikata T, Katoh S, et al. Growth of the cervical spine with special reference to its lordosis and mobility. *Spine* 1996;21:2067–73.
- [30] Alpayci M, Şenköy E, Delen V, et al. Decreased neck muscle strength in patients with the loss of cervical lordosis. *Clin Biomech* 2016;33: 98–102.
- [31] De Pauw R, Coppieters I, Kregel J, et al. Does muscle morphology change in chronic neck pain patients? A systematic review. *Manual Ther* 2016;22:42–9.
- [32] Ando E, Shigeta Y, Hirabayashi R, et al. Cervical curvature variations in patients with infraocclusion. *J Oral Rehabil* 2014;41:601–7.
- [33] Kim C, Lee S, Lim S, et al. Impact of fat infiltration in cervical extensor muscles on cervical lordosis and neck pain: a cross-sectional study. *Clin Orthop Surg* 2018;10:197–203.