

Open Access

Endoscopic Treatment of Various Gastrointestinal Tract Defects with an Over-the-Scope Clip: Case Series from a Tertiary Referral Hospital

Woong Cheul Lee, Weon Jin Ko, Jun-Hyung Cho, Tae Hee Lee, Seong Ran Jeon, Hyun Gun Kim and Joo Young Cho

Digestive Disease Center, Soonchunhyang University Hospital, Seoul, Korea

Recently, increasingly invasive therapeutic endoscopic procedures and more complex gastrointestinal surgeries such as endoscopic mucosal resection, endoscopic submucosal dissection, and novel laparoscopic approaches have resulted in endoscopists being confronted more frequently with perforations, fistulas, and anastomotic leakages, for which nonsurgical closure is desired. In this article, we present our experiences with the use of over-the-scope clip (OTSC) for natural orifice transluminal endoscopic surgery (NOTES) closure, prevention of perforation, anastomotic leakages, and fistula closures. The OTSC is a valuable device for closing intestinal perforations and fistulas, for NOTES closure, and for the prevention of perforation after the excision of a tumor from the proper muscle layer. Furthermore, it seems to be quite safe to perform, even by endoscopists with little experience of the technique.

Key Words: Over-the-scope clip; Natural orifice endoscopic surgery; Fistula; Subepithelial tumor; Anastomosis

INTRODUCTION

With the advancement of therapeutic endoscopy and complex surgical procedures based on new therapeutic techniques and devices, both endoscopists and surgeons are being more frequently confronted with clinical complications such as gastrointestinal (GI) perforation, fistulas, and anastomotic leakages. The surgical management of such complications is often difficult and time consuming, and the related morbidity and mortality may be as high as 5% to 30% in emergency situations.¹ Nonsurgical management of GI perforation and postoperative fistulas has also been attempted using various devices such as through-the-scope endoclips, endoloops, and covered self-expandable metal stents.²⁻⁴ However, the success rate of such procedures varies (55% to 69%)³ and additional surgical management is often required. Recently, a new over-

the-scope clip (OTSC) system (Ovesco Endoscopy AG, Tübingen, Germany) has been designed to create full-thickness closure by using an OTSC made of a superelastic, shape-memory alloy (nitinol) that takes its former unbent shape after the clip is released. The OTSC has been successfully used for the primary nonsurgical closure of GI tract perforations and fistulas.^{5,6} In an experimental setup, other indications such as closure of gastrostomy sites for natural orifice transluminal endoscopic surgery (NOTES) procedures have been evaluated.⁷⁻⁹ However, only limited data have been published concerning the clinical outcome of the application of the OTSC. In this article, we present our experiences with the OTSC in the treatment of GI leaks and fistulas, prevention perforation, and closure of NOTES gastrostomy sites (Table 1). The clinical significance of the OTSC system has already been demonstrated in several case series and articles. However, these reports have mainly been from the West and there are limited or no existing Eastern studies to our knowledge.

Received: February 5, 2013 Revised: March 28, 2013

Accepted: March 28, 2013

Correspondence: Joo Young Cho
Digestive Disease Center, Soonchunhyang University Hospital, 59 Daesagwan-ro, Yongsan-gu, Seoul 140-743, Korea
Tel: +82-2-709-9202, **Fax:** +82-2-709-9696, **E-mail:** cjy6695@dreamwiz.com

© This is an Open Access article distributed under the terms of the Creative Commons Attribution Non-Commercial License (<http://creativecommons.org/licenses/by-nc/3.0>) which permits unrestricted non-commercial use, distribution, and reproduction in any medium, provided the original work is properly cited.

CASE REPORT

Anastomosis site leakage closure

A 47-year-old male patient who had undergone minigastric

bypass for diabetes mellitus experienced anastomotic site leakage. Despite a successful surgical repair, he developed additional leakage at multiple sites, including a jejunocutaneous fistula. Furthermore, he developed a delayed allergic response to vicryl. We decided to use the OTSC system for fistula closure. Gastroduodenoscopy with the OTSC system was performed with fluoroscopic guidance with the patient under

conscious sedation. A total of three fistulas were identified and successfully closed during three separate sessions, each with a single OTSC. The patient was discharged with no further complications.

A 32-year-old woman underwent sleeve gastrectomy for morbid obesity. Two weeks after the gastrectomy, computed tomographic (CT) scans revealed a large intraperitoneal ab-

Table 1. Demographic and Clinical Data for Patients Undergoing Over-the-Scope Clip Placement

Case, age/sex	Size of defect, mm	No. of clips (type)	Location	Indication
47/M	8, 10, 10	3 (nontraumatic)	Anastomosis	Anastomosis site leak closure
32/F	10	1 (nontraumatic)	Anastomosis	Anastomosis site leak closure
56/M	12	1 (nontraumatic)	Colon fistula	Fistula closure
50/M	30	3 (traumatic)	Gastric angle	NOTES closure
57/M	10	1 (nontraumatic)	Gastric cardia	Tumorectomy, prevention of perforation

M, male; F, female; NOTES, natural orifice transluminal endoscopic surgery.

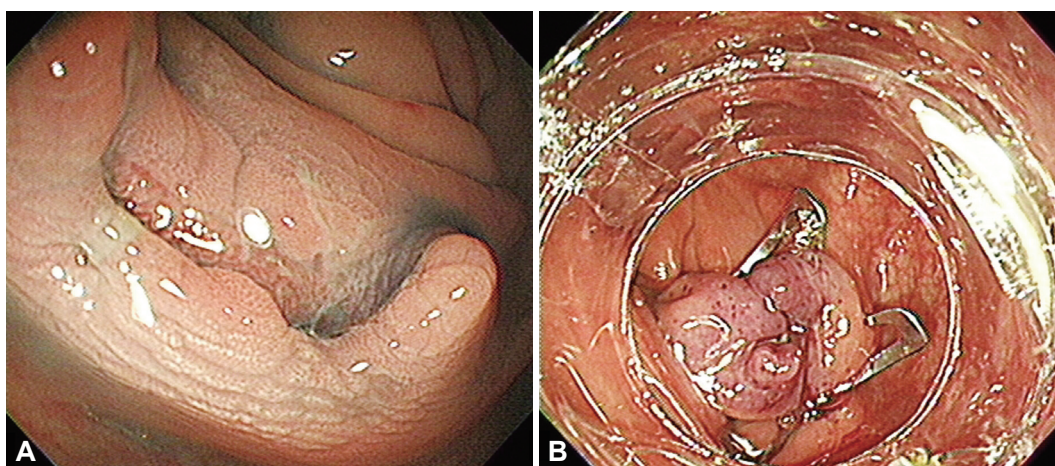


Fig. 1. (A) Colonoscopic findings of dye leakage from a colon fistula on the transverse colon. (B) No dye leakage occurred after over-the-scope clip closure.

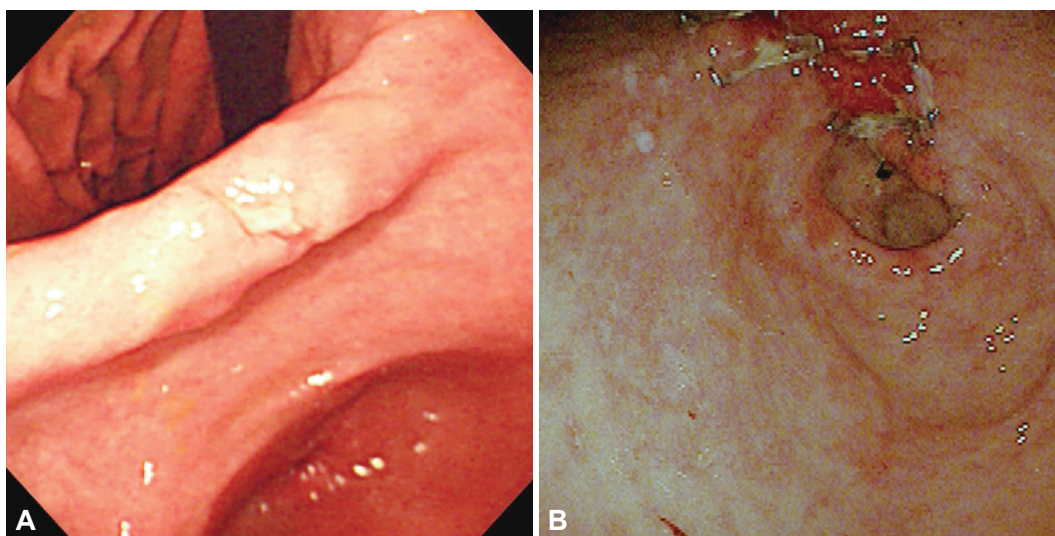


Fig. 2. (A) Endoscopic findings of early gastric cancer with submucosal invasion located on the angle. (B) Postendoscopic full-thickness gastric resection and closure with three over-the-scope clips.

cess due to anastomotic leakage at the esophagogastric junction. After percutaneous drainage of the abscess, we decided to use the OTSC system for primary closure. The fistula opening was approximately 10 mm wide. One OTSC was placed, successfully sealing the deficit, as confirmed by the introduction of gastrografin under fluoroscopy.

Inflammatory fistula closure

A 56-year-old man presented with fever and abdominal pain. He had been treated 2 months previously for necrotizing pancreatitis and a pancreatic pseudocyst, which was drained percutaneously. On admission, a colonopseudocystic fistula was detected by using contrast fluoroscopy. After identification of the fistula opening by using both indigo carmine dye and contrast, the OTSC system was used for primary closure of the fistula tract. A single t-type OTSC, with only suction applied, was used to completely seal the fistula. The fistula was completely healed after 5 days (Fig. 1).

NOTES closure

A 50-year-old man underwent endoscopic full-thickness gastric resection (EFTGR) for early gastric cancer. He had a history of chronic hepatitis B and had undergone transarterial chemoembolization for hepatoma. His tumor stage was T1bN0M0 according to endoscopic ultrasonography and abdominal CT findings. Although radical gastrectomy with nodal dissection is the standard treatment, we performed EFTGR with OTSC closure considering his comorbidities and surgical risk. After the EFTGR, the size of the gastric opening was approximately 30 mm. With laparoscopic guidance, we used an OTSC twin grasper to approximate the opposing margins of the opening and three t-type OTSCs for closure. Successful closure was confirmed by performing a leak test with indigo carmine dye and room air. Three days later, we performed an upper GI series with gastrografin. The seal at the opening was confirmed with the introduction of gastrografin under fluoroscopy. The patient was discharged 13 days later with no complications (Fig. 2).

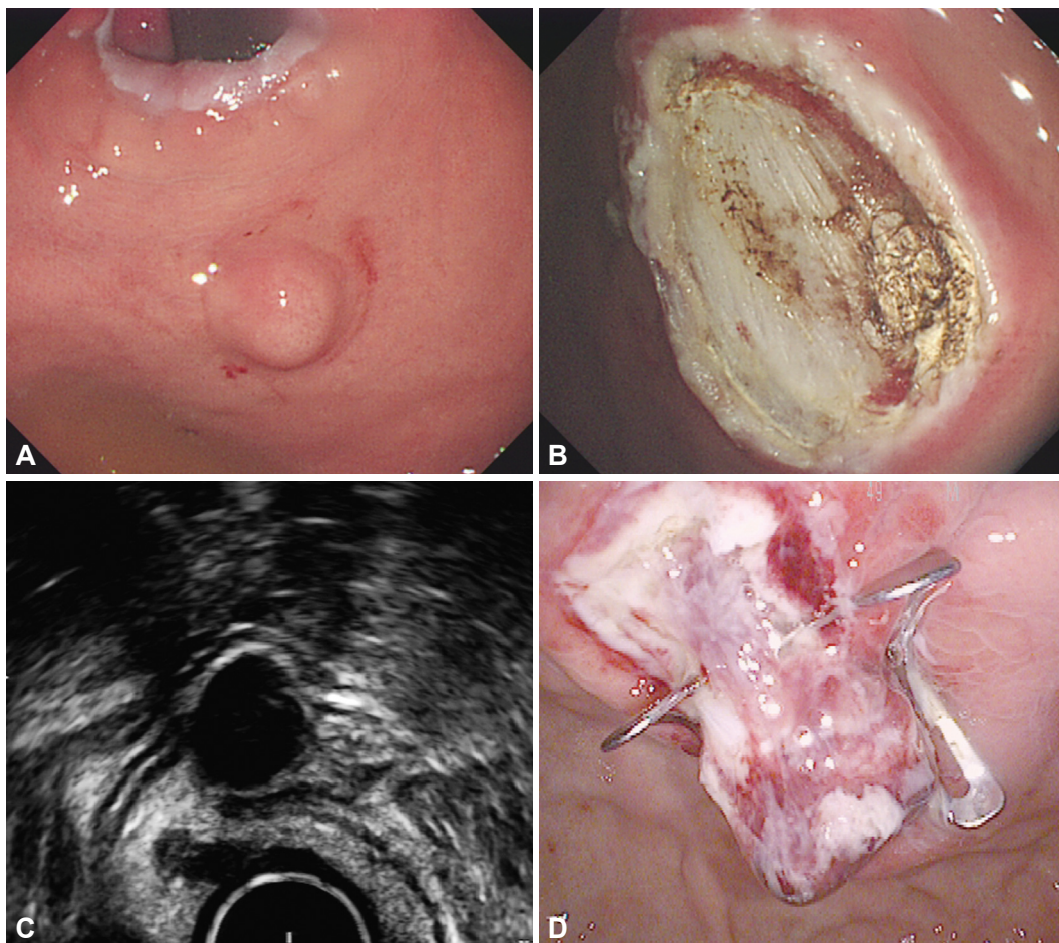


Fig. 3. (A) Endoscopic findings of a subepithelial tumor on the cardia. (B) The proper muscle layer is visibly exposed after tumorectomy. (C) Endoscopic ultrasonography findings of tumor raised from the proper muscle layer. (D) One over-the-scope clip was placed on the tumorectomy lesion to prevent perforation.

Prevention of perforation

A 57-year-old man underwent endoscopic *en bloc* resection for a gastric subepithelial tumor (SET) involving the muscle layer. The preresection diagnosis was a leiomyoma or a GI stromal tumor. The 1.2-cm tumor was removed by performing conventional endoscopic mucosal resection with a standard endoscopic snare. However, after resection, the muscularis proper was exposed at the base of the tumor. Because of the possible risk of delayed perforation, we decided to use the OTSC to prevent perforation. We used the OTSC twin grasper to grasp both ends of the resection margin, then successfully closed the wound with a t-type OTSC. Two days later, we performed gastroduodenoscopy. The lesion was completely sealed by using the OTSC, and the patient was discharged the following day (Fig. 3).

DISCUSSION

The OTSC has been successfully used to treat fistulas, deep wall defects, and perforations after endoscopic procedures.^{5,6} The OTSC system is easy to handle, and no noteworthy complications have been reported to date. In our series, all three patients with fistulas were successfully treated with only the OTSC system. In all cases, an operation was avoided. Although several animal studies have demonstrated the efficacy of the OTSC system for NOTES entry site closure,^{7,9,10} data supporting the use of the OTSC to close perforations in clinical practice are still limited. Our experience in a limited number of cases within a single center has confirmed the preliminary observations reported in the smaller series, and shown favorable results in terms of both outcomes and adverse effects.

From our experience, there are three possible indications for the use of this system besides management of bleeding. The first and most obvious indication is primary nonsurgical closure of postsurgical and postinflammatory fistulas. As in our first three cases, the OTSC system achieved complete closure of various fistulas with conscious sedation and without significant complications. Another potential indication of the OTSC system is NOTES closure. Previously, most authorities have used a hybrid approach for endoscopic full-thickness resection.¹¹ Thus, in EFTGR, closure was usually performed laparoscopically. With the OTSC system, pure NOTES may be feasible depending on the size of the defect. Although there are no reliable data about the maximal defect size that can be closed with the OTSC system, limited reports have suggested that a defect larger than 2.5 cm may be difficult to manage.⁶ In our series, the defect size was 30 mm and three clips were used for a successful closure. However, it should be noted that one or at the most two clips are more desirable as there is a risk of a gap between adjacent clips. Finally, the OTSC system can

be used for the closure and prevention of perforation after endoscopic resection of deep-seated SETs in the proper muscle layer. Endoscopic submucosal dissection and enucleation are more frequently being used for the diagnosis and treatment of SETs.¹² Complications of such interventions include perforation, especially for deep-seated SETs of the fourth hypoechoic endosonographic layer. As in our final case, the OTSC system may be used for the management of perforation and for closure of the defect, therefore preventing delayed perforation, which sometimes occurs as a result of coagulation damage to the deeper layers of the GI tract wall.

For using the OTSC system, we suggest that if the size of perforation or fistula is larger than the diameter of the OTSC, the operator should line up and placed as close as possible two or more OTSCs to prevent leakage.

In summary, the OTSC system seems to be a safe, simple, and valuable device for the primary closure of GI perforations and fistulas, and may have future indications for NOTES closure and prevention of perforation after endoscopic resections involving the proper muscle layer.

Conflicts of Interest

The authors have no financial conflicts of interest.

Acknowledgments

This work was supported in part by the Soonchunhyang University Research Fund.

REFERENCES

- Lüning TH, Keemers-Gels ME, Barendregt WB, Tan AC, Rosman C. Colonoscopic perforations: a review of 30,366 patients. *Surg Endosc* 2007;21:994-997.
- Yoshikane H, Hidano H, Sakakibara A, et al. Endoscopic repair by clipping of iatrogenic colonic perforation. *Gastrointest Endosc* 1997; 46:464-466.
- Trecca A, Gaj F, Gagliardi G. Our experience with endoscopic repair of large colonoscopic perforations and review of the literature. *Tech Coloproctol* 2008;12:315-321.
- Blackmon SH, Santora R, Schwarz P, Barroso A, Dunkin BJ. Utility of removable esophageal covered self-expanding metal stents for leak and fistula management. *Ann Thorac Surg* 2010;89:931-936.
- Repici A, Arezzo A, De Caro G, et al. Clinical experience with a new endoscopic over-the-scope clip system for use in the GI tract. *Dig Liver Dis* 2009;41:406-410.
- Kirschniak A, Kratt T, Stüker D, Braun A, Schurr MO, Königsrainer A. A new endoscopic over-the-scope clip system for treatment of lesions and bleeding in the GI tract: first clinical experiences. *Gastrointest Endosc* 2007;66:162-167.
- Arezzo A, Kratt T, Schurr MO, Morino M. Laparoscopic-assisted transgastric cholecystectomy and secure endoscopic closure of the transgastric defect in a survival porcine model. *Endoscopy* 2009;41: 767-772.
- Kratt T, Küper M, Traub F, et al. Feasibility study for secure closure of natural orifice transluminal endoscopic surgery gastrotomies by using over-the-scope clips. *Gastrointest Endosc* 2008;68:993-996.
- Voermans RP, van Berge Henegouwen MI, Bemelman WA, Fockens P. Novel over-the-scope-clip system for gastrotomy closure in natural orifice transluminal endoscopic surgery (NOTES): an ex vivo comparison

- study. *Endoscopy* 2009;41:1052-1055.
10. Von Renteln D, Vassiliou MC, Rothstein RI. Randomized controlled trial comparing endoscopic clips and over-the-scope clips for closure of natural orifice transluminal endoscopic surgery gastrotomies. *Endoscopy* 2009;41:1056-1061.
 11. Cho WY, Kim YJ, Cho JY, et al. Hybrid natural orifice transluminal endoscopic surgery. Endoscopic full-thickness resection of early gastric cancer and laparoscopic regional lymph node dissection: 14 human cases. *Endoscopy* 2011;43:134-139.
 12. Chu YY, Lien JM, Tsai MH, et al. Modified endoscopic submucosal dissection with enucleation for treatment of gastric subepithelial tumors originating from the muscularis propria layer. *BMC Gastroenterol* 2012;12:124.