

CASE REPORT

Open Access



Omental torsion mimicking acute appendicitis in a 7-year-old boy: a case report

Elham Khalili^{1,2}, Mahdis Marashi³, Majid Safarpanah⁴, Saeedeh Majidi⁵ and Zahra Ghaeini Hesarooeyeh^{1*}

Abstract

Background: Torsion of the greater omentum is an uncommon cause of acute abdominal pain. Omental torsion can be divided into primary and secondary. Owing to its nonspecific abdominal pain, preoperative diagnosis is difficult. Ultrasound sonography and abdominal computed tomography scans do not have a major role in preoperative diagnosis. The definite diagnosis is usually made during operation.

Case presentation: A 7-year-old Persian boy was referred with right lower quadrant pain associated with nausea and vomiting. Laboratory blood tests and urinalysis were requested that revealed normal values. Ultrasonography was performed, revealing inflammatory changes with mild free fluid collection in the interloop. The patient underwent an open appendectomy, confirming a normal appendix with omental torsion. Two days later, he was discharged home without postoperative complications.

Conclusions: In patients with acute abdomen, particularly those with acute appendicitis symptoms, omental torsion should be considered in the differential diagnosis.

Keywords: Omentum, Torsion abnormalities, Acute abdomen, Case report

Introduction

Omental torsion is a rare cause of acute abdomen [1] that results from omental rotation on its long axis, leading to a decreased blood supply and tissue infarction. Omental torsion mainly affects adults more than children, but its incidence has increased recently because of the widespread prevalence of obesity [2]. As Eitel had described for the first time in 1899, preoperative diagnosis of omental torsion is challenging because clinical symptoms and signs mimic other causes of abdominal pain, especially acute appendicitis. Omental torsion complications include intraperitoneal abscess, peritonitis, intraperitoneal bleeding, and rupture [3]. Surgical exploration is the gold-standard method for diagnosis [4]. In this case report, we describe a case of omental torsion

in a 7-year-old boy presenting with symptoms of acute appendicitis.

Case presentation

A 7-year-old Persian boy was referred to the emergency room with complaint of abdominal pain. His symptoms had started 2 days ago in the right lower quadrant and gradually increased, accompanied with nausea and vomiting.

He was fully vaccinated, had no significant family, social, or environmental history and had normal growth and development with no history of previous illness.

The child was not ill, and his vital signs included blood pressure of 111/720 mmHg, pulse rate of 75 beats per minute, respiratory rate of 17 breaths per minute, and temperature of 37 °C. Abdominal examination revealed right lower quadrant tenderness and rebound tenderness, while other parts of the abdomen had no pain or tenderness. There were no other findings on physical and neurological examination.

*Correspondence: zahrghaeini98@gmail.com

¹ Student Research Committee, Faculty of Medicine, Hormozgan University of Medical Sciences, Bandar Abbas, Iran
Full list of author information is available at the end of the article



Laboratory tests such as complete blood count and liver function tests revealed normal values as follows: white blood cells $6.7 \times 10^3/\mu\text{L}$ ($4.5\text{--}11 \times 10^3/\mu\text{L}$) (neutrophils 58%, lymphocytes 31%); red blood cells $4.77 \times 10^6/\mu\text{L}$ ($4.7\text{--}6.1 \times 10^6/\mu\text{L}$); hemoglobin 10.1 g/dL (11.2–14.5 g/dL); hematocrit 33% (39–50%); mean corpuscular volume 69.2 fL (80–100 fL); red cell distribution width 17% (11.5–15%); platelets $294 \times 10^3/\mu\text{L}$ ($150\text{--}450 \times 10^3/\mu\text{L}$); aspartate aminotransferase 22 U/L (8–33 U/L); alanine transaminase 27 U/L (7–55 U/L).

Ultrasonography revealed enhanced pericecal fat echogenicity due to the inflammatory changes with mild free fluid collection in the interloop (Fig. 1). The patient underwent a diagnostic laparotomy with suspicious of acute appendicitis with a Lanz incision. The laparotomy, however, revealed a normal-appearing appendix, and greater omentum torsion was visually determined (Fig. 2). The incision was not extended, and laparotomic appendectomy and omentectomy were done through Lanz incision. The pathology report noted a creamy normal appendix, measuring 6 cm in length and 0.5 cm in greatest diameter. Omentum pathology was reported as fibroconnective tissue with congestion.

The patient was nil per os (NPO) after hospitalization. We hydrated the patient with stat 300 cc lactate Ringer and 600 cc dextrose 5% in 0.9% sodium chloride once every 8 hours. Antibiotic therapy include ceftriaxone 750 mg twice a day, metronidazole 300 mg every 8 hours, and analgesic [Apotel as needed (PRN)] was prescribed intravenously. After surgery, the patient’s symptoms were ameliorated and he was discharged from the hospital 2 days later. Oral medication including metronidazole,

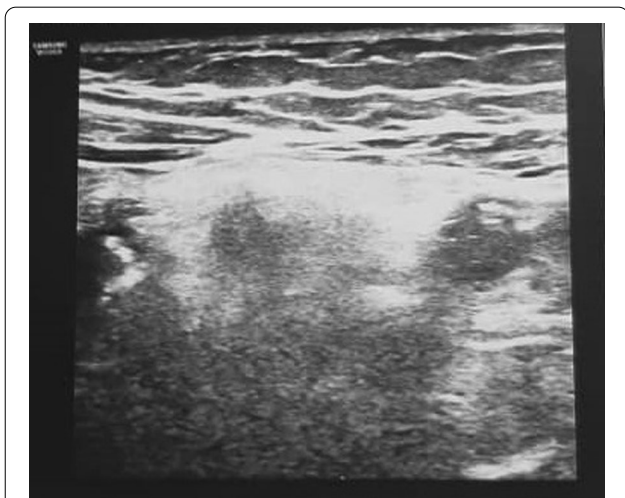

Fig. 1 Ultrasonography showing hyperechogenicity of pericecal fat with mild free fluid in the interloop at the site of tenderness in the right lower quadrant

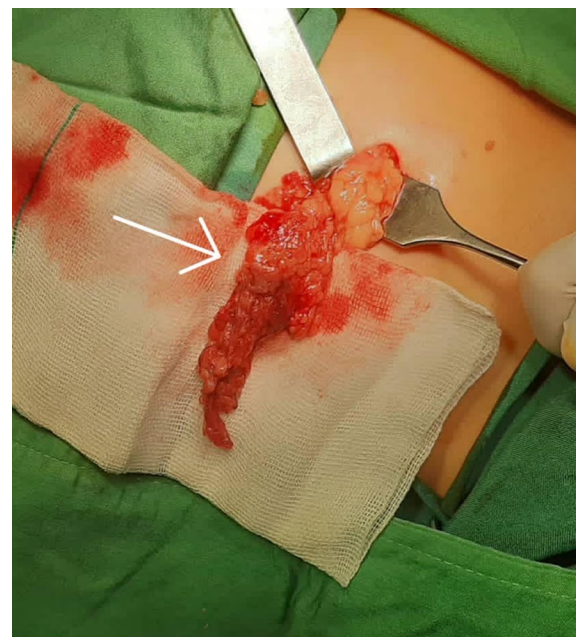


Fig. 2 Intraoperative findings of omental torsion, before resection. The sudden color change is evident in the image (arrow)

cefixime, and analgesic was prescribed. He had no complications on follow-up office visits after surgery for 6 months.

Discussion and conclusions

The omentum is a four-layer sheet of the peritoneum that descends from the stomach and binds to the transverse colon. It is capable of sequestering inflamed organs owing to its mobility [2] 4.

Omental torsion can be primary or secondary. Primary omental torsion is more prevalent in obese children and may occur in the absence of intraabdominal pathology. In contrast, secondary omental torsion, which is uncommon in children, is due to hernias, cyst or omental tumor, foreign body, adhesions, and postsurgical scarring. Risk factors for torsion include trauma, increased intraabdominal variations, pressure of fat deposits (particularly in obese patients), hyperperistalsis, omental anatomic variations, overeating, overexertion, and sudden changes in body position.

Increased omental weight due to fat deposits leads to decreased blood supply to the omentum in obese children and causes traction or torsion to the distal part. It occurs in 0.1–0.5% of children with presumptive appendicitis undergoing operations. Omental torsion occurs in adults more than children and is more common in males between 40 and 50 years (66%). With similar body weight, omental fat accumulation is higher in males compared

with females of similar body weight, which may explain the higher prevalence in males [2] 5 6.

Pain is the main clinical presentation of omental torsion, and it can be located in the right upper or lower quadrants, depending on the omentum affected site. The pain is nonradiating and constant, with sudden onset [7, 8]. Most patients with omental torsion present only one episode of pain, and recurrent abdominal pain may suggest intermittent torsions [7]. Body movements may induce pain and can be associated with rebound and localized tenderness [6]. Patients can also present gastrointestinal symptoms, such as anorexia, nausea, and vomiting. Fifty percent of patients present leukocytosis and low-grade fever. A mass under examination may be palpable if a large omental segment is involved. The palpable mass can be found in 50% of patients [4, 9].

Clinical presentation simulates other acute abdominal conditions. Differential diagnoses include cholecystitis, acute appendicitis, cecal diverticulitis, abdominal wall hematoma, perforated duodenal ulcer, and intestinal obstruction. In women of reproductive age, ectopic pregnancy, ovarian cyst torsion, and salpingitis should also be included. In children, mesenteric adenitis and Meckel diverticulum should also be considered. Another diagnostic possibility is torsion of an accessory spleen when it presents, which is usually located inside the omentum [10]. The duration of omental torsion is longer than acute appendicitis, and patients are less systematically unwell [9].

In our experience, radiological studies, have usually been nonspecific. However, recent studies have outlined specific findings on ultrasonography, computed tomography (CT), and magnetic resonance imaging (MRI) [6]. The characteristic ultrasound finding in omental torsion is a noncompressible, hyperechoic oval mass adherent to the abdominal wall with a hypoechoic rim [3, 11]. CT scan is crucial in diagnosing omental torsion because it can differentiate omental torsion from appendicitis and acute cholecystitis by showing a normal, noninflamed appendix and gallbladder, respectively. Also, a paracolic abscess and bowel wall thickening on CT scan may suggest diverticulitis [12]. CT scan findings in omental torsion include a large cake-shaped or ovoid dense fatty mass with hyperattenuating streaks associated with the thick anterior abdominal wall. There is often a typical whirling pattern of the mesentery, with serosanguinous fluid accumulation within the peritoneum. However, these findings can also appear in other conditions, such as liposarcoma, lipoma, angiomyolipoma, mesenteric lipodystrophy, teratoma, pseudomyxoma peritonei, intestinal volvulus, and segmental infarction of the omentum [11] 13. In our case, clinical signs and examinations were conclusive of acute

appendicitis, so there was no need for a CT scan. CT scan advantages outweigh ultrasonography on omental torsion evaluation when the mass can be identified in a specific location; in addition, ultrasonography is operator-dependent. Combining physical examination and real-time imaging may help focus on the maximal tenderness point by sonographic examination and less exposure to radiation [11]. MRI is also helpful, even with complications, such as abscess development or bleeding. However, the need for MRI is uncommon [7].

The treatment of omental torsion is controversial. Most patients recover with conservative treatment since imaging techniques can diagnose it early and lead to self-limiting and benign disease. Moreover, the total resolve of the inflammation, fibrosis, and retraction often occurs within 2 weeks [14] 15. However, some patients may require surgery because of an omental abscess, uncertain diagnosis, worsening of symptoms despite conservative treatment such as anti-inflammatory drugs, antibiotic therapy, and oral analgesics [14] 16. Surgical treatment includes laparoscopic resection of the affected segment of the omentum [17].

Furthermore, laparoscopic advantages are (1) facilitation of peritoneal aspiration and washing, (2) complete examination of the abdomen to confirm the diagnosis, and (3) reduction of the postoperative adhesion, wound-related complications, and postoperative pain [14].

In conclusion, omental torsion is a rare cause of acute abdomen. This case was treated successfully with omental resection. Most patients recover conservatively; however, because of the limitations in definitive diagnosis and prolonged hospital admission in conservative management, we suggest that surgical resection should be performed as soon as possible when the diagnosis is suspected.

Abbreviations

CT: Computed tomography; MRI: Magnetic resonance imaging; NPO: Nil per os.

Acknowledgements

We wish to thank our counselors in the Clinical Research Development Center of Children's Hospital in Bandar Abbas.

Author contributions

EK participated in the conception and design of the report. EK, ZG, and SM wrote the manuscript. MS evaluated the patient and performed the surgical management. MM interpreted radiological findings. SM substantively revised the manuscript. All authors read and approved the final manuscript.

Funding

The study did not receive any funding.

Availability of data and materials

The datasets used during the current study are available from the corresponding author on reasonable request.

Declarations

Ethics approval and consent to participate

The study is approved by Hormozgan University of Medical Sciences Ethical Committee under the ethical code IR.HUMS.REC.1400.061, and the study conforms with the statements of the Declaration of Helsinki.

Consent for publication

Written informed consent was obtained from the patient's legal guardian for publication of this case report and any accompanying images. A copy of the written consent is available for review by the Editor-in-Chief of this journal.

Competing interests

The authors declare no conflict of interest.

Author details

¹Student Research Committee, Faculty of Medicine, Hormozgan University of Medical Sciences, Bandar Abbas, Iran. ²Universal Scientific Education and Research Network (USERN), Bandar Abbas, Hormozgan, Iran. ³Department of Radiology, Shahid Mohammadi Hospital, Hormozgan University of Medical Sciences, Bandar Abbas, Iran. ⁴Department of Surgery, Shahid Mohammadi Hospital, Hormozgan University of Medical Sciences, Bandar Abbas, Iran. ⁵Pediatric Surgery, Hormozgan University of Medical Science, Bandar Abbas, Iran.

Received: 27 December 2021 Accepted: 30 June 2022

Published online: 24 July 2022

References

- Steinauer-Gebauer AM, Yee J, Lütolf ME. Torsion of the greater omentum with infarction: the vascular pedicle sign. *Clin Radiol*. 2001;56(12):999–1002.
- Madha ES, Kane TD, Manole MD. Primary omental torsion in a pediatric patient: case report and review of the literature. *Pediatr Emerg Care*. 2018;34(2):e32–4.
- Alexiou K, Ioannidis A, Drikos I, Sikalias N, Economou N. Torsion of the greater omentum: two case reports. *J Med Case Rep*. 2015;9:160.
- Joshi S, Cuthbert GA, Kerwat R. Omental torsion, a rare cause of acute abdomen. *BMJ Case Rep*. 2016.
- Mavridis G, Livaditi E, Baltogiannis N, Vasiliadou E, Christopoulos-Geroulanos G. Primary omental torsion in children: ten-year experience. *Pediatr Surg Int*. 2007;23(9):879–82.
- Panagidis A, El Salam S, Al Marzaoui A, Hobeldin M, Mahomed A. The emerging role of laparoscopy in diagnosis and treatment of primary omental torsion in children. *J Laparoendosc Adv Surg Tech A*. 2008;18(2):324–6.
- Cremonini C, Bertolucci A, Tartaglia D, Menonna F, Galatioto C, Chiarugi M. Acute abdomen caused by greater omentum torsion: a case report and review of the literature. *Ulus travma ve acil cerrahi Derg [Turk J Trauma Emerg Surg]*. 2016;22(4):391–4.
- López-Colombo A, Montiel-Jarquín A, García-Carrasco M, Nava A, Arcega-Domínguez A, Martínez-Fernández R, et al. Torsion of the omentum. A rare cause of acute abdomen. *Rev Med Inst Mex Seguro Soc*. 2010;48(5):549–52.
- Breunung N, Strauss P. A diagnostic challenge: primary omental torsion and literature review—a case report. *World J Emerg Surg*. 2009;4(1):40. <https://doi.org/10.1186/1749-7922-4-40>.
- Tsironis A, Zikos N, Bali C, Pappas-Gogos G, Koulas S, Katsamakis N. Acute abdomen due to primary omental torsion: case report. *J Emerg Med*. 2013;44(1):e45–8.
- Bachar GN, Shafir G, Postnikov V, Belenky A, Benjaminov O. Sonographic diagnosis of right segmental omental infarction. *J Clin Ultrasound*. 2005;33(2):76–9.
- Efthimiou M, Kouritas VK, Fafoulakis F, Fotakakis K, Chatzitheofilou K. Primary omental torsion: report of two cases. *Surg Today*. 2009;39(1):64–7.
- Naffaa LN, Shabb NS, Haddad MC. CT findings of omental torsion and infarction: case report and review of the literature. *Clin Imaging*. 2003;27(2):116–8.
- Kataoka J, Nitta T, Ota M, Takashima Y, Yokota Y, Fujii K, et al. Laparoscopic omentectomy in primary torsion of the greater omentum: report of a case. *Surg Case Rep*. 2019;5(1):2–7.
- Karanikas M, Kofina K, Boz Ali F, Vamvakerou V, Effraemidou E, Lyratzopoulos N, et al. Primary greater omental torsion as a cause of acute abdomen—a rare case report. *J Surg Case Rep*. 2018;2018:207.
- Gupta R, Farhat W, Ammar H, Azzaza M, Lagha S, Cheikh YB, et al. Idiopathic segmental infarction of the omentum mimicking acute appendicitis: a case report. *Int J Surg Case Rep*. 2019;60:66–8.
- Eaupanitcharoen S, Wattanasoontornsakul W. Left sided omental torsion with inguinal hernia: case report. *Int J Surg Case Rep*. 2020;76:328–30.

Publisher's Note

Springer Nature remains neutral with regard to jurisdictional claims in published maps and institutional affiliations.

Ready to submit your research? Choose BMC and benefit from:

- fast, convenient online submission
- thorough peer review by experienced researchers in your field
- rapid publication on acceptance
- support for research data, including large and complex data types
- gold Open Access which fosters wider collaboration and increased citations
- maximum visibility for your research: over 100M website views per year

At BMC, research is always in progress.

Learn more biomedcentral.com/submissions

