

Expression of Keratinocyte Growth Factor and Its Receptor in Rat Tracheal Cartilage: Possible Involvement in Wound Healing of the Damaged Cartilage

Takafumi Abo^{1,2}, Takeshi Nagayasu¹, Yoshitaka Hishikawa², Tsutomu Tagawa¹,
Atsushi Nanashima¹, Takatomo Yamayoshi¹, Keitaro Matsumoto¹,
Shucaï An² and Takehiko Koji²

¹Division of Surgical Oncology, Department of Translational Medical Sciences, Nagasaki University Graduate School of Biomedical Sciences and ²Department of Histology and Cell Biology, Nagasaki University Graduate School of Biomedical Sciences, Nagasaki 852–8523, Japan

Received January 18, 2010; accepted February 12, 2010; published online April 26, 2010

Keratinocyte growth factor (KGF) is involved in the development and regeneration of a variety of tissues. To clarify the role of KGF in cartilage wound healing, we examined the expression of KGF and its receptor (KGFR) immunohistochemically in the wound healing area of rat tracheal cartilage, and the direct effect of recombinant KGF on the proliferation and differentiation of primary cultures of rat chondrocytes. KGF was found in the cytoplasm of both chondrocytes and perichondrial cells. On the other hand, KGFR was detected only in the plasma membrane of chondrocytes. Although the expression of KGF was similar in the cartilage and perichondrial area before and after injury, KGFR expression was induced after injury and limited to proliferating chondrocytes. The staining pattern of KGF and KGFR was same in the mature and the immature rat tracheal cartilage. Moreover, *in vitro* experiments using primary cultured chondrocytes revealed that KGF at 200 ng/ml significantly increased the number of chondrocytes (~1.5-fold), and significantly reduced acid mucopolysaccharide production. These results indicate that KGF stimulates chondrocyte proliferation, suggesting that KGF could therapeutically modulate the wound healing process in the tracheal cartilage.

Key words: keratinocyte growth factor, tracheal cartilage, wound repair

I. Introduction

Regenerative medicine, particularly focusing on rapid reconstruction of damaged organs after surgery, has been notable in recent years, and various clinical attempts have already been made to apply this field to several organs, such as the skin, nervous system, and bones [2, 35]. However, approaches to the respiratory organs remain immature in this medical area. Among the tissue components of the respiratory system, the tracheal cartilage is important because it forms the duct structure of the trachea. The major problem

with research on cartilage is its very slow rate of proliferation. With respect to cartilage regeneration, various growth factors, such as fibroblast growth factor (FGF), transforming growth factor (TGF) β , insulin-like growth factor (IGF), and bone morphogenetic protein (BMP), have been reported to affect the state of proliferation and differentiation of chondrocytes [6, 10, 11, 21, 24, 31–33].

The keratinocyte growth factor (KGF) was originally discovered by Rubin *et al.* [25], and is a unique member of the FGF family (FGF-7) and a mesenchymal cell-derived paracrine mediator of epithelial cell growth. The high affinity KGF receptor (KGFR) was subsequently cloned by Miki *et al.* [20] and reported to be an alternatively spliced IIIb variant of the FGF receptor-2/bek gene (FGFR2) [5]. FGFR2-IIIb/KGFR is expressed in various epithelia and plays important roles in epithelial homeostasis and regener-

Correspondence to: Takehiko Koji, Ph.D., Department of Histology and Cell Biology, Nagasaki University Graduate School of Biomedical Sciences, 1–12–4 Sakamoto, Nagasaki 852–8523, Japan.
E-mail: tkoji@nagasaki-u.ac.jp

ation. On the other hand, FGFR2 also contains a spliced IIIc variant (FGFR2-IIIc), and FGFR2-IIIc has various effects on the osteoblast and chondrocytes [7]. KGF is currently known to be expressed in a variety of tissues, including the lungs [9, 23, 37], prostate, [13] mammary glands [12, 29], digestive tract [22], skin [26], and uterus [14], and is implicated in organ development, mass homeostasis, and carcinogenesis.

We have already reported the immunohistochemical expression of KGF on alveolar epithelium cells in rat lung resection model [18]. In that study we noted the strong expression of KGF in tracheal cartilages, suggesting its possible roles in the regulation of mass homeostasis of the tracheal cartilage, including wound healing. In fact, reports on the role of KGF and other growth factors in the tracheal cartilage have been very limited [3, 4]. Finch *et al.* [8] using *in situ* hybridization in mouse embryos reported that the cartilage of the limbs, larynx, and trachea exhibit hybridization signals for KGF and KGFR in the perichondrium and cartilage itself. Recently, Lazarus *et al.* [17] reported the expression of KGF and its receptor by real-time RT-PCR in the rat tibial perichondrium and growth plate, and suggested that perichondrial KGF regulates growth plate chondrogenesis. These studies strongly demonstrated the possible role of KGF in the promotion of cartilage regeneration.

The present study was designed to determine the role of KGF in the regulation of tracheal cartilage regeneration after injury. For this purpose, we examined immunohistochemically the expression of KGF and KGFR in relation to proliferative activity in a rat model of regenerating tracheal cartilage. We also examined the effect of human recombinant KGF on the proliferation and differentiation activity of primary cultured chondrocytes derived from the rat nasal septum.

II. Materials and Methods

Animals

Experiments were conducted on inbred, unmodified, pathogen-free male Lewis (LEW, RT1^l) rats. At the start of the study, the immature rats ($n=28$) were 3 weeks old, weighing 80 g, and the mature rats ($n=28$) were 8 weeks old, weighing 290 g (Charles River Japan Inc., Yokohama, Japan, and SLC Japan Co., Shizuoka, Japan). They were housed in the Laboratory Animal Resource Center at Nagasaki University Graduate School of Biomedical Sciences (NUGSBS) in accordance with the guidelines of the National Institutes of Health and our institution. The study design was approved by the Ethics Committee of the NUGSBS (No. 0212040233).

Antibodies

Polyclonal antibodies against KGF and KGFR were prepared by immunization of rabbits against synthetic peptides in cooperation with Nichirei Co. (Tokyo, Japan) as described previously [36]. For immunohistochemical analysis,

anti-KGF antibody (IgG, 10 $\mu\text{g}/\text{ml}$ for tissue sections, 5 $\mu\text{g}/\text{ml}$ for cultured cells) and anti-KGFR antisera (1:400 for tissue sections, 1:200 for cultured cells) were used to identify KGF and KGFR expression, respectively. The mouse anti-proliferating cell nuclear antigen (PCNA) monoclonal antibody (PC10, IgG, 1.4 $\mu\text{g}/\text{ml}$ for tissue sections) was purchased from DAKO (Glostrup, Denmark). Horseradish peroxidase (HRP)-conjugated goat anti-mouse IgG F (ab)' (1:200) was purchased from Chemicon International (Temecula, CA, USA). Normal goat IgG, normal rabbit IgG, and normal mouse IgG were purchased from Sigma Chemical Co. (St Louis, MO, USA). Normal goat serum and normal rabbit serum were purchased from DAKO.

Tracheal operation

The rat was anesthetized with an intraperitoneal injection of 25 mg/kg sodium pentobarbital (Dainippon Seiyaku Co., Tokyo). After sterilization and draping, a midline collar incision was made, followed by dissection of the muscular plane down to the trachea. A longitudinal tracheal incision over two rings in length at 3 or 4 rings below the vocal chords was made (Fig. 1). Three interrupted 8-0 PDS (polydioxanone; Ethicon Inc., Somerville, NJ, USA) sutures were placed between the tracheal rings to close the incision. During this operation, intubation was not needed. All rats survived without any major complications. No air leakage was observed from day 1 after the operation. The rats were then sacrificed with an overdose of pentobarbital (150 mg/kg) at day 0 (as control), 1, 3, 5, 7, 14 and 28 after operation. The tracheas were excised from the larynx to the carina, and trimmed into 5 cartilage rings including the incised wound. The specimens were then placed overnight in 4% paraformaldehyde in phosphate-buffered saline (PBS: pH 7.4), embedded in paraffin, and 4- μm thick serial cross-sections were cut and placed on silane-coated glass slides. To con-

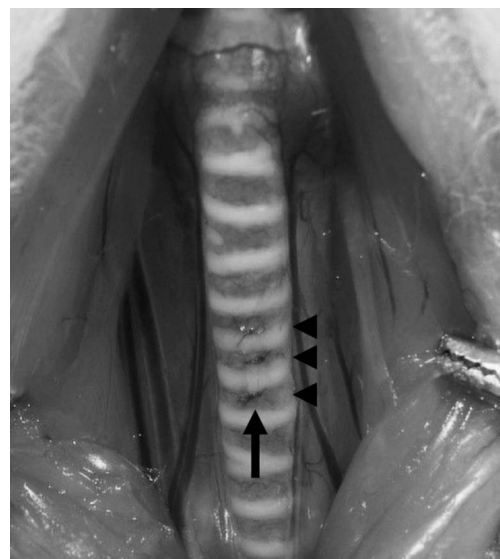


Fig. 1. Photograph of the operative field. Arrow: longitudinal tracheal incision. Arrowhead: three interrupted sutures closing incision.

firm the expression of KGF and KGFR in other rat cartilage tissues, we used the nasal septum and auricular cartilage of mature (8-week-old) rats. Several sections from the specimens were stained with hematoxylin and eosin (H&E) to examine the structure of the wound healing area and any difference in the healing process between the immature and mature groups. The other sections were used for immunohistochemical analysis of KGF, KGFR, and PCNA expression in the wound healing area.

Primary culture of rat nasal septum chondrocytes

Primary cultures of rat nasal septum chondrocytes were purchased from Hokudo Co. (Sapporo, Japan). The nasal septum cartilage has a blood-rich stroma and intraluminal epithelium, similar to that of the tracheal cartilage, and chondrocytes from the nasal septum cartilage have often been used as the cell source for artificial trachea [15]. The cells were incubated in collagen-coated 35-mm dishes (Becton Dickinson Labware, Franklin Lakes, NJ, USA) for 2 days in RPMI 1640 medium, supplemented with 100 U/ml penicillin potassium, 100 µg/ml streptomycin sulfate, 10% dextran-coated charcoal-treated fetal bovine serum, and 10 mM ascorbic acid at 37°C in a humidified atmosphere of 5% CO₂. To analyze KGF and KGFR expression, the cells were further incubated in collagen-coated chamber slides (Lab-Tek, Nalge Nunc International, Naperville, IL, USA) for 2 more days. After fixation with 4% paraformaldehyde in PBS for 10 min at room temperature, the slides were subjected to immunohistochemistry.

To analyze the effect of KGF, a fixed number of cells (1×10^4 cells per well) were incubated for 6 days in the medium described above with recombinant human KGF (0, 0.1, 10, 100, 200 and 500 ng/ml) (PeproTech, Rocky Hill, NJ, USA) in a collagen-coated 24-well plate (Becton Dickinson Labware), and medium change was performed every other day.

Cell count and measurement of acid mucopolysaccharide amounts in primary cultures of rat chondrocytes

At various time points after the addition of KGF, the cells and media were collected and solubilized in the cell-lysis solution (Hokudo Co.) with ultrasonication using Bronson Ultrasonicator 230 (Bronson Sonicator Co., Danbury, CT, USA) for 15 secs. For DNA assay, aliquots of triplicate samples were processed using a DNA quantification kit (Hokudo Co.). The fluorescence of the processed samples was measured with a fluorometer (RF5000; Shimadzu, Kyoto, Japan), and the DNA amount was calculated according to the instructions provided by the supplier. The cell number per dish was estimated from measured DNA amount of chondrocytes. For the acid mucopolysaccharide assay, the samples were analyzed using mucopolysaccharide quantification kit (Hokudo Co.) and absorbance at 650 nm was measured with a spectrophotometer (UV1600; Shimadzu, Kyoto, Japan). The obtained readings were compared with a standard curve generated to determine acid mucopolysaccharide concentrations.

Western blot analysis of KGF

Tissues of the rat trachea, nasal septum and cultured rat chondrocytes were homogenized with a Polytron homogenizer (Glen Mills Inc., Clifton, NJ, USA) in a lysis buffer containing 20 mM Tris-HCl (pH 7.5), 150 mM NaCl, 5 mM ethylenediaminetetraacetic acid, 0.5% Triton X-100, and 10% glycerol supplemented with protease inhibitors [10 µg/ml aprotinin, 10 µg/ml leupeptin, and 1 mM phenylmethylsulphonyl fluoride] on ice. The lysate was then centrifuged at 15,000 rpm for 20 min at 4°C and the supernatants were collected and stored at -80°C. The protein concentration in each preparation was determined using a protein assay kit from Bio-Rad Laboratories (Richmond, CA), using bovine serum albumin (BSA) as a standard. In the next step, 10 or 20 µg of the sample lysates were separated by sodium dodecyl sulfate-polyacrylamide gel electrophoresis (SDS-PAGE) with a 4–25% gradient gel (Daiichi Pure Chemical, Tokyo, Japan) according to the method of Laemmli [16] and electrophoretically transferred to a polyvinylidene difluoride membrane (Immobilon, Millipore Corp., Bedford, MA). A molecular marker was used to assess the molecular weight corresponding to the detected bands. The membranes were incubated overnight with the first antibody at room temperature, and then reacted with HRP-conjugated goat anti-rabbit IgG for 2 hr at room temperature. Finally, the signals were visualized by ECL plus reagent (Amersham Biosciences Inc., Piscataway, NJ, USA).

Immunohistochemistry

The immunohistochemical procedure used in the present study was described previously [1, 19, 27]. For KGF detection, the slides were pretreated with 0.3% H₂O₂ in methanol for 10 min at room temperature. After blocking the non-specific reaction with antibodies by incubation with 10% normal goat serum and 1% BSA in PBS, the sections were incubated with the first antibody for 2 hr. Next, the sections were incubated with HRP-conjugated goat anti-rabbit IgG for 1 hr. The signals were visualized with 3,3'-diaminobenzidine tetrahydrochloride and H₂O₂ for 10 min. For KGFR detection, a procedure similar to that used for KGF was applied except that the slides were pretreated with 0.2% Triton X-100 in PBS for 10 min at room temperature, and incubated with HRP-conjugated goat anti-rabbit IgG for second antibody. For immunohistochemistry of PCNA, the slides were autoclaved at 120°C for 10 min in 10 mM citrate buffer (pH 6.0) and then successively reacted with a monoclonal mouse anti-PCNA antibody (PC10) for 2 hr and HRP-conjugated goat anti-mouse IgG for 1 hr. Finally the sections were counterstained with methyl green. As a negative control, normal rabbit IgG (for anti-KGF), normal rabbit serum (for anti-KGFR) and normal mouse IgG (for anti-PCNA) were used.

For evaluation of immunohistochemical results, the relative intensities of immunostaining for KGF and KGFR were evaluated as negative (-), weakly positive (+), moderate (++) and intense (+++), relative to background staining in negative control sections. To quantify the proliferative

activity of the cartilage area and perichondrium area around the wound healing area, more than 2,000 chondrocytes were counted and the number of PCNA-positive cells was expressed as the percentage of positive cells per total number of counted cells (PCNA labeling index).

Statistical analysis

All data were expressed as mean±SD. Data of different groups were compared using one-way analysis of variance (ANOVA). Chi-square test was used for comparison of categorical variables. Differences between two groups were analyzed by Fisher's exact test or Scheffé's multiple comparison tests. A P value <0.05 was considered significant. StatView Software for Windows, version 5.0 (SAS Institute, Inc., Cary, NC, USA) was used for all statistical analyses.

III. Results

KGF expression in normal rat tracheal cartilage and primary cultured rat chondrocytes by western blot analysis

To confirm the expression of KGF in chondrocytes, we examined tracheal cartilage extracts from normal 8-week-old male Lewis rats and primary cultured rat nasal septum chondrocytes by western blotting. A band corresponding to 28 kD, the expected molecular weight for KGF, was detected with anti-KGF in each case (Fig. 2). These results indicated the expression of KGF in the rat tracheal cartilage, nasal septum cartilage, and primary cultured rat nasal septum chondrocytes.

Immunohistochemical detection of KGF and KGFR in normal rat tracheal and nasal septum cartilage

In the normal mature rat tracheal (Fig. 3A) and nasal septum (data not shown) cartilage, strong staining for KGF was found in the cytoplasm of both chondrocytes and perichondrial cells. KGF was also detected in the blood vessels, stroma and epithelium of the trachea, and the positive cells

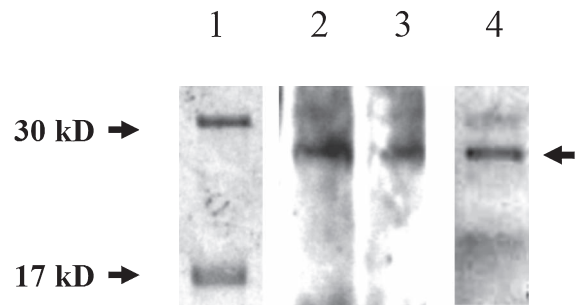


Fig. 2. Western blot analysis of KGF in adult rat cartilage. Molecular marker (lane 1), lysate of rat tracheal cartilage (lane 2, 20 µg), lysate of rat nasal septum cartilage (lane 3, 20 µg) and lysate of cultured rat nasal septum chondrocytes (lane 4, 20 µg) were separated on a 15–25% gel. A major band corresponding to 28 kD (lanes 2–4) was detected with anti-KGF antibody (arrow).

were identified as endothelial cells, infiltrating lymphocytes, fibroblasts, and glandular epithelial cells in the tracheal wall. On the other hand, KGFR was detected only in the plasma membrane of chondrocytes in the tracheal (Fig. 3B) and nasal septum (data not shown) cartilage. The perichondrial cells were almost negative for KGFR. The same staining pattern was also observed for KGF and KGFR in the immature rat tracheal and nasal septum cartilage. No staining was observed when the adjacent sections were reacted with the appropriate control serum (data not shown).

Cell proliferation and expression of KGF and KGFR in tracheal cartilage after surgery

As shown in Figure 4, the cartilage defect created by surgery was temporarily closed by fibroblasts at an early stage after the injury (Fig. 4A and C), and then the participation of chondrocytes reforming the cartilage ring was eventually observed on day 28 after the operation (Fig. 4B and D) in both the immature and mature groups. With

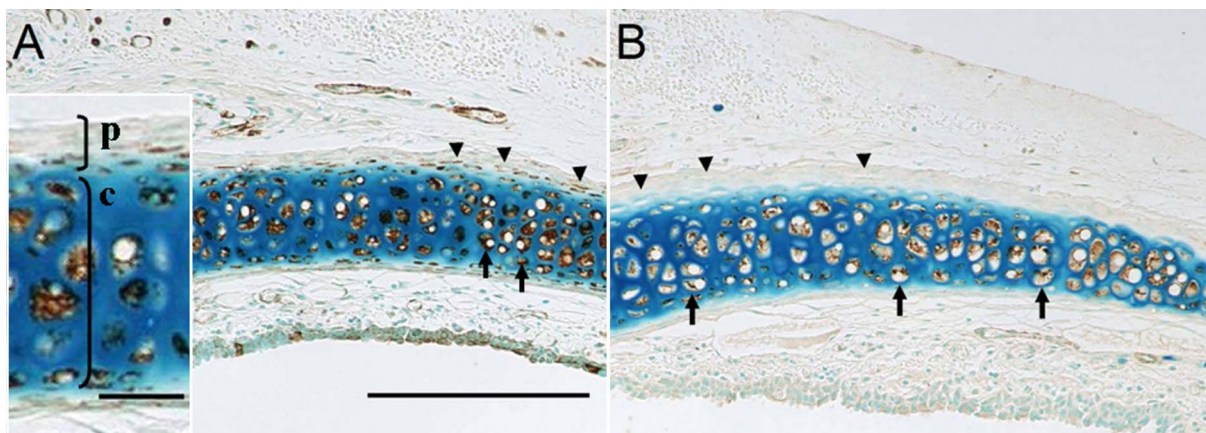


Fig. 3. Immunohistochemical localization of KGF and KGFR in serial paraffin sections from normal mature rat cartilage. (A) KGF immunoreactivity in rat tracheal cartilage. Arrow: KGF positive chondrocytes. Arrowhead: KGF positive perichondrial cells. (B) KGFR immunoreactivity in rat tracheal cartilage. Arrow: KGFR positive chondrocytes. Arrowhead: KGFR negative perichondrial cells. p: perichondrial area, c: chondrocyte area. Magnification×100. Bars=200 µm and 30 µm (inset in A).

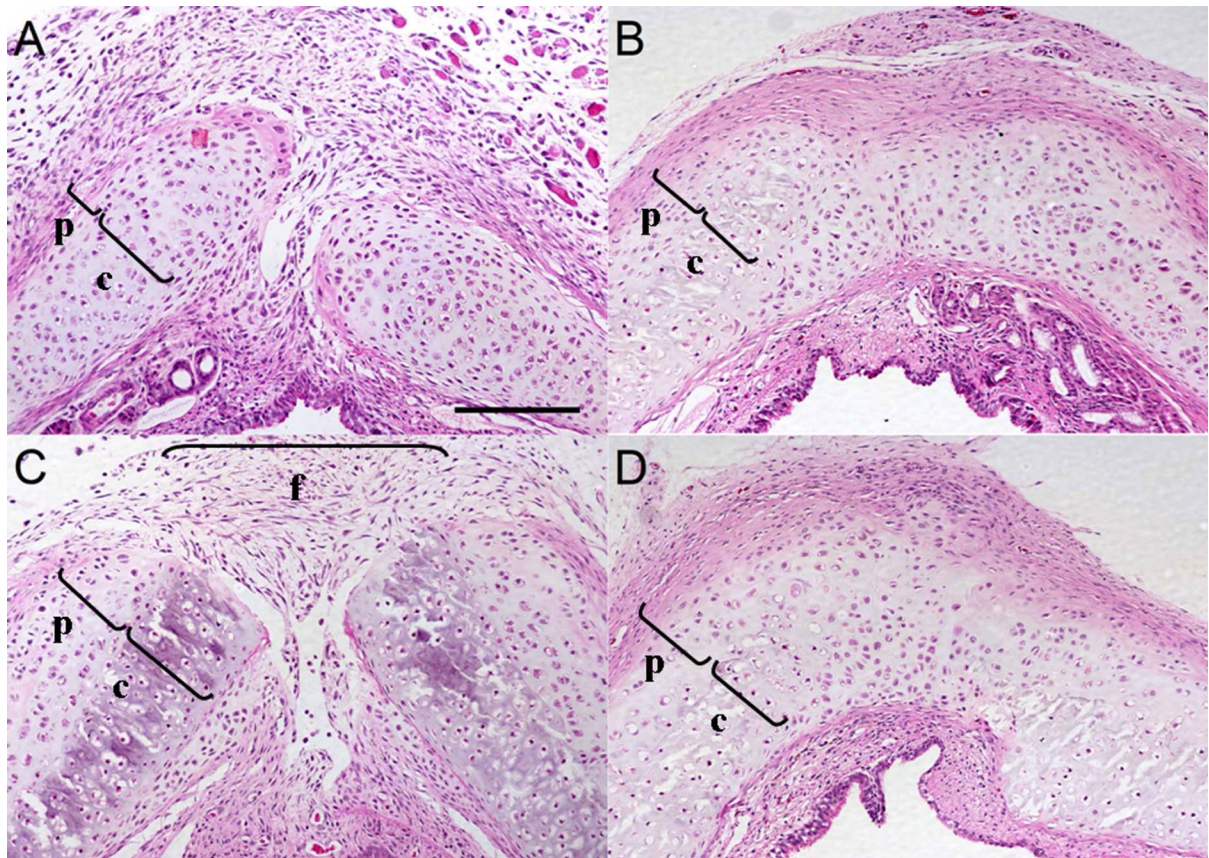


Fig. 4. Serial changes in the histology in paraffin sections of immature and mature post-operative rat trachea. (A) H&E staining on day 5 after operation in the immature rat group. (B) H&E staining on day 28 in the immature rat group. (C) H&E staining on day 5 in the mature rat group. (D) H&E staining on day 28 in the mature rat group. p: perichondrial area, c: chondrocyte area, f: proliferating fibroblast area. Magnification $\times 100$. Bar=200 μm .

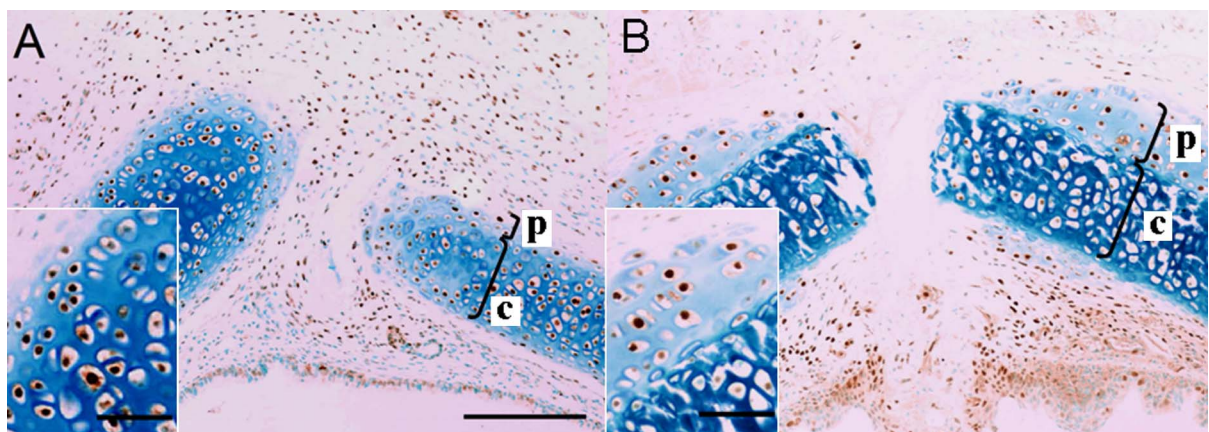


Fig. 5. Serial changes in the expression of PCNA in paraffin sections of immature and mature post-operative rat trachea. (A) Immunohistochemical detection of PCNA on day 5 in the immature rat group. (B) Immunohistochemical detection of PCNA on day 5 in the mature rat group. p: perichondrial area, c: chondrocyte area. Magnification $\times 100$. Bars=200 μm and 30 μm (inset in A, B).

regard to cell proliferation in the injured area, not only perichondrial cells but also the majority of chondrocytes of the immature group were positive for PCNA on day 5 after the operation (Fig. 5A), indicating multi-focal proliferation of

chondrocytes during the healing process. On the other hand, PCNA staining in the mature group was observed mainly in the perichondrium and only a few chondrocytes in the fully differentiated cartilage (Fig. 5B). To analyze the pro-

Table 1. Comparison of PCNA labeling index of chondrocytes in wound healing area on day 5 after operation between immature and mature group

Rat group	Area	PCNA labeling index n=2000
Immature	Cartilage area	0.82±0.09
	Perichondrium	0.84±0.08
Mature	Cartilage area	0.43±0.09*
	Perichondrium	0.83±0.05

Data are mean±SD. *: P<0.01, compared with the immature group.

liferating activities quantitatively, the PCNA labeling index of chondrocytes of perichondrial and cartilage parts in the wound healing area, including both right and left sides of the tracheostomy site, was measured. As shown in Table 1, the PCNA labeling index of chondrocytes in the cartilage part of the mature rats was significantly lower than that of the immature ones.

The staining intensity of KGF in the tracheal cartilage and perichondrial area was similarly before and after sur-

gery, in both immature and mature rat groups (Fig. 6A, B, C and D). However, staining for KGFR was markedly higher after surgery in the perichondrial area including the proliferating chondrocytes (Table 2).

Expression of KGF and KGFR in primary cultured chondrocytes

In primary cultures of rat nasal septum chondrocytes, a strong staining was detected for KGF in the cytoplasm (Fig. 7A). On the other hand, a variable degree of immunostaining for KGFR was noted; staining of plasma membrane was intense in the confluent area, but was weaker in the sparse area (Fig. 7B).

Effect of exogenous KGF on cell proliferation and production of acid mucopolysaccharides in primary cultured rat chondrocytes

To examine the effect of KGF on the proliferating activity of chondrocytes, primary cultures of rat chondrocytes from the nasal septum were incubated with increasing concentrations of recombinant human KGF for 6 days (Fig. 8 and Table 3). As shown in Figure 8A, the chondrocyte cell

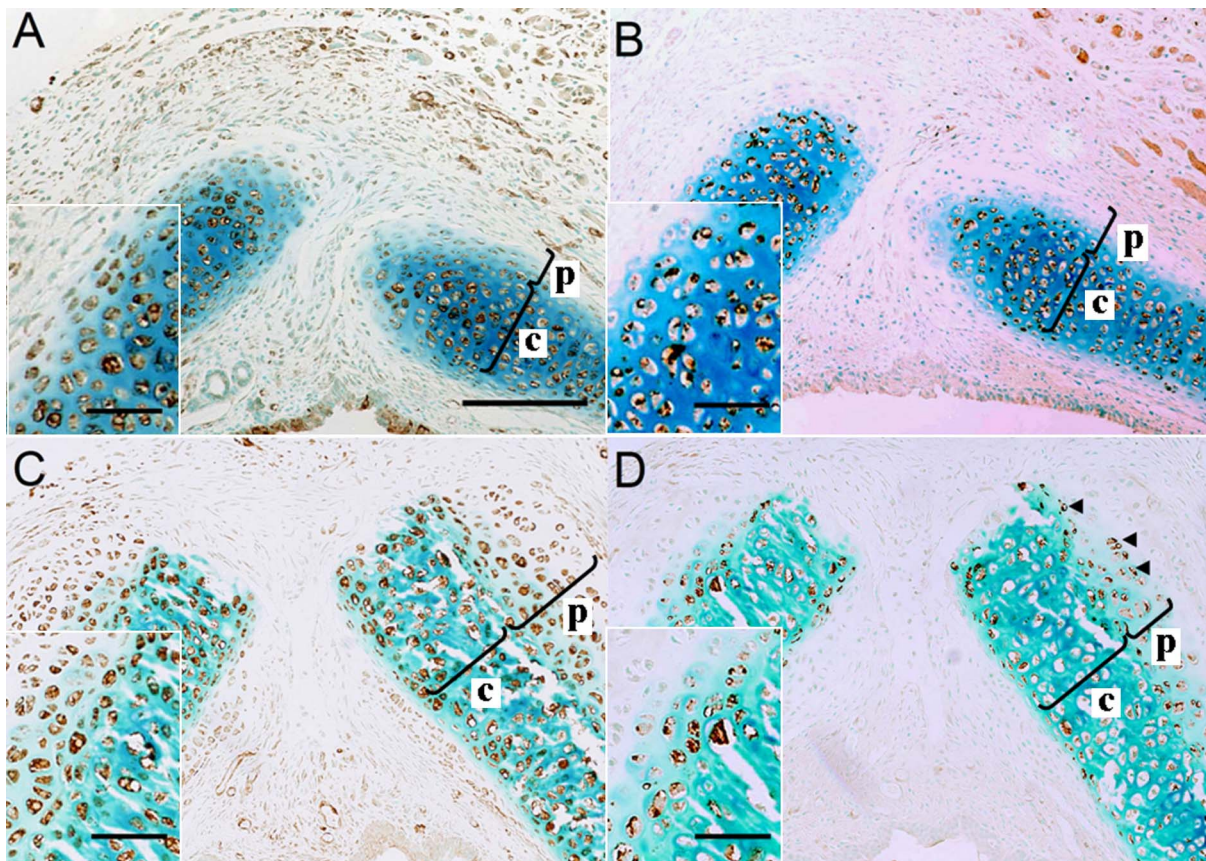


Fig. 6. Immunohistochemical detection of KGF and KGFR in paraffin sections of post-operative rat trachea. (A) Immunohistochemical detection of KGF on day 5 in the immature rat group. (B) Immunohistochemical detection of KGFR on day 5 in the immature rat group. (C) Immunohistochemical detection of KGF on day 5 in the mature rat group. (D) Immunohistochemical detection of KGFR on day 5 in the mature rat group. Arrowhead: positive staining of KGFR in proliferating chondrocytes from perichondrium. p: perichondrial area, c: chondrocyte area. Magnification×100. Bars=200 μm and 30 μm (inset in A, B, C, D).

Table 2. Comparison of KGF and KGFR staining in the wound healing area

Rat group	Area of cells	KGF (score of intensity)*			KGFR (score of intensity)		
		Control	Day 5	Day 28	Control	Day 5	Day 28
Immature	Cartilage	+++	+++	+++	+++	+++	+++
	Perichondrium	++	++	++	-	+	-
	Fibroblasts**	+	++	-	-	-	+
Mature	Cartilage	+++	+++	+++	+++	+++	+++
	Perichondrium	++	++	++	-	++	-
	Fibroblasts**	-	+	-	-	+	-

*- =negative; +=weakly positive; ++=moderate; +++=intense

** fibroblasts surrounding cartilage in the wound healing area

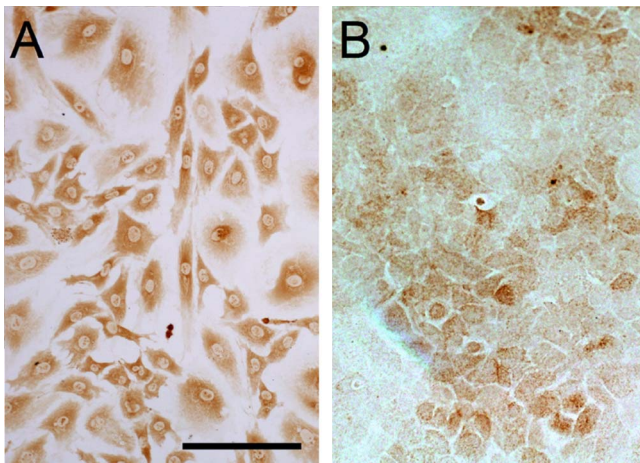


Fig. 7. Immunohistochemical detection of KGF and KGFR in primary cultures of rat nasal septum chondrocytes. (A) KGF immunoreactivity was detected in primary cultures of rat nasal septum chondrocytes. (B) KGFR immunoreactivity was detected in primary cultures of rat nasal septum chondrocytes. Magnification $\times 400$. Bar=50 μm .

number per dish increased significantly in a dose-dependent manner, reaching a plateau level (149% of the control) at a concentration of 200 ng/ml. The calculated doubling-time (1.6 ± 0.3 days), was significantly shorter than control cultures (2.9 ± 0.3 days).

Since the production of acid mucopolysaccharides is a functional marker of chondrocytes, we measured the amount of acid mucopolysaccharides in the primary cultures with various concentrations of recombinant KGF. As shown in Figure 8B, a significant dose-dependent decrease in the amount was noted. These results indicate that KGF promotes chondrocyte proliferation, but not their differentiation.

IV. Discussion

In the present study of a rat model of tracheal incision, we investigated the possible involvement of KGF and KGFR in the wound healing process of tracheal cartilage, since little is known about the growth factors involved in

regulation of cartilage wound healing *in vivo*. Our study clearly demonstrated the expression of KGF in chondrocytes and perichondrial cells of both immature and mature rat trachea while KGFR was detected in the chondrocyte plasma membrane only, but not in perichondrial cells. After surgery, however, KGFR expression was induced in perichondrial cells in parallel with the induction of their proliferation. Moreover, we also showed that KGF promoted the proliferation of primary cultured chondrocytes from rat nasal septum. These results indicate that the KGF-KGFR system plays an important role in the wound healing process of the tracheal cartilage in both immature and mature rats, especially inducing perichondrial cell proliferation.

Although the defect of tracheal cartilage rings was finally repaired by newly constructed cartilage tissue in both immature and mature rats, the cartilage regeneration process was preceded by proliferation and migration of fibroblasts to fill the defective parts. During the process of wound healing, the expression of KGF was increased not only in chondrocytes but also in fibroblasts. These results may indicate that the higher expression of KGF can induce the regeneration of cartilage through the proliferation of fibroblasts. Considering that the regenerative response of the connective tissue and cartilage in the repair process of joint cartilages occurred simultaneously, the delayed response of the tracheal cartilage to the injury may be tissue-specific. Another interesting aspect of tracheal cartilage regeneration is that the roles of chondrocytes in the cartilage matrix seemed to be different between immature and mature rats; immature rats showed induction of proliferation of chondrocytes as well as perichondrial cells, whereas no proliferation of chondrocytes in the mature cartilage matrix was observed, consistent with the findings of a previous study [6]. Therefore, in the clinical setting, careful attention must be paid to monitor wound healing of cartilage in mature or aged cases, especially when accompanied by perichondrial handling, because the perichondrium appears to be essential in the cartilage regeneration process in mature rats.

In the present study, KGFR was expressed in the perichondrium during wound healing but not under normal physiological condition. This finding strongly suggests the involvement of KGF in the proliferation of perichondrial cells. In addition, based on the post-surgical distribution of

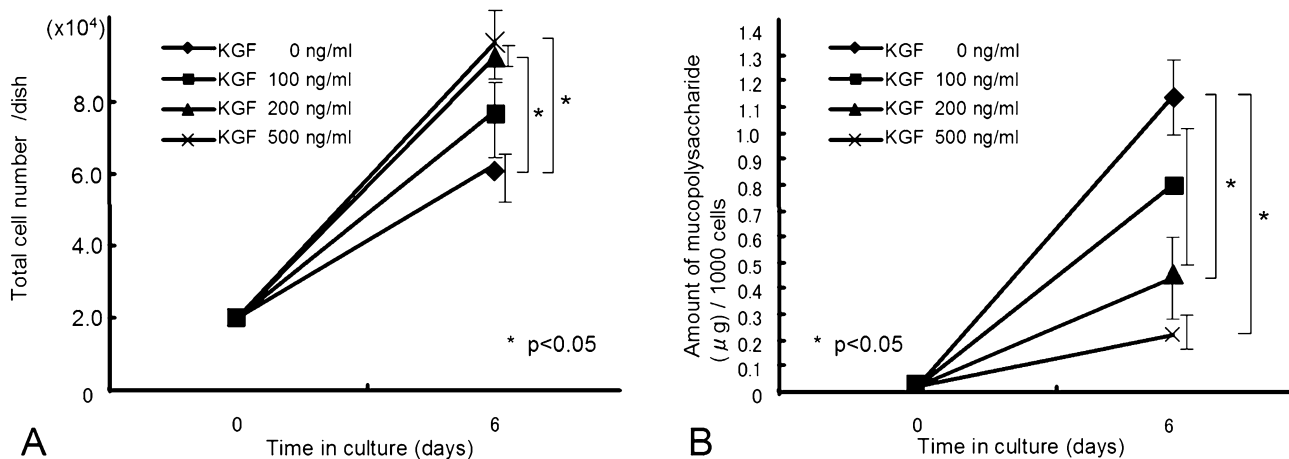


Fig. 8. Total cell counts and quantification of acid mucopolysaccharide product in primary cultured chondrocytes treated with various concentrations of KGF. **(A)** Total cell counts of primary cultured chondrocytes treated with various concentrations of KGF on day 6 during culture. Data are mean±SD of three independent experiments. * P<0.05 vs. control. **(B)** Quantification of acid mucopolysaccharide product in primary cultured chondrocytes treated with various concentrations of KGF on day 6 during culture. (Product amount per 1000 cells). Data are mean±SD of three independent experiments. * P<0.05 vs. control.

Table 3. Effect of KGF to cell proliferation and production of mucopolysaccharide of primary cultured chondrocytes after day 6 in culture

KGF concentration	Total cell number/dish	
	Mean±SD	Difference from control (p value)
Control	6.23×10 ⁴ ±3.94×10 ³	
100 ng/ml	7.74×10 ⁴ ±1.32×10 ⁴	0.231
200 ng/ml	9.34×10 ⁴ ±3.11×10 ³	0.0056*
500 ng/ml	9.63×10 ⁴ ±1.28×10 ⁴	0.0028*
KGF concentration	Total product of mucopolysaccharide/dish	
	Mean±SD (μg)	Difference from control (p value)
Control	70.6±10.7	
100 ng/ml	59.7±19.6	0.744
200 ng/ml	42.2±14.8	0.085
500 ng/ml	20.6±7.17	0.0025*
KGF concentration	Product of mucopolysaccharide/1000 cells	
	Mean±SD (μg)	Difference from control (p value)
Control	1.13±0.15	
100 ng/ml	0.78±0.42	0.148
200 ng/ml	0.45±0.18	0.0034*
500 ng/ml	0.21±0.09	0.0002*

* p<0.05, compared with the respective control group.

PCNA-positive cells, the perichondrium seems to be the primary source of proliferative chondrocytes in mature rats, and chondrocytes near the cutting edge can also proliferate in a multifocal manner in immature rats.

Since KGF promotes cell differentiation under certain conditions [28], it is conceivable that the expression of KGF in normal cartilage serves to maintain cartilage function in an autocrine/paracrine manner. However, when we examined the effect of extraneously added KGF on primary cultured chondrocytes derived from the nasal septum, KGF did not stimulate acid mucopolysaccharide production; rather, it decreased such production from chondrocytes. This apparent discrepancy may be explained by the general tendency of proliferating cells to lose their specific functions. Since other growth factors, such as TGFβ-1 and BMP2, are known to promote cartilage differentiation (i.e., production of extracellular matrix or acceleration of ossification) [30, 32], cooperation between KGF and such growth factors might be required to promote or maintain the differentiation state of chondrocytes. Further studies are required to explore this issue in the future. In this context, it should be noted that Weksler *et al.* described dedifferentiation of chondrocytes by FGF-9 [34]; the receptor for FGF-9 is FGFR3, which is similar receptor for KGFR, promoted proliferation, but inhibited terminal differentiation, similar to KGF.

Several recent studies have investigated the effect of IGF-1 alone or with other growth factors such as FGFs on the temporomandibular joint condylar cartilage, which exhibits hyaline-like features [33]. Finch *et al.* [8] reported that KGF and KGFR are expressed on the cartilage of limbs, ribs, larynx, and trachea from embryonic stage, it is possible that the use of KGF with these growth factors may have enhancing, competitive, or other specific effects on the hyaline cartilage.

In conclusion, the results of the present study showed that the KGF-KGFR system plays a role in promotion of the wound healing process in injured tracheal cartilage. These results suggest that KGF may be a potentially useful therapeutic tool after tracheoplasty and/or lung transplantation.

V. References

- Aoki, D., Yamamoto-Fukuda, T., Hishikawa, Y., Nakamura, M., Sakai, H., Kanetake, H. and Koji, T. (2004) Coexpression of keratinocyte growth factor and its receptor in normal and prostate cancer tissues: Possible formation of autonomous andromedin loop. *Acta Histochem. Cytochem.* 37; 379–389.
- Butler, D. L., Goldstein, S. A., Guldberg, R. E., Guo, X. E., Kamm, R., Laurencin, C. T., McIntire, L. V., Mow, V. C., Nerem, R. M., Sah, R. L., Soslowsky, L. J., Spilker, R. L. and Tranquillo, R. T. (2009) The impact of biomechanics in tissue engineering and regenerative medicine. *Tissue Eng. Part. B Rev.* 15; 477–484.
- Dodge-Khatami, A., Backer, C. L., Holinger, L. D., Mavroudis, C., Cook, K. E. and Crawford, S. E. (2001) Healing of a free tracheal autograft is enhanced by topical vascular endothelial growth factor in an experimental rabbit model. *J. Thorac. Cardiovasc. Surg.* 122; 554–561.
- Dodge-Khatami, A., Niessen, H. W., Baidoshvili, A., van Gulik, T. M., Klein, M. G., Eijnsman, L. and de Mol, B. A. (2003) Topical vascular endothelial growth factor in rabbit tracheal surgery: comparative effect on healing using various reconstruction materials and intraluminal stents. *Eur. J. Cardiothorac. Surg.* 23; 6–14.
- Drugan, C. S., Paterson, I. C. and Prime, S. S. (1998) Fibroblast growth factor receptor expression reflects cellular differentiation in human oral squamous carcinoma cell lines. *Carcinogenesis* 19; 1153–1156.
- Duynstee, M. L., Verwoerd-Verhoef, H. L., Verwoerd, C. D. and Van Osch, G. J. (2002) The dual role of perichondrium in cartilage wound healing. *Plast. Reconstr. Surg.* 110; 1073–1079.
- Eswarakumar, V. P., Horowitz, M. C., Locklin, R., Morriss-Kay, G. M. and Lonai, P. (2004) A gain-of-function mutation of Fgfr2c demonstrates the roles of this receptor variant in osteogenesis. *Proc. Natl. Acad. Sci. USA* 101; 12555–12560.
- Finch, P. W., Cunha, G. R., Rubin, J. S., Wong, J. and Ron, D. (1995) Pattern of keratinocyte growth factor and keratinocyte growth factor receptor expression during mouse fetal development suggests a role in mediating morphogenetic mesenchymal-epithelial interactions. *Dev. Dyn.* 203; 223–240.
- Galiacy, S., Planus, E., Lepetit, H., Féréol, S., Laurent, V., Ware, L., Isabey, D., Matthay, M., Harf, A. and d'Ortho, M. P. (2003) Keratinocyte growth factor promotes cell motility during alveolar epithelial repair in vitro. *Exp. Cell Res.* 283; 215–229.
- Grumbles, R. M., Howell, D. S., Wenger, L., Altman, R. D., Howard, G. A. and Roos, B. A. (1996) Hepatocyte growth factor and its actions in growth plate chondrocytes. *Bone* 19; 255–261.
- Guerne, P. A., Blanco, F., Kaelin, A., Desgeorges, A. and Lotz, M. (1995) Growth factor responsiveness of human articular chondrocytes in aging and development. *Arthritis Rheum.* 38; 960–968.
- Hishikawa, Y., Tamaru, N., Ejima, K., Hayashi, T. and Koji, T. (2004) Expression of keratinocyte growth factor and its receptor in human breast cancer: its inhibitory role in the induction of apoptosis possibly through the overexpression of Bcl-2. *Arch. Histol. Cytol.* 67; 455–464.
- Huang, Y. W., Wang, L. S., Chang, H. L., Ye, W., Shu, S., Sugimoto, Y. and Lin, Y. C. (2006) Effect of keratinocyte growth factor on cell viability in primary cultured human prostate cancer stromal cells. *J. Steroid Biochem. Mol. Biol.* 100; 24–33.
- Koji, T., Chedid, M., Rubin, J. S., Slayden, O. D., Csaky, K. G., Aaronson, S. A. and Brenner, R. M. (1994) Progesterone-dependent expression of keratinocyte growth factor mRNA in stromal cells of the primate endometrium: keratinocyte growth factor as a progesteromedin. *J. Cell Biol.* 125; 393–401.
- Kojima, K., Bonassar, L. J., Roy, A. K., Vacanti, C. A. and Cortiella, J. (2002) Autologous tissue-engineered trachea with sheep nasal chondrocytes. *J. Thorac. Cardiovasc. Surg.* 123; 1177–1184.
- Laemmli, U. K. (1970) Cleavage of structural proteins during the assembly of the head of bacteriophage T4. *Nature* 227; 680–685.
- Lazarus, J. E., Hegde, A., Andrade, A. C., Nilsson, O. and Baron, J. (2007) Fibroblast growth factor expression in the postnatal growth plate. *Bone* 40; 577–586.
- Matsumoto, K., Nagayasu, T., Hishikawa, Y., Tagawa, T., Yamayoshi, T., Abo, T., Tobinaga, S., Furukawa, K. and Koji, T. (2009) Keratinocyte growth factor accelerates compensatory growth in the remaining lung after trilobectomy in rats. *J. Thorac. Cardiovasc. Surg.* 137; 1499–1507.
- Matsuo, Y., Nomata, K., Eguchi, J., Aoki, D., Hayashi, T., Hishikawa, Y., Kanetake, H., Shibata, Y. and Koji, T. (2007) Immunohistochemical analysis of connexin43 expression in infertile human testes. *Acta Histochem. Cytochem.* 40; 69–75.
- Miki, T., Bottaro, D. P., Fleming, T. P., Smith, C. L., Burgess, W. H., Chan, A. M. and Aaronson, S. A. (1992) Determination of ligand-binding specificity by alternative splicing: two distinct growth factor receptors encoded by a single gene. *Proc. Natl. Acad. Sci. USA* 89; 246–250.
- Nakanishi, T., Nishida, T., Shimo, T., Kobayashi, K., Kubo, T., Tamatani, T., Tezuka, K. and Takigawa, M. (2000) Effects of CTGF/Hcs24, a product of a hypertrophic chondrocyte-specific gene, on the proliferation and differentiation of chondrocytes in culture. *Endocrinology* 141; 264–273.
- Nakazawa, K., Yashiro, M. and Hirakawa, K. (2003) Keratinocyte growth factor produced by gastric fibroblasts specifically stimulates proliferation of cancer cells from scirrhous gastric carcinoma. *Cancer Res.* 63; 8848–8852.
- Panos, R. J., Bak, P. M., Simonet, W. S., Rubin, J. S. and Smith, L. J. (1995) Intratracheal instillation of keratinocyte growth factor decreases hyperoxia-induced mortality in rats. *J. Clin. Invest.* 96; 2026–2033.
- Rousche, K. T., Ford, B. C., Praul, C. A. and Leach, R. M. (2001) The use of growth factors in the proliferation of avian articular chondrocytes in a serum-free culture system. *Connect. Tissue Res.* 42; 165–174.
- Rubin, J. S., Osada, H., Finch, P. W., Taylor, W. G., Rudikoff, S. and Aaronson, S. A. (1989) Purification and characterization of a newly identified growth factor specific for epithelial cells. *Proc. Natl. Acad. Sci. USA* 86; 802–806.
- Rubin, J. S., Bottaro, D. P., Chedid, M., Miki, T., Ron, D., Cheon, G., Taylor, W. G., Fortney, E., Sakata, H., Finch, P. W. and LaRochelle, W. J. (1995) Keratinocyte growth factor. *Cell Biol. Int.* 19; 399–411.
- Shirendeb, U., Hishikawa, Y., Moriyama, S., Win, N., Thu, M. M., Mar, K. S., Khatanbaatar, G., Masuzaki, H. and Koji, T. (2009) Human papillomavirus infection and its possible correlation with p63 expression in cervical cancer in Japan, Mongolia, and Myanmar. *Acta Histochem. Cytochem.* 42; 181–190.
- Sugahara, K., Tokumine, J., Teruya, K. and Oshiro, T. (2006) Alveolar epithelial cells: differentiation and lung injury. *Respirology* 11; 28–31.
- Tamaru, N., Hishikawa, Y., Ejima, K., Nagasue, N., Inoue, S., Muramatsu, M., Hayashi, T. and Koji, T. (2004) Estrogen receptor-associated expression of keratinocyte growth factor and its possible role in the inhibition of apoptosis in human breast cancer. *Lab. Invest.* 84; 1460–1471.
- Toh, W. S., Liu, H., Heng, B. C., Rufaihah, A. J., Ye, C. P. and Cao, T. (2005) Combined effects of TGFβ1 and BMP2 in serum-free chondrogenic differentiation of mesenchymal stem cells induced hyaline-like cartilage formation. *Growth Factors* 23; 313–321.
- van den Berg, W. B., van der Kraan, P. M., Scharstuhl, A. and van Beuningen, H. M. (2001) Growth factors and cartilage repair. *Clin. Orthop. Relat. Res.* 391; 244–250.
- van Osch, G. J., van der Veen, S. W. and Verwoerd-Verhoef, H. L.

- (2001) In vitro redifferentiation of culture-expanded rabbit and human auricular chondrocytes for cartilage reconstruction. *Plast. Reconstr. Surg.* 107; 433–440.
33. Wang, L. and Detamore, M. S. (2009) Effects of growth factors and glucosamine on porcine mandibular condylar cartilage cells and hyaline cartilage cells for tissue engineering applications. *Arch. Oral Biol.* 54; 1–5.
34. Weksler, N. B., Lunstrum, G. P., Reid, E. S. and Horton, W. A. (1999) Differential effects of fibroblast growth factor (FGF) 9 and FGF2 on proliferation, differentiation and terminal differentiation of chondrocytic cells in vitro. *Biochem. J.* 342; 677–682.
35. Wood, F. M., Kolybaba, M. L. and Allen, P. (2006) The use of cultured epithelial autograft in the treatment of major burn wounds: eleven years of clinical experience. *Burns* 32; 538–544.
36. Yamamoto-Fukuda, T., Aoki, D., Hishikawa, Y., Kobayashi, T., Takahashi, H. and Koji, T. (2003) Possible involvement of keratinocyte growth factor and its receptor in enhanced epithelial-cell proliferation and acquired recurrence of middle-ear cholesteatoma. *Lab. Invest.* 83; 123–136.
37. Yamayoshi, T., Nagayasu, T., Matsumoto, K., Abo, T., Hishikawa, Y. and Koji, T. (2004) Expression of keratinocyte growth factor/fibroblast growth factor-7 and its receptor in human lung cancer: correlation with tumour proliferative activity and patient prognosis. *J. Pathol.* 204; 110–118.

This is an open access article distributed under the Creative Commons Attribution License, which permits unrestricted use, distribution, and reproduction in any medium, provided the original work is properly cited.
