

From Bone Marrow Necrosis to Gaucher Disease; A Long Way to Run

Kemik İliği Nekrozundan Gaucher Hastalığı Tanısına Uzun Yol

To the Editor,

Bone marrow necrosis (BMN) is a disease characterized with fever and bone pain and caused by many different malignancies, benign diseases and drugs. We reported a case of BMN due to diclofenac in 2006 [1]. And now we present the same patient with a corrected diagnosis, seven years after the first presentation.

A 26-year-old male presented with fever, bone pain, splenomegaly, anemia, leucopenia and was diagnosed with BMN due to diclofenac consumption. Nine months after his initial admission, his laboratory and physical examination were normal. Seven year after diagnosis, he was admitted to hospital due to bone pain. He had splenomegaly, leukocyte level was $6.22 \times 10^9/L$, hemoglobin level was 13.7 g/dL and thrombocyte level was $152 \times 10^9/L$. Because of history of BMN and recurring splenomegaly, bone marrow aspiration and biopsy were performed. He was diagnosed with Gaucher disease in bone marrow biopsy and diagnosis was also confirmed by pathology. He had low glucosylceramide level (0.53 $\mu\text{kat/kg}$ protein, normal range 2.4-3.8 $\mu\text{kat/kg}$ protein) and high chitotriosidase level (2793 $\mu\text{kat/kg}$ protein, normal range <40 $\mu\text{kat/kg}$ protein). His treatment was started with imiglucerase. When we retrospectively reevaluated the first bone marrow aspiration which had been made 7 years before, we saw that Gaucher cells were also present (Figure 1).

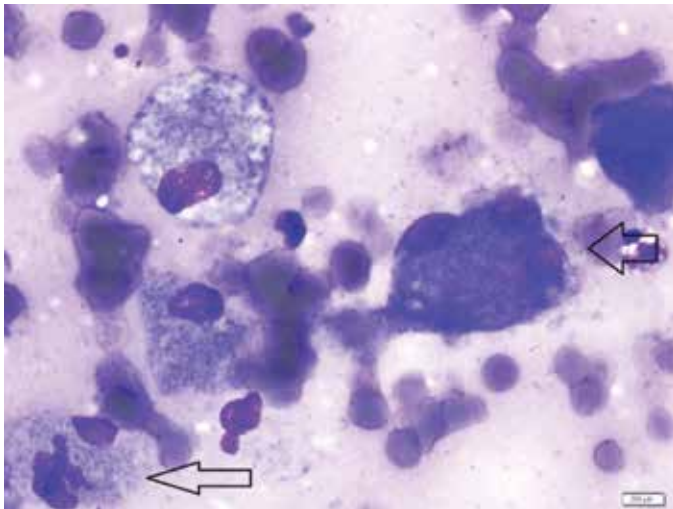


Figure 1. Gaucher cells, striated and fibrillary like cytoplasm with small dense nucleus.

Gaucher disease is an autosomal recessive, familial disease which presents with hepatosplenomegaly, skin pigmentation, bone lesions, anemia, leukopenia and thrombocytopenia. Interestingly, our patient was diagnosed with BMN and after 7 years, his diagnosis was corrected as Gaucher disease with new bone marrow biopsy and reevaluation of the first bone marrow biopsy. BMN is characterized by necrosis of the medullary stroma and myeloid tissues in bone marrow, because of failure of microcirculation. Chemotherapy, microvascular infarction, tumor necrosis factor, and thrombosis were blamed for the pathophysiology [2]. It's characterized with presence of amorphous eosinophilic material and ghost-like haematopoietic cells with irregular cell membranes. As seen in Figure 1, amorphous and corrupted appearance of the cells misled us. But when inspected carefully, typical Gaucher cells can be seen. Gaucher disease is characterized by accumulation of glucosylceramide in spleen, liver and bone marrow due to lysosomal glucocerebrosidase deficiency [3]. There is usually latency in diagnosis of Gaucher disease because of its rarity and not thinking of the disease in the first step but in further steps. In our patient, BMN due to diclofenac consumption was diagnosed in the first place, but after recurring splenomegaly and bone pain, he was reevaluated and diagnosed with Gaucher disease. Gaucher disease can be easily confused with other hematological diseases and can be overlooked. This leads us to the conclusion that diagnosis of a disease is a long way and if we have doubts about the diagnosis or unexpected changes are present, we should check the diagnosis and make further investigations. Gaucher disease must be kept in mind while making differential diagnosis in patients with splenomegaly, bone pain and pancytopenia.

Concept: Neslihan Erdem, Ahmet Çizmecioglu, İsmet Aydoğdu, **Design:** Neslihan Erdem, Ahmet Çizmecioglu, İsmet Aydoğdu, **Data Collection or Processing:** Neslihan Erdem, Ahmet Çizmecioglu, İsmet Aydoğdu, **Analysis or Interpretation:** Neslihan Erdem, Ahmet Çizmecioglu, İsmet Aydoğdu, **Literature Search:** Neslihan Erdem, Ahmet Çizmecioglu, İsmet Aydoğdu, **Writing:** Neslihan Erdem, Ahmet Çizmecioglu, İsmet Aydoğdu.

Conflict of Interest: The authors of this paper have no conflicts of interest, including specific financial interests, relationships, and/or affiliations relevant to the subject matter or materials included.

Keywords: Necrosis, Gaucher, Bone marrow

Anahtar Sözcükler: Nekroz, Gaucher, Kemik iliği

Neslihan Erdem¹, Ahmet Çizmeçioğlu², İsmet Aydoğdu³

¹Celal Bayar University Faculty of Medicine, Department of Internal Medicine, Manisa, Turkey

²Karaman State Hospital, Clinic of Internal Medicine, Karaman, Turkey

³Celal Bayar University Faculty of Medicine, Department of Hematology, Manisa, Turkey

References

1. Aydogdu I, Erkurt MA, Ozhan O, Kaya E, Kuku I, Yitmen E, Aydin NE. Reversible bone marrow necrosis in a patient due to overdosage of diclofenac sodium. *Am J Hematol* 2006;81:298.
2. Bhasin TS, Sharma S, Chandey M, Bhatia PK, Mannan R. A case of bone marrow necrosis of an idiopathic aetiology: the report of a rare entity with review of the literature. *J Clin Diagn Res* 2012;7:525-528.
3. Rosenbaum H. Hemorrhagic aspects of Gaucher disease. *Rambam Maimonides Med J* 2014;5:e0039.

Address for Correspondence: Neslihan ERDEM, M.D.,

Celal Bayar University Faculty of Medicine, Department of Internal Medicine, Manisa, Turkey

Phone: +90 555 729 88 22

E-mail: nesliherdem@gmail.com

Received/Geliş tarihi: March 15, 2015

Accepted/Kabul tarihi: May 04, 2015

DOI: 10.4274/tjh.2015.0123



First Observation of Hemoglobin Kansas [β 102(G4)Asn→Thr, AAC>ACC] in the Turkish Population

Türk Toplumunda İlk Hemoglobin Kansas [β 102(G4)Asn→Thr, AAC>ACC] Gözlemi

To the Editor,

Hemoglobin (Hb) Kansas [β 102 (G4) Asn→Tyr, AAC>ACC] is an unstable abnormal hemoglobin with low oxygen affinity and increased dissociation. Hb Kansas has rarely been reported in the literature to date; the first case was defined in the state of Kansas of the United States [1]. The second reported case was a newborn baby with cyanosis from Sarajevo and the third was an elderly patient with polycythemia from Japan [2,3]. There has been no previous report from Turkey [4]. We herein report the first case of Hb Kansas from Turkey, an introduction of clinical significance.

Case: A 28-year-old male patient with cyanosis of the lips and fingertips was admitted to a hospital in the city of Malatya. He had peripheral cyanosis of the hands and feet on physical examination. Blood gas analysis showed low oxygen levels. Complete blood count, blood chemistry, and

cardiac echocardiography results were within normal levels. High-performance liquid chromatography results were as follows; HbA1: 63.6%, HbA2: 32.8%, HbF: 0.2%. Agarose gel electrophoresis was performed to distinguish HbA2, but a band was identified at the level of 39.7% in HbF, G zone, and between HbA1 and HbA2. A blood sample was transferred to our genetic diagnostic center. Following DNA extraction with a commercial kit (Roche, Germany) and amplification of the whole beta globin gene by standard PCR protocols, DNA sequencing (Applied Biosystems, USA) revealed an A to C substitution at nucleotide position 308 (Figure 1). This change was identified as HBB: c.308 A>C, known as Hb Kansas in the HbVar database [5].

Hb Kansas is one of four known hemoglobins with neutral substitutions, along with Hb Köln, Porto Alegre, and Genova [1].

The oxygen equilibrium of Hb Kansas has two unusual characteristics: low affinity for oxygen and low heme-heme interaction. The low oxygen affinity of Hb Kansas should be considered in the differential diagnosis of peripheral cyanosis, especially in the neonatal period and in cyanotic disease and polycythemia in the elderly.

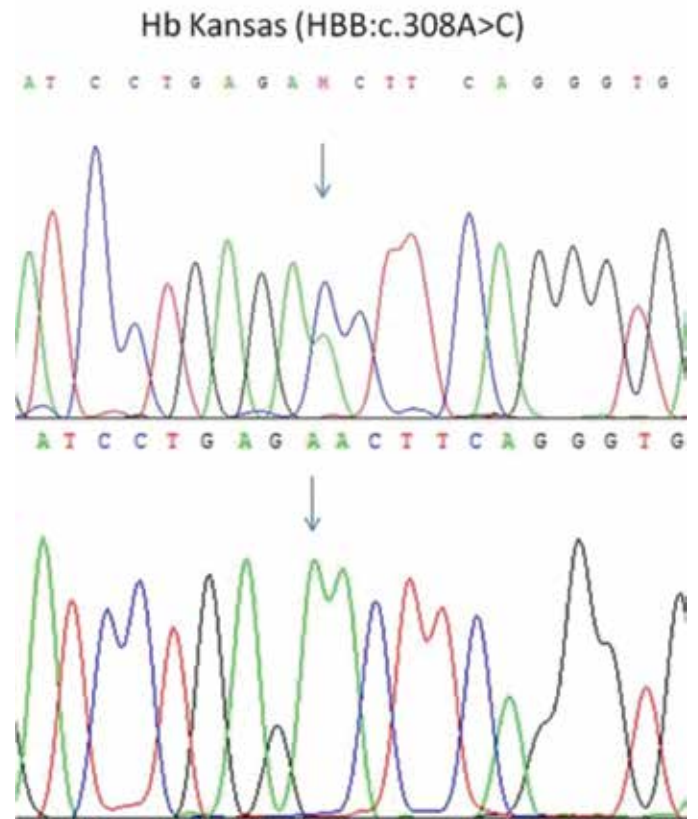


Figure 1. Hemoglobin Kansas in DNA sequencing.