



Contents lists available at ScienceDirect

Respiratory Medicine Case Reports

journal homepage: www.elsevier.com/locate/rmcr

Case Report

Infected lung bulla caused by *Neisseria elongata*: A case reportTetsuji Moriya^a, Akihiro Ohsumi^{a,*}, Kiminobu Tanizawa^b, Yasufumi Matsumura^c, Hiroshi Date^a^a Department of Thoracic Surgery, Kyoto University Hospital, 54 Shogoin-Kawahara-cho, Sakyo-ku, Kyoto, 606-8507, Japan^b Department of Respiratory Medicine, Kyoto University Hospital, 54 Shogoin-Kawahara-cho, Sakyo-ku, Kyoto, 606-8507, Japan^c Department of Infection Control and Prevention, Kyoto University Hospital, 54 Shogoin-Kawahara-cho, Sakyo-ku, Kyoto, 606-8507, Japan

ARTICLE INFO

Keywords:

Infected lung bulla
Neisseria elongata
 Mass spectrometry

ABSTRACT

Neisseria elongata is a rod-shaped, Gram-negative, aerobic bacterium that is part of the normal oral bacterial flora. Although previously considered a non- or low-pathogenic organism, the development of bacterial detection methods has resulted in increased reports of *N. elongata* infections such that it has recently been recognized as a causative agent of serious infections even in non-immune-compromised patients.

A 77-year-old man with rheumatoid arthritis-associated interstitial lung disease, chronic obstructive pulmonary disease, and diabetes mellitus was diagnosed with a nodule in the left lower lobe of his lung. Thoracoscopic wedge resection was performed, and pus was discharged from the specimen. Mass spectrometry of the swab culture revealed *N. elongata*. The patient's postoperative course was uneventful, and he was doing well without recurrence at 13 months after surgery. Since *N. elongata* is an oral bacterial flora, the patient consulted a local dentist, and decayed teeth were extracted.

Most of the reported cases of serious *N. elongata* infections have described infective endocarditis. This is the first report of infected lung bulla due to *N. elongata* infection, which demonstrates a new pathogenicity.

1. Introduction

Infected lung bulla is a severe infection that is often associated with oral hygiene. *Neisseria elongata* is a rod-shaped Gram-negative bacterium found in the human nasopharynx and oral flora. Although *N. elongata* was previously considered a low pathogenic bacterium differing from *N. meningitidis* and *N. gonorrhoeae*, reports of serious *N. elongata* infection cases are increasing. Herein, we report the first case of infected lung bulla caused by *N. elongata*.

2. Case report

A 77-year-old man with rheumatoid arthritis (RA), RA-associated interstitial lung disease, chronic obstructive pulmonary disease, chronic kidney disease, and diabetes mellitus was referred to our hospital because of a growing pulmonary nodule. One year previously, a new nodule 25 mm in diameter with niveau formation along a bulla wall was detected incidentally in his left lower lobe on an annual chest computed tomography (CT) scan (Fig. 1A). One month later, the nodule had decreased in size to a diameter of 19 mm (Fig. 1B); however, it further increased in size to a diameter of 25 mm with niveau formation at the 6-month follow-up (Fig. 1C). Fluoro-

* Corresponding author. Department of Thoracic Surgery, Kyoto University Hospital, 54 Shogoin-Kawahara-cho, Sakyo-ku, Kyoto, 606-8507, Japan.
 E-mail address: akohsumi@kuhp.kyoto-u.ac.jp (A. Ohsumi).

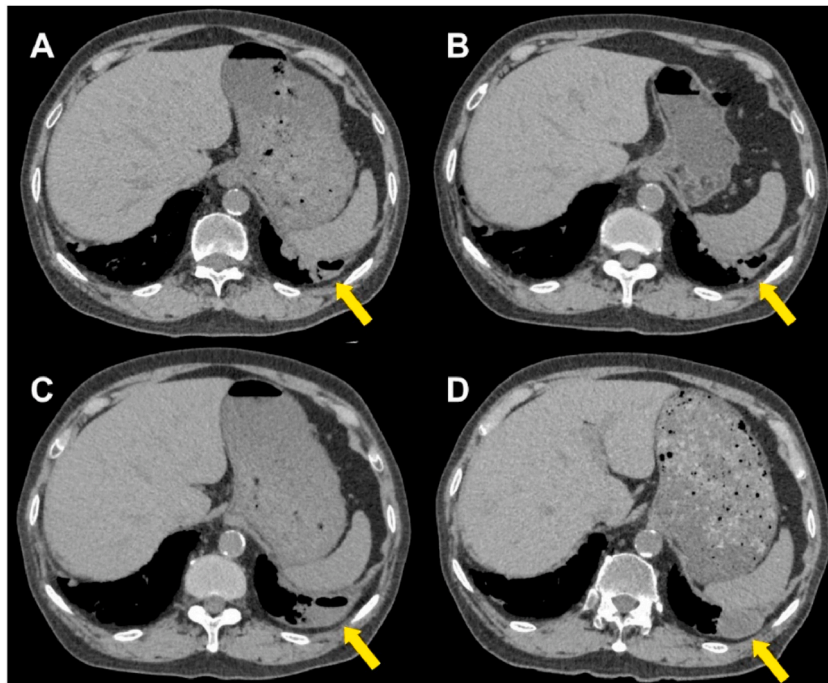


Fig. 1. (A–D) Plain chest computed tomography. These images show the nodule (arrow) in the left lower lobe in the order of time series. A: One year previous from the surgery. B: Eleven months previous from the surgery. C: Five months previous from the surgery. D: Three and a half months previous from the surgery.

rodeoxyglucose-positron emission tomography (FDG-PET) showed increased FDG uptake in the lesion (maximal standardized uptake value [SUV_{max}] = 3.8) (Fig. 2). The plasma β -D-glucan level was elevated to 17.0 pg/mL (cut-off value = 11.0 pg/mL). Owing to a suspected fungal infection, oral voriconazole (300 mg/day) was administered. The 1.5-month follow-up CT showed further growth of the nodule with nodule resolution and a cavity filled with low-density content (Fig. 1D), suggesting the need to rule out the possibility of lung cancer. Therefore, surgical resection of the nodule was planned.

On admission, the patient was asymptomatic except for knee arthralgia. He was taking 7 mg prednisolone, 1 mg tacrolimus, and 300 mg voriconazole daily. The immunosuppressive medication was maintained at the same dose for about 1 year and the antifungal agent was taken for 3 months prior to the surgery. Physical examination revealed fine inspiratory crackles at both lung bases as well as rheumatoid joint changes. As a summary of preoperative examinations, laboratory tests revealed a slight elevation of serum C-reactive protein (0.7 mg/dL) and mild renal dysfunction with a serum creatinine concentration of 1.28 mg/dL. His hemoglobin A1c level improved from 8.0% to 6.7% after 1 month of insulin therapy. The patient's carcinoembryonic antigen (CEA), cytokeratin 19 fragment (CYFRA), and squamous cell carcinoma (SCC) antigen levels were within the reference range. Pulmonary function tests revealed obstructive impairment, with 63% forced expiratory volume in 1 second (FEV₁%) and severe diffusing capacity impairment at 34% of the predicted diffusing capacity of carbon monoxide (DLCO). Chest CT, taken prior to the hospitalization, showed emphysematous changes, reticular opacities, and an increase in nodule size to 43 mm (Fig. 1D).

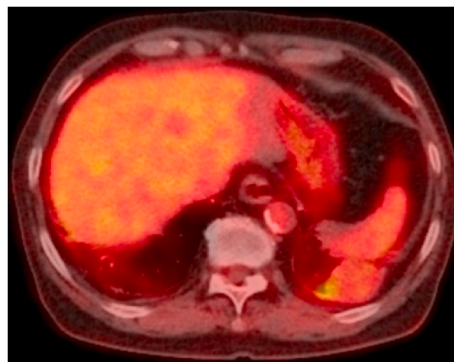


Fig. 2. Positron emission tomography-computed tomography. This shows the increased fluorodeoxyglucose uptake in the nodule.

The patient underwent thoroscopic surgery. The left lower lobe around the lesion was adhered to the parietal pleura and diaphragm, and inflammatory changes around the nodule were suspected. Pulmonary wedge resection, including the lesion in the left lower lobe, was performed. Excision of the extracted specimen revealed viscous pus discharge from the nodule.

The postoperative course was uneventful, and the patient was discharged on postoperative day six. Gram staining of two sets of culture swabs sampled from the discharge revealed numerous leukocytes, but no organisms. Fungal and acid-fast bacilli cultures were negative. However, a single isolate was obtained in both samples after incubation, and *N. elongata* was identified by matrix-assisted laser desorption ionization time-of-flight (MALDI-TOF) mass spectrometry (Microflex LT, MBT Compass ver. 4.1; Bruker, Billerica, MA, USA). The score value of *N. elongata* in MALDI-TOF was 2.26 and that of other bacteria was less than 2.0. This result was classified in the high consistency category. Pathological examination of the resected lung revealed inflammatory changes in the bulla, without any malignant tumors or nodular lesions. No bacterial or fungal pathogen was demonstrated by Gram, periodic acid-Schiff (PAS), and Grocott stainings. Finally, the patient was diagnosed with infected lung bulla caused by *N. elongata*. As *N. elongata* is part of the normal oral bacterial flora, the patient was referred to a local dentist. Dental caries and periodontitis were diagnosed, and the decayed teeth were extracted. Since there were no signs of systemic inflammation, we decided not to administer any adjuvant antibiotics. The patient has been doing well for 13 months after surgery.

3. Discussion

N. elongata was first reported by Bovre and Holten in 1970. It is a slender, rod-shaped, Gram-negative, non-motile, non-saccharolytic, aerobic bacterium belonging to the genus *Neisseria*, which is typically spherical [1]. Its morphological appearance resembles those of *Eikenella*, *Moraxella*, and *Kingella*, which are also classified as *Neisseriaceae* [2]. It is often arranged as diplobacilli or in short chains. Moreover, it sometimes appears to be coccial, which changes uniformly into long filaments in other cultures [1]. This heterogeneity in appearance makes it difficult to assign *N. elongata* by the conventional bacterial identification flow of Gram staining followed by biochemical identification kits. The *Neisseriaceae* family normally exists in the oropharynx, vagina, and colon; thus, *N. elongata* can be found in the human nasopharynx [1].

N. meningitidis and *N. gonorrhoeae* are well known to be pathogenic, whereas infections due to other *Neisseria* genera, including *N. elongata*, are rare. However, *N. elongata* is increasingly recognized as an important pathogenic cause of serious infections, such as infective endocarditis [3–5], septicemia [6], and osteomyelitis [7,8]. The three subspecies of *N. elongata* (*N. elongata* subsp. *elongata*, subsp. *glycolytica*, and subsp. *nitroreducens*) [9] are classified according to their biochemical differences. Of these, *N. elongata* subsp. *nitroreducens* is considered the primary pathogenic agent [10]. Although *N. elongata* is susceptible to many antibiotics, when infective endocarditis occurs, surgical intervention is often required [10]. While most reported cases occur in immunocompromised patients, *N. elongata* infection occasionally occurs in patients without any risks [11,12].

As mentioned above, its shape after Gram staining and uncharacteristic colony appearance, grayish-white color, and opaque appearance after incubation on blood agar [1] can easily lead to the misdiagnosis of *N. elongata* as other bacteria by conventional identification methods [13]. Due to this difficulty and/or a lack of reports, many cases of *N. elongata* infection may not have been diagnosed accurately. However, new microbial inspection methods such as 16S ribosomal DNA gene sequencing and MALDI-TOF mass spectrometry have recently become available as accurate methods for identifying microorganisms [14], with the latter proving to be helpful in our case. Although these new methods cannot be used to identify subspecies, they reliably identify *N. elongata* at the species level [4,13,15]. The result of MALDI-TOF in our case was highly reliable based on the score value and the environment the samples were taken in Refs. [3,5]. Biochemical tests, such as catalase and nitrate, are useful for precise identification to the subspecies level [6]. Due to our knowledge limitations, the isolated *N. elongata* was not confirmed by 16S ribosomal DNA sequencing, which is not a practical method in our institution. In addition, the subspecies were not identified by biochemical reaction tests in combination with MALDI-TOF mass spectrometry because of the loss of the bacterial strain.

Antimicrobial susceptibility was determined by the broth microdilution method using DryPlate Eiken (Eiken Chemical, Tokyo, Japan) according to the Clinical and Laboratory Standards Institute (CLSI) guidelines [16], the results of which are shown in Table 1. It is difficult to determine the susceptibilities of *N. elongata* isolates due to the lack of minimum inhibitory concentration (MIC) breakpoints. However, a previous report suggested good *in vitro* activity of commonly used antimicrobials [4]. As the infected lung bulla was completely dissected, adjuvant antibiotics were unnecessary in our case.

Although reports of *N. elongata* infections have increased, those of infections other than endocarditis and bacteremia are rare (Table 2). To our knowledge, this is the first report of infected lung bulla caused by *N. elongata*. Since two sets of pus samples were obtained directly from the surgical specimen and both culture swabs showed the presence of *N. elongata*, we concluded that this bacterium had caused the formation of infected lung bullae. Since the patient presented no signs of infective endocarditis, further examinations were not conducted. Older age, severe emphysema, immunosuppression due to steroids and tacrolimus, diabetes, and comorbidity with caries and periodontitis were risk factors in the present case.

4. Conclusion

In conclusion, we experienced the first case of infected lung bulla caused by *N. elongata*. Although *N. elongata* was previously assumed to be a non-pathogenic or low-pathogenic bacterium, it can cause severe infections in various circumstances.

Funding

This case report did not receive any specific grant from funding agencies in the public, commercial, or not-for-profit sectors.

Table 1
Antimicrobial susceptibility of the *N. elongata* isolate.

Antibiotics	MIC ($\mu\text{g/mL}$)
Ampicillin (ABPC)	≤ 0.12
Penicillin (PCG)	0.12
Clavulanic acid/Amoxicillin (CVA/AMPC)	≤ 2.0
Sulbactam/Ampicillin (SBT/ABPC)	≤ 2.0
Tazobactam/Piperacillin (TAZ/PIPC)	≤ 1.0
Cefepime (CFPM)	≤ 0.5
Cefotaxime (CTX)	≤ 0.125
Cefdinir (CFDN)	≤ 0.5
Cefoxitin (CFX)	≤ 4.0
Meropenem (MEPM)	≤ 0.25
Imipenem/Cilastatin (IPM/CS)	≤ 0.12
Gentamicin (GM)	≤ 4.0
Azithromycin (AZM)	≤ 0.25
Clarithromycin (CAM)	≤ 1.0
Erythromycin (EM)	> 0.5
Clindamycin (CLDM)	> 0.5
Ciprofloxacin (CPFX)	> 0.06
Levofloxacin (LVFX)	> 0.03
Minocycline (MINO)	≤ 2.0
Linezolid (LZD)	> 4.0
Teicoplanin (TEIC)	> 8.0
Vancomycin (VCM)	> 16.0
Daptomycin (DAP)	> 1.0
Fosfomycin (FOM)	≤ 64.0
Sulfamethoxazole-trimethoprim (ST)	> 2.5
Rifampicin (RFP)	≤ 0.5

MIC, minimum inhibitory concentration.

Table 2
Characteristics of previous reports of *N. elongata* infections other than endocarditis and bacteremia.

References (year)	Infections	Subspecies of <i>N. elongata</i>	Identification methods	Risk factors	Mainly used antibiotics
Miler (1985) [17]	Vaginal infection	Not specified	N/D	N/D	N/D
Garner (1986) [7]	Osteomyelitis	Not specified	Biochemical reactions	Extraction of tooth	Benzylpenicillin
Saha (2009) [18]	Septic arthritis	<i>glycolytica</i>	N/D	None	Amoxicillin
Bousquet (2013) [14]	Spondylodiscitis, endocarditis	<i>nitroreducens</i>	Biochemical reactions, rDNA sequencing	Prosthetic valve replacement	Ampicillin, ciprofloxacin
Lin (2014) [19]	Peritonitis	<i>glycolytica</i>	Biochemical reactions	Peritoneal dialysis, poor nutrition	Gentamicin, ceftriaxone
Knox (2015) [15]	Septic arthritis	<i>nitroreducens</i>	Mass spectrometry, biochemical reactions, rDNA sequencing	Intra-articular injection of cortisone, dental procedure	Ceftriaxone
Grandolfo (2016) [20]	Urethritis, balanoposthitis	<i>nitroreducens</i>	Biochemical reactions,	Repetitive traumatic oral sex	Ceftriaxone
Spielman (2020) [8]	Osteomyelitis	Not specified	Biochemical reactions	Morbid obesity (BMI 35), PVD, extremity wounds, DM, CKD (dialysis)	Ceftazidime

N. elongata, *Neisseria elongata*; N/D, no data; rDNA, ribosomal deoxyribonucleic acid; BMI, body mass index; PVD, peripheral vascular disease; DM, diabetes mellitus; CKD, chronic kidney disease.

Authorship statement

T.M and A.O managed the case, prepared, and revised the draft. K.T managed the case, assisted, and revised the draft. Y.M assisted and revised the draft. H.D supervised and revised the draft. All authors approved the final manuscript and meet the ICMJE authorship criteria.

Declarations of competing interest

None.

References

- [1] K. Bøvre, F. Holtén, *Neisseria elongata* sp. nov., a rod-shaped member of the genus *Neisseria*. Re-evaluation of cell shape as a criterion in classification, *J. Gen. Microbiol.* 60 (1) (1970) 67–75, <https://doi.org/10.1099/00221287-60-1-67>.
- [2] L.J. Haddow, C. Mulgrew, A. Ansari, J. Miell, H. Malnick, G.G. Rao, *Neisseria elongata* endocarditis: case report and literature review, *Clin. Microbiol. Infect.* 9 (2003) 426–430, <https://doi.org/10.1046/j.1469-0691.2003.00533.x>.
- [3] T. Fasciana, F.D. Gaudio, S. Novo, G. Aquilina, S. Indelicato, G. Giordano, et al., Rapid identification by MALDI-TOF of *Neisseria elongata* subspecies nitroreducens in an endocarditis case, *J. Immunol. Tech. Infect. Dis.* 5 (2016) 1, <https://doi.org/10.4172/2329-9541.1000137>.
- [4] H. Osuka, A. Ichiki, M. Yamamoto, D. Kawahata, Y. Saegusa, T. Oishi, et al., Native valve endocarditis caused by *Neisseria elongata* subsp. nitroreducens, *Intern. Med.* 54 (2015) 853–856, <https://doi.org/10.2169/internalmedicine.54.2738>.
- [5] M. Foissac, L. Bergon, M. Mourguet, L. Prudhomme, S. Khatibi, Native mitral valve endocarditis due to *Neisseria elongata* following an untreated dental abscess, *Germes* 10 (2) (2020) 123–125, <https://doi.org/10.18683/germes.2020.1195>.
- [6] C. Hombrouck-Alet, I. Poilane, C. Janoir-Jouveshomme, O. Fain, P. Cruaud, M. Thomas, et al., Utilization of 16S ribosomal DNA sequencing for diagnosis of septicemia due to *Neisseria elongata* subsp. glycolytica in a neutropenic patient, *J. Clin. Microbiol.* 41 (2003) 3436–3437, <https://doi.org/10.1128/JCM.41.7.3436-3437.2003>.
- [7] J. Garner, R.H. Briant, Osteomyelitis caused by a bacterium known as M-6, *J. Infect.* 13 (1986) 298–300, [https://doi.org/10.1016/s0163-4453\(86\)91487-8](https://doi.org/10.1016/s0163-4453(86)91487-8).
- [8] A.F. Spielman, A. Ghumman, Z. Panthaki, A. Lessard, *Neisseria elongata* osteomyelitis: literature review and case report in a 63-year-old male presenting with progressive right-handed redness, swelling and pain, *Int. J. Surg. Case Rep.* 4472 (2020) 228–230, <https://doi.org/10.1016/j.ijscr.2020.07.022>.
- [9] B.M. Andersen, R.S. Weyant, A.G. Steigerwalt, C.W. Moss, D.G. Hollis, R.E. Weaver, et al., Characterization of *Neisseria elongata* subsp. glycolytica isolates obtained from human wound specimens and blood cultures, *J. Clin. Microbiol.* 33 (1995) 76–78, <https://doi.org/10.1128/jcm.33.1.76-78.1995>.
- [10] E.A. Dominguez, T.L. Smith, Endocarditis due to *Neisseria elongata* subspecies nitroreducens: case report and review, *Clin. Infect. Dis.* 26 (1998) 1471–1473, <https://doi.org/10.1086/517671>.
- [11] M. Samannodi, S. Vakkalanka, A. Zhao, M. Hocko, *Neisseria elongata* endocarditis of a native aortic valve, *BMJ Case Rep.* (2016) 1–4 <https://doi.org/10.1136/ber-2015-213311>, 2016.
- [12] D. Youssef, T.S. Marroush, M.T. Levine, M. Sharma, Endocarditis due to *Neisseria elongata*: a case report and review of the literature, *Germes* 9 (2019) 188–192, <https://doi.org/10.18683/germes.2019.1176>.
- [13] M. Evans, F. Yazdani, H. Malnick, J.J. Shah, D.P.J. Turner, Prosthetic valve endocarditis due to *Neisseria elongata* subsp. elongata in a patient with Klinefelter's syndrome, *J. Med. Microbiol.* 56 (2007) 860–862, <https://doi.org/10.1099/jmm.0.47155-0>.
- [14] A. Bousquet, C. Soler, C. Martinaud, C.M. Nab, E. Perrier, Endocarditis and spondylodiscitis due to *Neisseria elongata* subsp. nitroreducens, *Med. Mal. Infect.* 43 (2013) 435–437, <https://doi.org/10.1016/j.medmal.2013.07.008>.
- [15] J. Knox, S. Hume, D. Johnson, Sternoclavicular septic arthritis caused by *Neisseria elongata* subspecies nitroreducens, *Pathology* 47 (5) (2015) 490–491, <https://doi.org/10.1097/PAT.0000000000000284>.
- [16] Clinical and Laboratory Standards Institute, *Methods for Dilution Antimicrobial Susceptibility Tests for Bacteria that Grow Aerobically; Approved Standard—Tenth Edition. CLSI M07-A10*, Clinical and Laboratory Standards Institute, Wayne, PA, 2015.
- [17] K. Miller, W. Hansen, M. Labbé, F. Crokaert, E. Yourassowsky, T. Hubert, Isolation of *Neisseria elongata* and of *Capnocytophaga ochracea* from vaginal specimens, *J. Infect.* 10 (2) (1985) 174–175, [https://doi.org/10.1016/s0163-4453\(85\)91690-1](https://doi.org/10.1016/s0163-4453(85)91690-1).
- [18] A. Saha, S. Agarwal, T. Gibson, Septic arthritis: an extensive variety of pathology, *BMJ Case Rep.* 3 (2009) 1642, <https://doi.org/10.1136/ber.03.2009.1642>.
- [19] M. Lin, G.K. Yang, M.Z. Gao, F.Y. Hong, Peritoneal dialysis-related peritonitis caused by *Neisseria elongata* subsp. nitroreducens, the first report, *Perit. Dial. Int.* 34 (7) (2014) 816–817, <https://doi.org/10.3747/pdi.2013.00114>.
- [20] M. Grandolfo, M. Vestita, D. Bonamonte, A. Filoni, Acute urethritis and balanoposthitis associated to *Neisseria elongata*, *Sex. Transm. Dis.* 43 (12) (2016) 778–779, <https://doi.org/10.1097/OLQ.0000000000000532>.