

Michael R. Pranzatelli,
MD
Nathan R. McGee, BS

*Neurol Neuroimmunol
Neuroinflamm*
2018;5:e433; doi: 10.1212/
NXI.0000000000000433

NEUROIMMUNOLOGY OF OMS AND ANNA-1/ ANTI-HU PARANEOPLASTIC SYNDROMES IN A CHILD WITH NEUROBLASTOMA

OPEN

Paraneoplastic neurologic disorders have been at the frontier of neuroimmunology for decades and remain urgent. Newer tools for the diagnosis and treatment of neuroinflammation include autoantibody screening, lymphocyte subset analysis, oligoclonal bands, and profiling of chemokines/cytokines and brain-related proteins in CSF and blood/serum. Opsoclonus-myoclonus syndrome (OMS), a paraneoplastic disorder without a known diagnostic antibody marker, is associated with remote neuroblastoma and is often relapsing.¹ Paraneoplastic encephalomyelitis with type 1 antineuronal nuclear antibodies (ANNA-1) (alias anti-Hu)² also may occur in children with neuroblastoma^{3–5} and exhibits intrathecal B- and T-cell inflammation in adults.⁶ We now provide a detailed neuroimmunologic profile of a child with both relapsing OMS and ANNA-1 paraneoplastic syndromes and neuroblastoma.

Methods. Description of the clinical and laboratory methods is provided at <http://links.lww.com/NXI/A17>.

Case report. The clinical course is summarized in table e-1 at <http://links.lww.com/NXI/A18>. Pelvic stage II neuroblastoma was detected in a 16-month-old child who was presented with OMS. She received IV immunoglobulin (IVIg) and prednisone but was referred after illness-triggered relapse, treated with high-dose corticotropin, IVIg, and low-dose cyclophosphamide \times 6 with good response (figure).

Twenty-nine months after tumor resection, new-onset seizures heralded devastating ANNA-1 encephalitis (serum titer 1:122,000 and CSF 1:256) without tumor recurrence. Other paraneoplastic serology and CSF viral studies were negative. Near-daily seizures were of various types, predominantly complex partial, the EEG became epileptiform, and multiple antiepileptic drugs (AEDs) were tried. The patient improved on rituximab \times 4, corticotropin dose escalation, and continued IVIg. Head MRI with and without contrast was normal.

However, medically intractable “left temporal lobe epilepsy,” a unilateral left mesial temporal epileptic focus on EEG, and a corresponding hypometabolic

area on PET, led to left anterior temporal lobectomy elsewhere. The surgical pathology report disclosed focal neuronal loss and gliosis in the hippocampus, focal perivascular chronic inflammation and gliosis in the amygdala, and focal subpial gliosis and cortical dysplasia in the temporal lobe.

For another relapse, 6 monthly dexamethasone pulses replaced corticotropin, and she improved.

Neuroimmunologic studies. After the first OMS relapse treatment, a mildly elevated CSF memory B-cell frequency was normalized. The low helper-inducer (CD4⁺) to cytotoxic/suppressor (CD8⁺) T-cell ratio (<1; controls, \geq 2.5) suggested T-cell dysregulation.

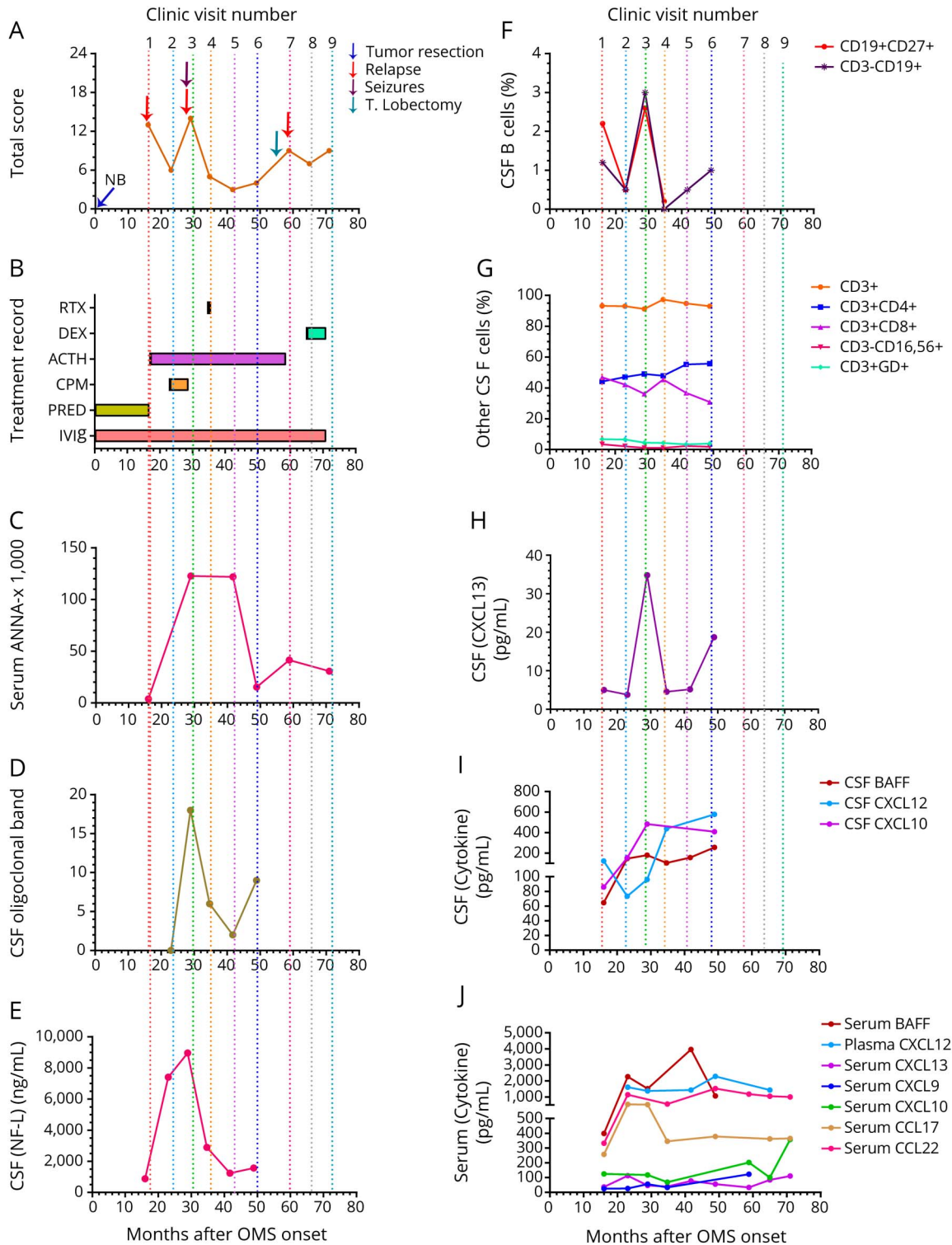
With the emergent ANNA-1 syndrome, there was a precipitous rise in the CSF total and memory B-cell frequency, oligoclonal band positivity (18 bands), concentrations of inflammatory chemokines/cytokines (CXCL13, CXCL10, and BAFF), and a neuronal/axonal injury biochemical marker (neurofilament light chain), as well as sudden drop in the homeostatic chemokine CXCL12. Serum BAFF and CSF/serum CXCL13 ratios spiked. Testing of the initial sample revealed very low titer serum ANNA-1 antibodies preceding the first seizure by \geq 10 months.

When rituximab was given adjunctively, intrathecal inflammation rapidly abated. Serum ANNA-1 antibodies, which remained high for 10 months before declining, persisted for years. However, she improved clinically, without seizures off AEDs or relapse of OMS or ANNA-1 syndrome off immunotherapy, and returned to school.

Discussion. This detailed neuroimmunologic report of a child with ANNA-1 paraneoplastic disorder which presented 2.4 years after OMS onset demonstrated multicomponent neuroinflammation. Although OMS and ANNA-1 encephalitis were clinically discrete, some patterns of neuroinflammation were shared. Biomarkers of disease activity and treatment reported in pediatric-onset OMS¹—high CSF memory B-cell frequency, intrathecal IgG oligoclonal band production, B-cell attractant CXCL13—were demonstrated in the second paraneoplastic syndrome, too. It is noteworthy that the dramatic spike in CSF neurofilament light chain, paralleling ANNA-1 titers, was reversible and

Supplemental data at
Neurology.org/nn

Figure Comparative timeline of events and observations



(A) Clinical events and total Score. Arrows indicate key events. OMS onset (time = 0). (B) Immunotherapy record: ACTH, CPM, DEX, IVIg, PRED, RTX. Standard dosing: RTX, 375 mg/m² IV weekly × 4; DEX, 20 mg/m² ÷ TID IV or po for 3–4 d/cycle/mo; ACTH, 75 IU/m² IM BID × 2 weeks, QD × 2 weeks, then tapered over 1 year; CPM, 750 mg/m² IV once monthly × 6; and IVIg, 1–2 g/kg monthly. (C) Serum ANNA-1 antibody titers. (D) CSF oligoclonal bands not found in serum (positive if ≥2). (E) CSF NFL concentration (controls, 200 ng/mL). (F) Frequency of CSF total B cells (CD19⁺ CD3⁻) and memory B cells (CD19⁺ CD27⁺) (control median, <2%). (G) Frequency of total CSF T cells (CD3⁺), T-cell subsets (CD4⁺, CD8⁺, and TCR-γ/δ⁺), and natural killer cells (CD3⁻ CD16⁺ and CD56⁺). Controls: CD4⁺ T cells, 60%–75% and CD8⁺ T cells, 20%–25%. (H) CSF CXCL13 concentration (control median, 1.7 pg/mL). (I) Other CSF chemokine/cytokine concentrations. Control medians (pg/mL): BAFF, 144; CXCL10, 109; and CXCL12, 550. (J) Serum chemokine/cytokine concentrations. Control medians with interquartile range: 167 (153–182) for BAFF; 1,770 (1,514–2,027) for CXCL12; 89 (84–94) for CXCL13; 48 (40–56) for CXCL9; 115 (99–130) for CXCL10; 359 (317–400) for CCL17; and 1,074 (1,010–1,139) for CCL22. ACTH = corticotropin; ANNA-1 = type 1 antineuronal nuclear antibody; CPM = cyclophosphamide; DEX = dexamethasone; IVIg = IV immunoglobulin; NB = neuroblastoma; NFL = neurofilament light chain; OMS = opsoclonus-myoclonus syndrome; PRED = prednisone; RTX = rituximab.

occurred concurrently with the neuroinflammation not as a delayed effect.

The occurrence of 2 paraneoplastic neurologic syndromes in the same child is rare as in adults.⁷ ANNA-1 limbic encephalitis after OMS was reported in a child with nonrecurrent pelvic neuroblastoma, unifocally hypermetabolic PET, and resultant temporal lobectomy (reactive astrocytosis and gliosis).⁵ However, no antibody titers were measured during the OMS diagnosis, and there was limited testing for neuroinflammation. The pelvic tumor location accounts for only 6% of neuroblastomas associated with OMS but could be coincidental. Ours is one of a few cases of ANNA-1 encephalitis associated with pelvic neuroblastoma and treated effectively with rituximab in children.

The phenotype of ANNA-1-associated paraneoplastic disorders is protean.^{3–5} In adults, limbic encephalitis, a manifestation of encephalomyelitis affecting the medial temporal lobe, displays hallmark seizures and memory impairment with or without focal MRI abnormalities.⁷ In small children, behavioral changes are more likely than demonstrable memory loss, but information is largely anecdotal.^{4,5} In our patient, seizures, not memory loss, dominated the phenotypic changes of the second paraneoplastic syndrome. In the absence of signs of neuropathy or myelitis in her case, the diagnosis of limbic encephalitis would seem to fit, although ANNA-1 “encephalitis” also would be suitable. The onset of seizures in a child presumed to have OMS should prompt the clinician to order serum ANNA-1 titers, as seizures are outside the usual OMS phenotype.¹

There are several clinical ramifications. Biomarkers of disease activity supported the use of anti-B-cell therapy¹ and normalized in correlation with clinical improvement. By contrast, steroids/corticotropin, IVIg, and cyclophosphamide failed to prevent the occurrence of ANNA-1. Persistent lower ANNA-1 serum antibody titers despite rituximab suggest production by plasma cells (lacking CD20), not CD20⁺ plasmablasts/memory B cells, and required no aggressive therapy in view of convalescence. Given the protracted recovery, the destructive nature of ANNA-1 paraneoplastic encephalitis/limbic encephalitis is not to be underestimated.

From the National Pediatric Myoclonus Center (M.R.P., N.R.M.); and National Pediatric Neuroinflammation Organization, Inc. (M.R.P.), Orlando, FL.

Author contributions: Michael R. Pranzatelli: conceptualization, data interpretation, and manuscript drafting and revision. Nathan R. McGee: data collection and analysis, laboratory assays, computer graphics, and manuscript revision.

Acknowledgment: Dr. Pranzatelli is a clinician-scientist; President and Founder of the National Pediatric Neuroinflammation Organization, Inc.; and an Adjoint Professor of Neurology at the University of Colorado School of Medicine. The National Pediatric Myoclonus Center relocated from Springfield, IL (SIU School of Medicine) to Orlando, FL, in 2014 to become the current independent, nonprofit organization. The authors thank Elizabeth D. Tate, MN, ARNP, C-FNP, who participated in clinical care, the patient, her family, and referring and treating physicians.

Study funding: No targeted funding reported.

Disclosure: The authors report no disclosures. Go to Neurology.org/nn for full disclosure forms. The Article Processing Charge was funded by the authors.

This is an open access article distributed under the terms of the Creative Commons Attribution-NonCommercial-NoDerivatives License 4.0 (CC BY-NC-ND), which permits downloading and sharing the work provided it is properly cited. The work cannot be changed in any way or used commercially without permission from the journal.

Received August 12, 2017. Accepted in final form November 8, 2017.

Correspondence to Prof. Pranzatelli: mpranzatelli@omsusa.org

1. Pranzatelli MR, Tate ED. Trends and tenets in relapsing and progressive opsoclonus-myoclonus syndrome. *Brain Dev* 2016;38:439–448.
2. King PH, Redden D, Plamgren JS, Nabors LB, Lennon VA. Hu antigen specificities of ANNA-1 autoantibodies in paraneoplastic neurological disease. *J Autoimmun* 1999;13:435–443.
3. Dalmau J, Graus F, Cheung NK, et al. Major histocompatibility proteins, anti-Hu antibodies, and paraneoplastic encephalomyelitis in neuroblastoma and small cell lung cancer. *Cancer* 1995;75:99–109.
4. Morales La Madrid A, Rubin CM, Kohrman M, Pytel P, Cohn SL. Opsoclonus-myoclonus and anti-Hu positive limbic encephalitis in a patient with neuroblastoma. *Pediatr Blood Cancer* 2012;58:472–474.
5. Langer JE, Lopes MB, Fountain NB, et al. An unusual presentation of anti-Hu-associated paraneoplastic limbic encephalitis. *Dev Med Child Neurol* 2012;54:863–866.
6. de Jongste AH, de Graaf MT, van den Broek PD, Kraan J, Smitt POA, Gratama JW. Elevated numbers of regulatory T cells, central memory T cells and class-switched B cells in cerebrospinal fluid of patients with anti-Hu antibody associated paraneoplastic neurological syndromes. *J Neuroimmunol* 2013; 254:85–90.
7. Ducray F, Graus F, Vigliani MC, et al. Delayed onset of a second paraneoplastic neurological syndrome in eight patients. *J Neurol Neurosurg Psychiatry* 2010;81:937–939.