



CLINICAL ARTICLE

Three-Dimensional Distribution of Bone-Resorption Lesions in Osteonecrosis of the Femoral Head Based on the Three-Pillar Classification

Guang-bo Liu, MD^{1#} , Qiang Lu, MD, PhD^{2#}, Hao-ye Meng, PhD², Qi Quan, MD, PhD², Yu-xuan Zhang, MD², Huo Li, MD², Hai-yang Ma, MD, PhD², Jun Zhao, MD², Peng Wang, MD², Xue-feng Zhou, MD¹, Jiang Peng, MD, PhD² 

¹Strategic Support Force Medical Center and ²Department of Orthopaedics, the First Medical Center, Chinese PLA General Hospital, Beijing, China

Objective: To investigate three-dimensional distribution of bone-resorptive lesions based on the three-pillar classification and its effect on the disease progression of osteonecrosis of the femoral head (ONFH).

Methods: A total of 194 femoral head CT images from 117 patients diagnosed with ARCO stage II and III ONFH were retrospectively reviewed from April 2014 to February 2019. Three-dimensional structures of the femoral head and the bone-resorptive lesions were reconstructed. Using the three-pillar classification and coronal plane of the femoral head, we divided each femoral head into six regions to observe the location characteristics of bone-resorption lesions, and explore the destruction of different areas of the femoral head by the bone-resorptive lesions. Then the hips were divided into two groups based on whether they contained bone-resorption lesions and compared the difference of stage II and stage III between the two groups.

Results: The regional distribution revealed 39 (27.27%), 55 (38.46%), six (4.20%), 23 (16.08%), 17 (11.89%) and three (2.10%) bone-resorptive lesions in regions I, II, III, IV, V and VI respectively. The lateral pillar, AL (I + IV), contained 44.76% of the lesions, central pillar, C (II + V), 48.95%, and medial pillar, M (III + VI), 6.29%. Moreover, there were 81.82% bone-resorption lesions in anterolateral pillar, AL (I + II + IV), and 18.18% in posteromedial pillar, PM (III + V + VI). In all ONFH hips, the lateral pillar of 81(88.04%) femoral heads were affected, the central pillar of 84 (91.30%) femoral heads were affected, and the medical pillar of 29 (31.52%) femoral heads were affected. The ratio of ARCO stage III in the group with bone-resorption lesions was significantly higher than that of the group without bone-resorption lesions (76.09% vs 30.39%, $P < 0.001$).

Conclusions: This study demonstrated that the bone-resorption lesions are mainly distributed in the lateral and central pillar of the femoral head, and the two pillars of the femoral head are usually involved by bone-resorption lesions. Furthermore, the ratio of ARCO stage III in the group with bone-resorption lesions was significantly higher than that of the group without bone-resorption lesions, suggesting that the bone-resorption lesions might accelerate the progression of ONFH.

Key words: Bone-resorptive lesions; Collapse; Osteonecrosis of the femoral head; Three-dimensional distribution; Three-pillar classification

Address for correspondence Xue-feng Zhou, MD, Strategic Support Force Medical Center, No. 9, Anxiang Beili, Beijing, China 100101 Tel: +86 10 66356253; Email: zhouxuefeng306@sina.com; Jiang Peng, MD, Department of Orthopaedics, The First Medical Center, Chinese PLA General Hospital, No.28, Fuxing Road, Beijing, China 100853 Tel: +86 10 66939202; Email: pengjiang301@126.com

#Co-first author: The first two authors contributed equally to this work and are considered as co-first author.

The work was performed at Strategic Support Force Medical Center

Disclosure: The authors declare that they have no conflicts of interest.

Received 22 December 2020; accepted 10 May 2021

Introduction

Osteonecrosis of the femoral head (ONFH) is characterized by a challenging disease in the orthopaedic field. There are an estimated 8.12 million patients with nontraumatic osteonecrosis in China alone¹. The main causes of nontraumatic ONFH in China are use of corticosteroids, chronic alcohol over-consumption, decompression sickness, haemoglobin diseases, autoimmune diseases, and idiopathic diseases¹. In the progression of the ONFH, collapse of the femoral head is considered to be an important event. After collapse of the femoral head, total hip arthroplasty will be the only solution due to secondary osteoarthritis of the hip joint with severe hip pain and joint dysfunction², so it is essential to elucidate the mechanisms and risk factors of collapse to prevent the occurrence of hip joint destruction. At present, it is common to predict the risk of femoral head collapse based on the location and size of the necrotic area. Nishii's research showed that necrotic lesion volume is strongly correlated with risk of collapse³. Moreover, others studies demonstrated that when the necrotic lesions involved more anterolateral femoral head, collapse will almost be inevitable^{4,5}. Besides the size and location of the necrotic lesion, previous studies have demonstrated that subchondral fracture and collapse are closely related to bone-resorptive lesions, suggesting the importance of bone-resorptive lesions on the collapse progression⁶⁻⁸.

Bone-resorptive lesions are considered a typical sign of stage II ONFH according to the Association for Research on Osseous Circulation (ARCO) staging system, which is characterized by low-density translucent areas of different sizes and locations on computed tomography (CT)^{8,9}. The pathologic characteristics of bone-resorptive lesions, in which trabecular structure was no longer present, are noncavitary and contain loose fibrous elements^{10,11}. By using micro-CT imaging of the femoral head in ARCO stage III from total hip arthroplasty, Hamada *et al.*⁶ and Baba *et al.*⁷ found that the bone resorption area can lead to the initiation of subchondral fracture and accelerate the progress of collapse. In addition, Gao *et al.*⁸ also demonstrated that the femoral head with osteonecrosis complicating by cystic bone-resorptive area is more likely to accompany microfracture and crescent sign, which could hint that the femoral head loses its stability and proceeds to collapse more quickly. So, it is significant to understand the characteristics of the bone-resorptive lesions for successful joint preservation in ONFH.

Much research has suggested that collapse mostly occurs when the necrotic lesion involves the outside of the femoral head¹². Our previous three-dimensional reconstruction studies based on CT data found that the bone-resorption lesions are mainly located on the anterior and lateral sides of the femoral head, destroying the weight-bearing area of the femoral head, which is considered as one of the reasons for its accelerated collapse¹³. However, the previous partitioning method, using three mutually perpendicular planes to segment the femoral head (coronal plane, axial plane, sagittal plane), cannot well reflect the situation that the bone resorption area involves the outside of the femoral head, so a new partitioning method is needed to

study this problem. The three-pillar classification system based on the position of necrotic bone is widely accepted and used in ONFH research^{14,15}. The classification system divides the femoral head into three pillars, in which the medial pillar, central pillar, and lateral pillar represent 30%, 40%, and 30% of the femoral head, respectively¹⁶. According to the involved site of the necrotic lesion, ONFH can be classified as a medial (M) type (only medial pillar involved), central (C) type (medial and central pillars involved), and lateral (L) type (lateral pillar involved). The classification method considers that the lateral pillar of femoral head is considered as a key factor in progression of collapse¹⁷. Therefore, we think it is appropriate to use its three-pillar classification method to explore the distribution of bone-resorptive lesions and the involvement of the femoral head.

The purposes of this study are as follows: (i) to analyze the distribution characteristics bone-resorptive lesions based on the three-pillar classification system; (ii) to study the involvement of the bone-resorptive lesions in different positions of the femoral head in ONFH, and (iii) explore the effect of bone-resorptive lesions on the progression of osteonecrosis of the femoral head.

Methods

Inclusion and Exclusion Criteria

Our institution's research ethics board approved this study. We retrospectively reviewed the information of 171 patients (282 hips) who visited Chinese PLA General Hospital because of ONFH between April 2014 and February 2019. The inclusion criteria for this study were: (i) diagnosis of ONFH based on Guidelines for clinical diagnosis and treatment of osteonecrosis of the femoral head in adults (2019 version);¹ (ii) classification of Association Research Circulation Osseous (ARCO) stage II and stage III; and (iii) complete CT scan data of the hip joint. The exclusion criteria were: (i) a history of hip injury or surgery; (ii) the ONFH hips suffering from osteoarthritis (OA), congenital hip diseases, or other joint diseases; and (iii) ONFH hip suffering primary bone cystic lesion. Of these 282 hips, 14 hips were without CT data, 24 hips had undergone surgical treatment, and 50 hips classified under ARCO stage I or IV were excluded. Ultimately, 117 patients (194 hips) were included in this study.

General Information of Participants

The demographic information of the patient was shown in Table 1. Among the patients, there were 25 females and 92 males with a mean age of 39.85 years (range 17 to 64 years, SD = 10.55). Thirty-two patients had unilateral ONFH, and 85 patients had bilateral ONFH, of which seven bilateral ONFH patients included only one side because the contralateral side was in stage I or stage IV. Of the 194 ONFH hips, 93 hips were at stage II, 101 hips were at stage III, and 104 hips were on the left side, 90 hips were on the right. Among all ONFH hips, 92 hips contained 143 bone-resorption lesions, 54 hips (58.70%) were complicated by

TABLE 1 The baseline characteristics and demographics of the study population

Variable	Outcome
Age (years, mean \pm SD)	39.85 \pm 10.55
Gender (M/F)	92/25
Unilateral / Bilateral ONFH	32/85
Hips with ONFH in 2 and 3 stage	194
ARCO staging	
II (%)	93(47.94)
III (%)	101(52.06)
Side	
Left (%)	104 (53.61)
Right (%)	90 (46.39)
ONFH with bone-resorptive lesions (%)	92(47.42)
ONFH without bone-resorptive lesions (%)	102(52.58)
Number of lesions in per femoral head	
Single lesions (%)	54(58.70)
Multiple lesions (%)	38(41.30)
two	27(29.35)
three	9(9.78)
four	2(2.17)
Etiology	
Corticosteroids (%)	26(23.42)
Alcohol (%)	38(34.23)
Idiopathic (%)	47(42.34)

single lesion, and 38 hips (41.30%) were complicated by multiple lesions. The incidence of bone-resorption lesions in ONFH was 47.42% (92/194). The factors associated with ONFH were corticosteroid usage in 26 hips, alcohol abuse in 38 hips, and idiopathic in 47 hips.

Three-Dimensional Reconstruction of the Femur, and Bone-Resorptive Lesions

All patients underwent CT images, which the scans had a slice thickness of ≤ 1 mm, a slice increment of ≤ 0.6 mm, and a pixel size of ≤ 0.8 mm. The three-dimensional structure of the femoral head and bone-resorption lesions were obtained based on the previous method¹³. Briefly, raw hip CT data were obtained in the axial plane and imported to the Mimics software (version 21.0, Materialise, Leuven, Belgium). First, based on CT values, a rough femoral head construction was acquired. Then, the structural details of the femoral head were refined by tracing the outline of the femoral head manually at each level. Bone-resorptive lesions were also segmented manually, which was estimated by defining it as the area in which the trabecular structure was no longer present. Finally, three-dimensional structures of femoral head and bone-resorptive lesions was created. To obtain an optimally homogeneous and anatomically faithful three-dimensional structure, the resulting objects were smoothed in Mimics as well (Fig. 1).

Three-Dimensional Segmentation of Femoral Head

To determine the distribution of bone-resorptive lesions on the femoral head based on the three-pillar classification system, we divided the femoral head into three regions through two mutually parallel planes. All operations are done in

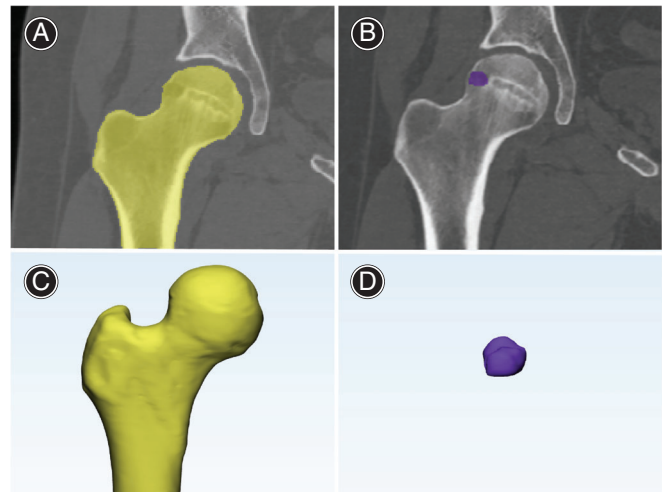


Fig. 1 Three-dimensional reconstruction of the femur, and bone-resorptive lesions. (A, B) The region of femoral head and bone-resorption lesions is obtained by software's' semiautomatic tools and manual addition and subtraction. The yellow area is the femoral head area at a certain level (A), The purple area is a bone-resorptive lesion at a certain level (B); (C, D) Objects are reconstructed in three dimensions and smoothed. (C) femoral head, (D) bone-resorptive lesions.

3-matic software (version 13.0, Materialise, Leuven, Belgium). The specific steps were as follows: (i) initially, the reference plane was obtained, which included the center of the femoral head, the center of femoral head fovea and the center of the femoral neck (Fig. 2); (ii) connect the center of femoral head and the center of femoral neck, then define it as the axis line of the femoral head and the femoral neck; (iii) on the established reference plane, make the vertical line of the above axis line through the center of the femoral head as the diameter line of the femoral head; (iv) divide the diameter line of the femoral head into three parts with a length ratio of 30%, 40% and 30%; (v) cross the two length division points of the femoral heads' diameter line to make two planes which is perpendicular to the femoral diameter line, and use these two planes to divide the femoral head into lateral (L), central (C), and medial (M) pillars; (vi) in order to make the segmentation more detailed to provide more valuable position information, we also use the reference plane to divide the femoral head into two parts: front and back (Fig. 3); finally (vii) we divide the femoral head into six areas (I–VI) using the above three planes (Fig. 4).

Observation Indicators

Three-Dimensional Distribution Characteristics of Bone-Resorptive Lesions

To study three-dimensional distribution characteristics of bone-resorptive lesions, the femoral head was divided into six regions. Because a bone-resorptive lesion might be distributed across multiple regions at the same time, we defined

the region containing the largest volume of bone-resorptive lesion as its distribution area. By analyzing the characteristics of its location, we hoped to provide clues to the formation mechanism of bone-resorptive lesions and its role in ONFH.

The Involvement of the Bone-Resorption Lesions in the Femoral Head

The bone structure in the bone-resorption lesions disappeared, and it appeared as a low-density and translucent area on CT. After segmentation of the femoral head, we also count the involvement of the bone-resorption lesions on the lateral, central, and medial pillars in the femoral head, and aim to analyze its effect on the ONFH based on statistical results.

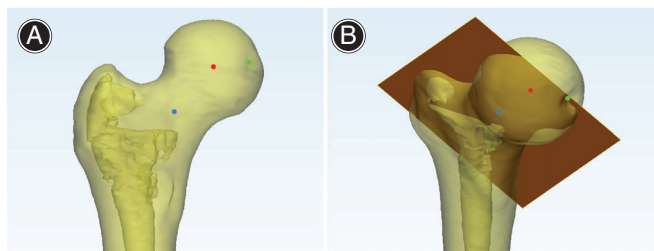


Fig. 2 The determination of the reference plane. (A) The green point, red point, and blue point indicate the positions of the center of femoral head fovea, the center of the femoral head and the center of the femoral neck. (B) The reference plane (red plane) was obtained, which included the center of femoral head fovea, the center of the femoral head and the center of the femoral neck.

Assessment of Bone-Resorptive Lesions Association with Disease Progression

Based on the electronic medical record and follow-up, we collected the demographic information of the patient including age, sex, BMI, etiology. Then on the basis of CT data, the side of the hips, the number of bone-resorptive lesions and the ARCO stage are determined. ONFH hips with subchondral fractures and collapse were classified as ARCO stage III, while the hips without collapse that osteosclerosis, focal osteoporosis were seen are classified as stage II. To explore the bone-resorptive lesions' influence on progression of collapse, we made a comparison for the ratio of stage II and stage III between the ONFH group with bone-resorptive lesions and the ONFH group without bone-resorptive lesions.

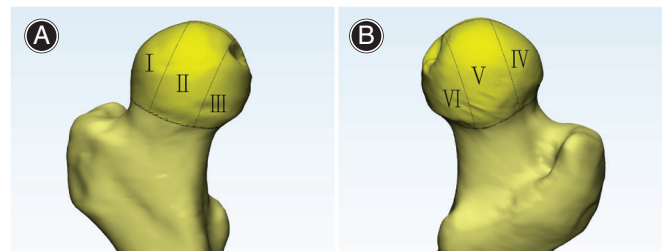


Fig. 4 The femoral head are divided into six regions (I–VI) by three planes. (A) I–III represents lateral, central and medial pillars in the anterior side of femoral head respectively. (B) IV–VI represents lateral, central and medial pillars in the posterior side of the femoral head respectively.

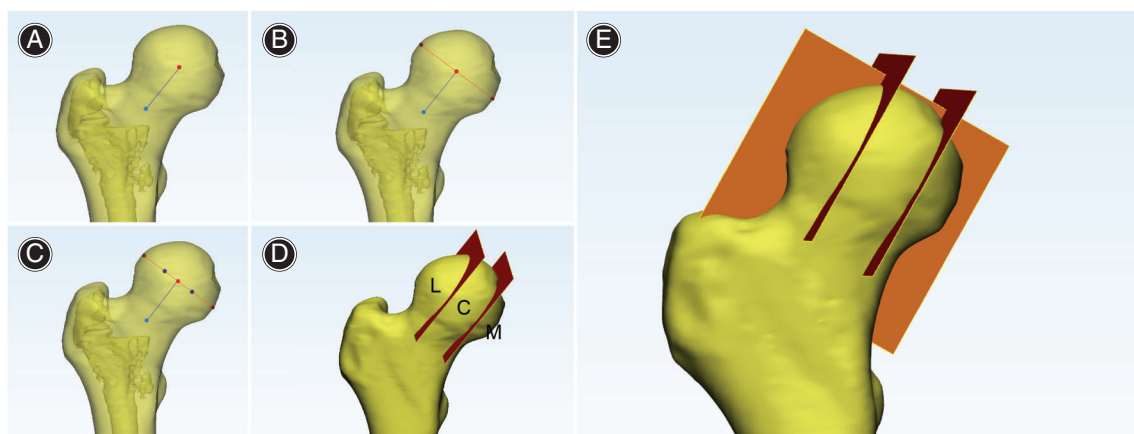
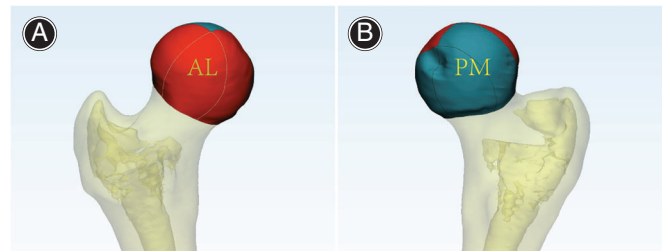


Fig. 3 Determination of three segmentation planes. (A) Connect the center of femoral head (red point) and the center of femoral neck (blue point) as the axis line of the femoral head and the femoral neck (blue line). (B) On reference plane, make the vertical line of the axis line through the center of the femoral head as the diameter line of the femoral head (red line). (C) Determine two segmentation reference points (deep blue points), which could divide the diameter line into three parts of 30%: 40%: 30%. (D) Cross the two segmentation points to make two planes which is perpendicular to the femoral diameter line (red plane), and use these two planes to divide the femoral head into lateral (L), central (C), and medial (M) pillars. (E) Using reference plane (orange plane), the femoral head is divided into anterior and posterior parts.

TABLE 2 The distribution of bone-resorptive lesions in regions I-VI in ONFH

Location	Outcome	
	Number	Percentage
I	39	27.27
II	55	38.46
III	6	4.20
IV	23	16.08
V	17	11.89
VI	3	2.10
Total	143	100.00

**Fig. 5** To make the distribution characteristics more obvious, the six areas are redivided into two areas: anterolateral pillar, zone AL (I + II + IV) and posteromedial pillar, zone PM (III + V + VI). (A) The locations of zone AL (I + II + IV)(B)The locations of zone PM (III + V + VI).**TABLE 3** The distribution of bone-resorptive lesions based three-pillar classification

Location	Outcome	
	Number	Percentage
L	64	44.76
C	70	48.95
M	9	6.29
Total	143	100.00

C, central pillar; L, lateral pillar; M, medial pillar.

TABLE 4 The involvement of the three pillars in the femoral head

Area	Number (%)
L	8 (8.70)
C	5 (5.43)
M	0 (0.00)
L + C	50 (54.35)
C + M	6 (6.52)
L + C + M	23 (25.00)
Total	92 (100.00)

C, central pillar; L, lateral pillar; M, medial pillar.

Statistical Analysis

SPSS version 13.0 (SPSS Inc., USA) was used for the analyses. Quantitative variables were expressed as mean \pm standard deviation, and qualitative variables as percentage. The chi-square test or Fisher exact test probability was used for categorical variables, including sex, factors associated with ONFH, and stage. The *t* test was used for continuous variables, including age and BMI. For statistical analysis, $P < 0.05$ was considered to be significant.

Results

Three-Dimensional Distribution Characteristics of Bone-Resorptive Lesions

Three-dimensional structures of each bone-resorption lesion and femoral head were reconstructed, which was shown in Supplementary 1. The distribution of bone-resorption lesions in the six regions is shown in Table 2. The location of bone-resorption lesions on the hip revealed that there were 39 bone-resorption lesions in region I (27.27%), 55 in II (38.46%), six in III (4.20%), 23 in IV (16.08%), 17 in V (11.89%), and three lesions in region in VI (2.10%), indicating that zone II is the region with the largest distribution. Based on the three-pillar classification system, zone I plus IV represent the lateral pillar, II plus V represent the central pillar, and zones III and VI represent the medial pillar. As shown in

Table 3, Sixty-four (44.76%) bone-resorption lesions were located on the lateral pillar, 70 (48.95%) bone-resorption lesions were located on the central pillar, and nine (6.29%) bone-resorption lesions on the medial pillar.

As can be seen, the adjacent zones I, II and IV contained a relatively higher number of lesions than the other zones did. To make the trend more obvious, we defined zone I, zone II, and zone IV as anterolateral pillar, AL (I + II + IV) and zone III, zone V, and zone VI as posteromedial pillar, PM (III + V + VI) (Fig. 5). The partitioning method showed distribution as follows: there were 69 (48.25%) bone-resorption lesions in zone AL totally, three (2.10%) in PM totally, and 71(49.65%) in both AL and PM (33.57%: AL > PM, 16.08%: AL < PM). If we defined the region containing the largest volume as its distribution area, then 81.82% of the bone-resorption lesions was located on the anterolateral pillar, and 18.18% on the posteromedial pillar. Thus, the anterolateral pillar and central pillar were the main distribution areas of bone-resorption lesions in hips with ONFH in the research.

Involvement of the Bone-Resorption Lesions in the Femoral Head

As shown in Table 4, in eight (8.70%) femoral heads, only the lateral pillar was affected by the bone-resorption lesions

TABLE 5 The comparison of hips' characteristics between ONFH with bone-resorptive lesions and without bone-resorptive lesions

	ONFH with bone-resorptive lesions	ONFH without bone-resorptive lesions	P value
Age (mean ± SD, years)	39.53 ± 10.84 (n = 92)	40.40 ± 9.75 (n=102)	0.557
BMI (mean ± SD, kg/m ²)	25.44 ± 4.11 (n = 87)	25.06 ± 4.32 (n = 98)	0.236
Sex			0.371
Male	76	79	
Female	16	23	
Side			0.054
Left	56	48	
Right	36	54	
Etiology			0.675
Corticosteroids	17	24	
Alcohol	31	35	
Idiopathic	39	39	
ARCO staging			0.000
I	22	71	
III	70	31	

ARCO, Association Research Circulation Osseous.

and in five (5.43%) femoral heads, only the central pillar was affected. No medial pillar was affected alone. In 50 (54.35%) femoral heads, the lateral pillar and the central pillar were simultaneously affected, and in six (6.52%) femoral heads, the central pillar and the medial pillar were simultaneously affected. In addition, there were 23 (25.00%) femoral heads whose lateral, central and medial pillars were all complicated by bone-resorption lesions. Therefore, in all ONFH hips, the lateral pillar of 81 (88.04%) femoral heads were affected, the central pillar of 84 (91.30%) femoral heads were affected, and the medial pillar of 29 (31.52%) femoral heads were affected. It is worth noting that there were no femoral heads with only the medial pillar affected.

Role of Bone-Resorption Lesions in the Disease Progression of ONFH

This research divided the ONFH hips into two groups based on whether it contained bone-resorption lesions: group with bone-resorptive lesions and group without bone-resorptive lesions. Between the two groups, the difference was not significant in age, BMI, sex, side, and factors associated with ONFH. With respect to the ARCO stage, the ratio of ARCO stage III in the group with bone-resorption lesions (70/92, 76.09%) was significantly higher than that of the group without bone-resorption lesions (31/102, 30.39%, $P < 0.001$). Thus, the results suggested that the bone-resorption lesions were associated with disease progression of ONFH (Table 5).

Discussion

To the best of our knowledge, this is the first study to investigate the distribution of bone-resorption lesions in ONFH on the three-dimensional level based on the three-pillar classification. Based on our research, we found that 44.76% of bone-resorption lesions was distributed in the

lateral pillar of the femoral head, 48.95% was distributed in the central pillar, and only 6.29% was distributed in the medial pillar. Moreover, if we define the most distributed adjacent areas I, II, and IV as the anterolateral pillar, then 81.82% of the bone-resorption lesions was located on the anterolateral pillar of the femoral head. In addition, among all femoral heads with bone-resorption lesions, 88.04% of the lateral pillar are affected, which is vital to the mechanical stability of the femoral head. At the same time, it is found that the proportion of ARCO stage III in hips with bone-resorption lesions is significantly higher than that of hips without bone-resorption lesions (76.09% vs 30.39%, $P < 0.001$), suggesting that bone-resorption lesions are closely association with the progression of ONFH.

Although the mechanism of collapse has not been fully elucidated, active joint-preserving treatments could often achieve better results in early stages of ONFH¹⁸. Many previous studies have suggested that the bone-resorption lesions were closely related to the progress of collapse. An animal study showed that the cystoid bone cavity formed by bone resorption was an important reason for the loss of structural integrity and deformity of the femoral head¹⁹. At the same time, some scholars performed micro-CT scans on the femoral head specimens in the early stage of collapse, and found that subchondral fractures, microfractures, and collapse are closely related to the bone-resorption lesions^{6,7}. Furthermore, our study also suggests that the bone-resorption lesions might accelerate the progression of ONFH. So, we believe that this study can help better understand the characteristics of the bone-resorption lesions and provide a theoretical basis for the prevention and treatment of femoral head's collapse.

To obtain the three-dimensional location information of the bone-resorption lesions, Baba *et al.*⁷ investigated 35 entire femoral heads resected from 35 patients

with ONFH. By analyzing the area of the bone-resorption lesions at different levels, a high percentage of bone-resorptive cross-sectional areas tended to be seen in the anterior femoral head, suggesting bone-resorptive lesions were more common in the anterior portion of the femoral head. Previous studies used the coronal, sagittal, and axial planes to divide the femoral head into eight regions¹³. However, this zoning method focused on mechanical geometrical division and cannot fit the commonly used clinical classifications (e.g., Japanese Investigation Committee, JIC) to better fit and serve clinical practice. Based on Herrington's three-pillar concept of Legg-Calvé-Perthes disease, three-pillar classification system of ONFH divides the femoral head into medial, central and lateral pillars²⁰. It is believed that preservation of the lateral pillar is the keystone for forestalling the collapse of the femoral head. According to reports, 95.3% of the femoral head collapsed within 0.5–3 years when the lateral pillar was involved²⁰. Therefore, we believe the distribution of bone-resorption lesions based on three-pillar classification can help us understand the role of bone-resorption lesions in the progression of ONFH.

Much research have shown the occurrence of collapse might become inevitable when the lateral boundary of the necrotic lesion is involved¹². This study shows that 44.76% of the bone-resorption lesions is located on the lateral pillar of the femoral head and further exploration suggests 81.82% of the bone-resorption lesions located on the anterolateral pillar. In addition, for the femoral head containing bone-resorption lesions, 88.04% of lateral pillars are affected. Therefore, in terms of the location characteristics, it is reasonable to assume that the bone-resorption lesions could accelerates collapse by reducing the weight-bearing capacity of the femoral head. Through comparison of this study, it was also found that the ratio of ARCO stage III is significant higher in the hips containing bone-resorption lesions. In addition, the central pillar of the femoral head is also an area of high incidence of bone-resorption lesions. The disappearance of the trabecular bone in the central pillar might destroy the stress transfer path of the hip^{8,21}. Thus, the stress transfer efficiency of principal compressive trabeculae was impaired, contributing to damaging the bearing ability. Furthermore, the results of the finite element study show that the bone-resorption lesions could lead to the formation of a stress concentration area around it and increase the stress in the necrotic area, which could increase the risk of collapse^{22,23}. Previous reports have also shown that the bone-resorption lesions are mainly located near the sclerosis rim, destroying its protective effect on the necrotic area^{8,13}. All of above elements might contribute to the occurrence of collapse in ONFH.

Although there is no clear research evidence, based on previous literature reports, it is believed that the formation of bone-resorption lesions is closely associated with osteoclasts. Wang *et al.*²⁴ found that the number and activity of osteoclasts in the necrotic area were significantly higher than those in the normal area by analyzing the specimens

obtained from patients undergoing total hip arthroplasty. Bisphosphonates, which serve as osteoclast inhibitors, are usually used to explore the role of osteoclasts in the collapse of ONFH. In animal model experiments, after local administration of bisphosphonates, the number of osteoclast and the bone resorption area was significantly reduced compared with the control group¹⁹. In addition, a bone chamber study in rats also confirmed that systemic alendronate could prevent resorption of necrotic bone, indicating the close connection between osteoclasts and bone-resorption lesions²⁵. Based on previous studies, the bone-resorption lesions were mainly located at the junction of the necrotic zone and the normal zone¹³. Li *et al.*²⁶ observed the distribution of tartrate resistant acid phosphatase (TRAP)-positive cells in 51 hips and found that TRAP-positive cells were detected in the early radiologic stage and were detected increasingly through the reparative interface zone in accordance with progression of the radiologic stage. Therefore, we speculate that near the reaction interface in the anterolateral area of the femoral head considered as a stress concentration area^{27,28}, microfractures of trabecular bone occur under excessive stress in the early stage of ONFH. Subsequently, the number of osteoclasts increases and the bone resorption is active. Part of the necrotic bone is absorbed by osteoclasts and replaced by fibrous tissue, so the CT imaging shows a change in the bone resorption area.

Although some studies have reported that bisphosphonates could significantly reduce the incidence of collapse in ONFH^{29,30}, comprehensive treatment should be adopted for characteristics of the femoral head complicated by bone-resorption lesions. Considering that the bone-resorption lesions are mainly located in the weight-bearing area, cleaning up lesions and filling the cavity is very important to prevent joint surface collapse. Besides, ONFH is a disease with impaired blood supply, and it might be difficult for drugs to reach the necrotic lesion. So, local administration of bisphosphonates might be an effective way to inhibit its formation and prevent collapse.

There were some limitations of this study. Confined to resolution of clinical CT, when the volume of the bone-absorption lesions is very small, it is difficult to identify its distribution and characteristics. However, it is impossible to perform micro-CT of femoral head in the early stage and the smallest bone-resorption lesions in this study is only 32 mm³. So, we believe the analysis could still provide useful information on the distribution of bone-absorption lesions, especially in the early stage. Moreover, we only conducted a simple cross-sectional investigation to explore the effect of bone-resorption lesions on ONFH. The clinical research with higher level of evidence should be performed in the future.

Conclusion

This study demonstrated that the bone-resorption lesions are mainly distributed in the lateral and central pillar of the femoral head, and the two pillars of the femoral head are usually involved by bone-resorption lesions. Furthermore, the ratio of ARCO stage III in the group with bone-resorption lesions was significantly higher than that of the

group without bone-resorption lesions, suggesting that the bone-resorption lesions might accelerate the progression of ONFH.

Declarations

Three-dimensional reconstruction images of the bone-resorptive lesions and femoral head are available in supplementary materials.

Acknowledgements

This study was supported by the National Natural Science Foundation of China (grant number: 81972047).

Compliance with ethical standards

This article was approved by the Medical Ethics Committee of Chinese PLA General Hospital(S2020-317-01).

Supporting Information

Additional Supporting Information may be found in the online version of this article on the publisher's web-site:

Supplementary 1 The three-dimensional images of the bone resorption lesions and femoral heads of 92 ONFH hips. The bone resorption lesions are marked in purple to show its distribution characteristics based on the three-pillar classification in the femoral head.

References

- Zhao D, Zhang F, Wang B, *et al.* Guidelines for clinical diagnosis and treatment of osteonecrosis of the femoral head in adults (2019 version). *J Orthop Translat.* 2020, 21: 100–110.
- Sodhi N, Acuna A, Etcheson J, *et al.* Management of osteonecrosis of the femoral head. *Bone Joint J*, 2020, 102: 122–128.
- Nishii T, Sugano N, Ohzono K, Sakai T, Sato Y, Yoshikawa H. Significance of lesion size and location in the prediction of collapse of osteonecrosis of the femoral head: a new three-dimensional quantification using magnetic resonance imaging. *J Orthop Res*, 2002, 20: 130–136.
- Sugano N, Atsumi T, Ohzono K, Kubo T, Hotokebuchi T, Takaoka K. The 2001 revised criteria for diagnosis, classification, and staging of idiopathic osteonecrosis of the femoral head. *J Orthop Sci*, 2002, 7: 601–605.
- Kubo Y, Motomura G, Ikemura S, *et al.* The effect of the anterior boundary of necrotic tissue on the occurrence of collapse in osteonecrosis of the femoral head. *Int Orthop*, 2018, 42: 1449–1455.
- Hamada H, Takao M, Sakai T, Sugano N. Subchondral fracture begins from the bone resorption area in osteonecrosis of the femoral head: a micro-computerised tomography study. *Int Orthop*, 2018, 42: 1479–1484.
- Baba S, Motomura G, Ikemura S, *et al.* Quantitative evaluation of bone-resorptive lesion volume in osteonecrosis of the femoral head using micro-computed tomography. *Joint Bone Spine*, 2020, 87: 75–80.
- Gao F, Han J, He Z, Li Z. Radiological analysis of cystic lesion in osteonecrosis of the femoral head. *Int Orthop*, 2018, 42: 1615–1621.
- Murphey MD, Foreman KL, Klassen-Fischer MK, Fox MG, Chung EM, Kransdorf MJ. From the radiologic pathology archives imaging of osteonecrosis: radiologic-pathologic correlation. *Radiographics*, 2014, 34: 1003–1028.
- Resnick D, Niwayama G, Coultts RD. Subchondral cysts (geodes) in arthritic disorders: pathologic and radiographic appearance of the hip joint. *AJR Am J Roentgenol*, 1977, 128: 799–806.
- McCollum DE, Mathews RS, O'Neil MT. Aseptic necrosis of the femoral head: associated diseases and evaluation of treatment. *South Med J*, 1970, 63: 241–253.
- Chen L, Hong G, Fang B, *et al.* Predicting the collapse of the femoral head due to osteonecrosis: from basic methods to application prospects. *J Orthop Translat*, 2017, 11: 62–72.
- Liu GB, Li R, Lu Q, *et al.* Three-dimensional distribution of cystic lesions in osteonecrosis of the femoral head. *J Orthop Translat*, 2020, 22: 109–115.
- Rajan R, Chandrasenan J, Price K, Konstantoulakis C, Metcalfe J, Jones S. Legg-Calvé-Perthes: interobserver and intraobserver reliability of the modified Herring lateral pillar classification. *J Pediatr Orthop*, 2013, 33: 120–123.
- Herring JA, Neustadt JB, Williams JJ, Early JS, Browne RH. The lateral pillar classification of Legg-Calvé-Perthes disease. *J Pediatr Orthop*, 1992, 12: 143–150.
- Zhang QY, Li ZR, Gao FQ, Sun W. Pericollapse stage of osteonecrosis of the femoral head: a last chance for joint preservation. *Chin Med J (Engl)*, 2018, 131: 2589–2598.
- Wen PF, Guo WS, Zhang QD, *et al.* Significance of lateral pillar in osteonecrosis of femoral head: a finite element analysis. *Chin Med J (Engl)*, 2017, 130: 2569–2574.
- Larson E, Jones LC, Goodman SB, Koo KH, Cui Q. Early-stage osteonecrosis of the femoral head: where are we and where are we going in year 2018?. *Int Orthop*, 2018, 42: 1723–1728.
- Kim HK, Aruwajoye O, Du J, Kamiya N. Local administration of bone morphogenetic protein-2 and bisphosphonate during non-weight-bearing treatment of ischemic osteonecrosis of the femoral head: an experimental investigation in immature pigs. *J Bone Joint Surg Am*, 2014, 96: 1515–1524.
- Sun W, Li ZR, Wang BL, Liu BL, Zhang QD, Guo WS. Relationship between preservation of the lateral pillar and collapse of the femoral head in patients with osteonecrosis. *Orthopedics*, 2014, 37: e24–e28.
- Zhang Y, Tian K, Ma X, *et al.* Analysis of damage in relation to different classifications of pre-collapse osteonecrosis of the femoral head. *J Int Med Res*, 2018, 46: 693–698.
- McErlain DD, Milner JS, Ivanov TG, Jencikova-Celerin L, Pollmann SI, Holdsworth DW. Subchondral cysts create increased intra-osseous stress in early knee OA: a finite element analysis using simulated lesions. *Bone*, 2011, 48: 639–646.
- Liu G, Mei Y, Ma H, *et al.* Effects of bone-resorptive lesion on stress distribution of the femoral head and on progression in patients with osteonecrosis of the femoral head. *Chin J Orthop*, 2020, 7: 408–416.
- Wang C, Meng H, Wang Y, *et al.* Analysis of early stage osteonecrosis of the human femoral head and the mechanism of femoral head collapse. *Int J Biol Sci*, 2018, 14: 156–164.
- Astrand J, Aspenberg P. Systemic alendronate prevents resorption of necrotic bone during revascularization. A bone chamber study in rats. *BMC Musculoskelet Disord*, 2002, 3: 19.
- Li W, Sakai T, Nishii T, *et al.* Distribution of TRAP-positive cells and expression of HIF-1 α , VEGF, and FGF-2 in the reparative reaction in patients with osteonecrosis of the femoral head. *J Orthop Res*, 2009, 27: 694–700.
- Michaeli DA, Murphy SB, Hipp JA. Comparison of predicted and measured contact pressures in normal and dysplastic hips. *Med Eng Phys*, 1997, 19: 180–186.
- Utsunomiya T, Motomura G, Ikemura S, *et al.* Effects of sclerotic changes on stress concentration in early-stage osteonecrosis: a patient-specific, 3D finite element analysis. *J Orthop Res*, 2018, 36: 3169–3177.
- Lai KA, Shen WJ, Yang CY, Shao CJ, Hsu JT, Lin RM. The use of alendronate to prevent early collapse of the femoral head in patients with nontraumatic osteonecrosis. A randomized clinical study. *J Bone Joint Surg Am*, 2005, 87: 2155–2159.
- Agarwala S, Jain D, Joshi VR, Sule A. Efficacy of alendronate, a bisphosphonate, in the treatment of AVN of the hip. A prospective open-label study. *Rheumatology (Oxford)*, 2005, 44: 352–359.