

IMAGE OF THE MONTH

## 스테로이드 치료에 좋은 조기 반응을 보였던 Cronkhite-Canada 증후군

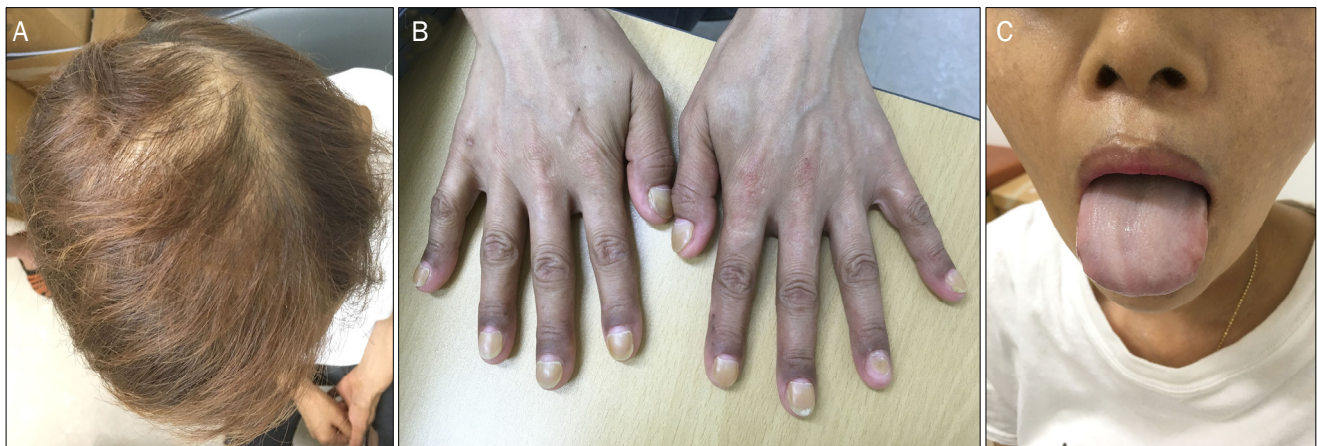조우희, 남광우, 방기배, 신현덕, 신정은  
단국대학교 의과대학 내과학교실

### Cronkhite-Canada Syndrome Showing Good Early Response to Steroid Treatment

Woohee Cho, Kwangwoo Nam, Ki Bae Bang, Hyun Deok Shin and Jeong Eun Shin  
Department of Internal Medicine, Dankook University College of Medicine, Cheonan, Korea

**Case:** A 43-year-old female visited our hospital with complaints of abdominal pain and diarrhea. The patient had diffuse postprandial abdominal pain, dyspepsia, loss of taste, and repeated watery diarrhea for a duration of one month. She was in poor general condition and unable to consume regular diet. During that period, she gradually experienced

hair loss, nail dystrophy of both hands and feet, and skin hyperpigmentation of both upper and lower limbs (Fig. 1). She had no remarkable previous medical, surgical, and family history; she underwent screening esophagogastroduodenoscopy seven months ago, which revealed mild gastritis, and had no history of colonoscopy. She was a non-smoker and



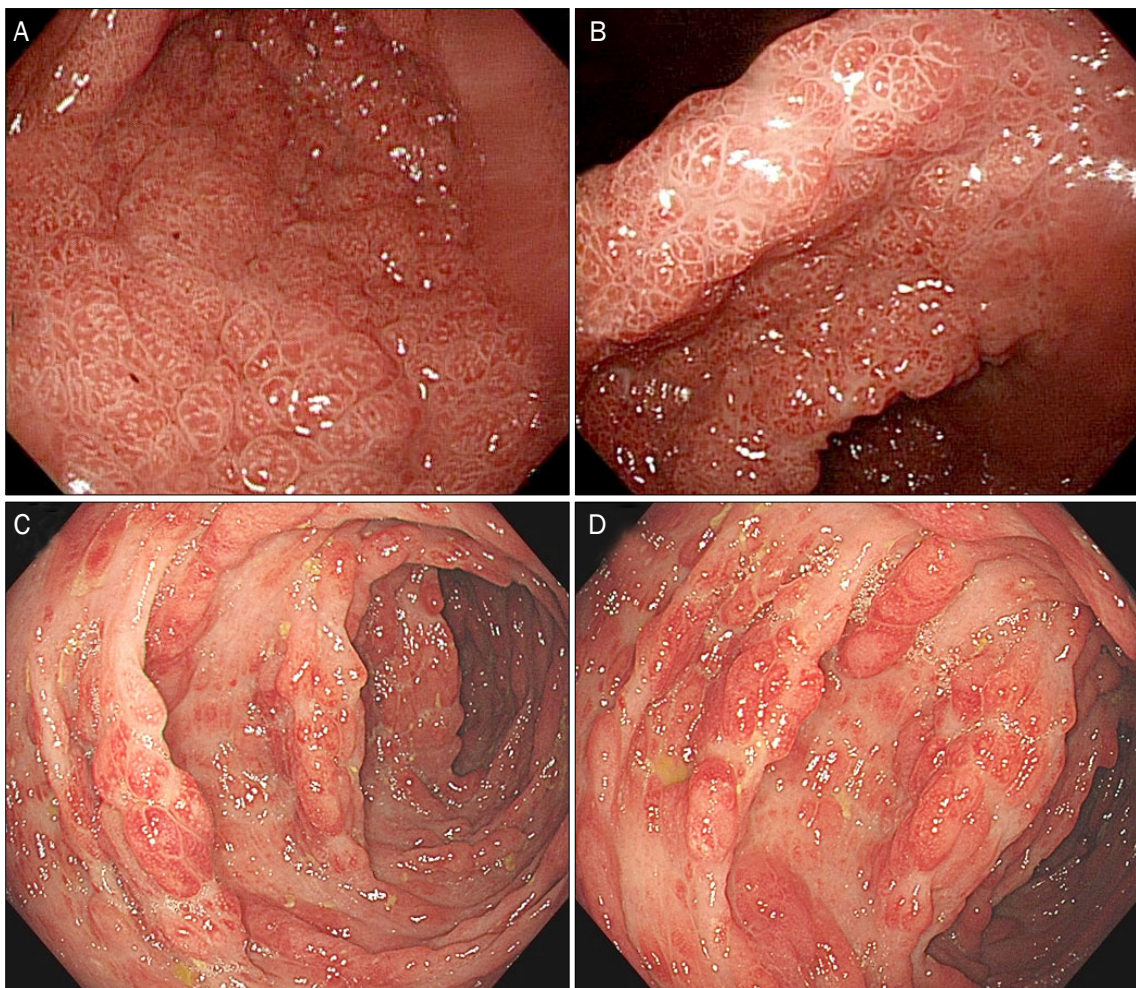
**Fig. 1.** Clinical manifestation of the patient at the initial presentation. (A) Hair loss. (B) Skin pigmentation and nail dystrophy. (C) Tongue swelling and mucosal atrophy.

© This is an open access article distributed under the terms of the Creative Commons Attribution Non-Commercial License (<http://creativecommons.org/licenses/by-nc/4.0>) which permits unrestricted non-commercial use, distribution, and reproduction in any medium, provided the original work is properly cited.  
Copyright © 2018. Korean Society of Gastroenterology.

교신저자: 남광우, 31116, 천안시 동남구 망향로 201, 단국대학교병원 내과

Correspondence to: Kwangwoo Nam, Department of Internal Medicine, Dankook University Hospital, 201 Manghyang-ro, Dongnam-gu, Cheonan 31116, Korea.  
Tel: +82-41-550-7630, Fax: +82-41-550-7050, E-mail: nambag1108@gmail.com

Financial support: None. Conflict of interest: None.



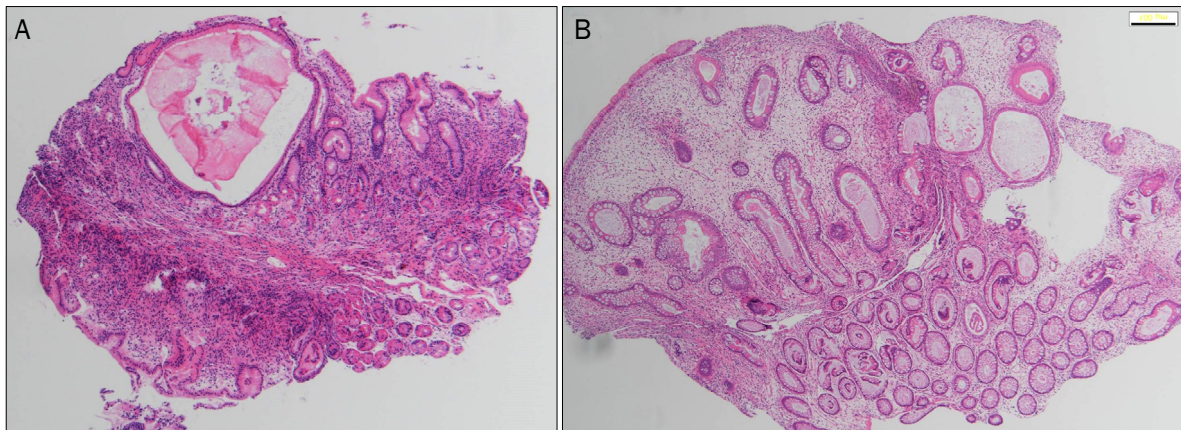
**Fig. 2.** Initial upper and lower endoscopic findings. Numerous variable-sized sessile polyps with mucosal edema and hyperemia were observed in the (A, B) stomach, and (C, D) colon.

non-drinker. She had been running her own restaurant business for the past year and had been under a lot of stress.

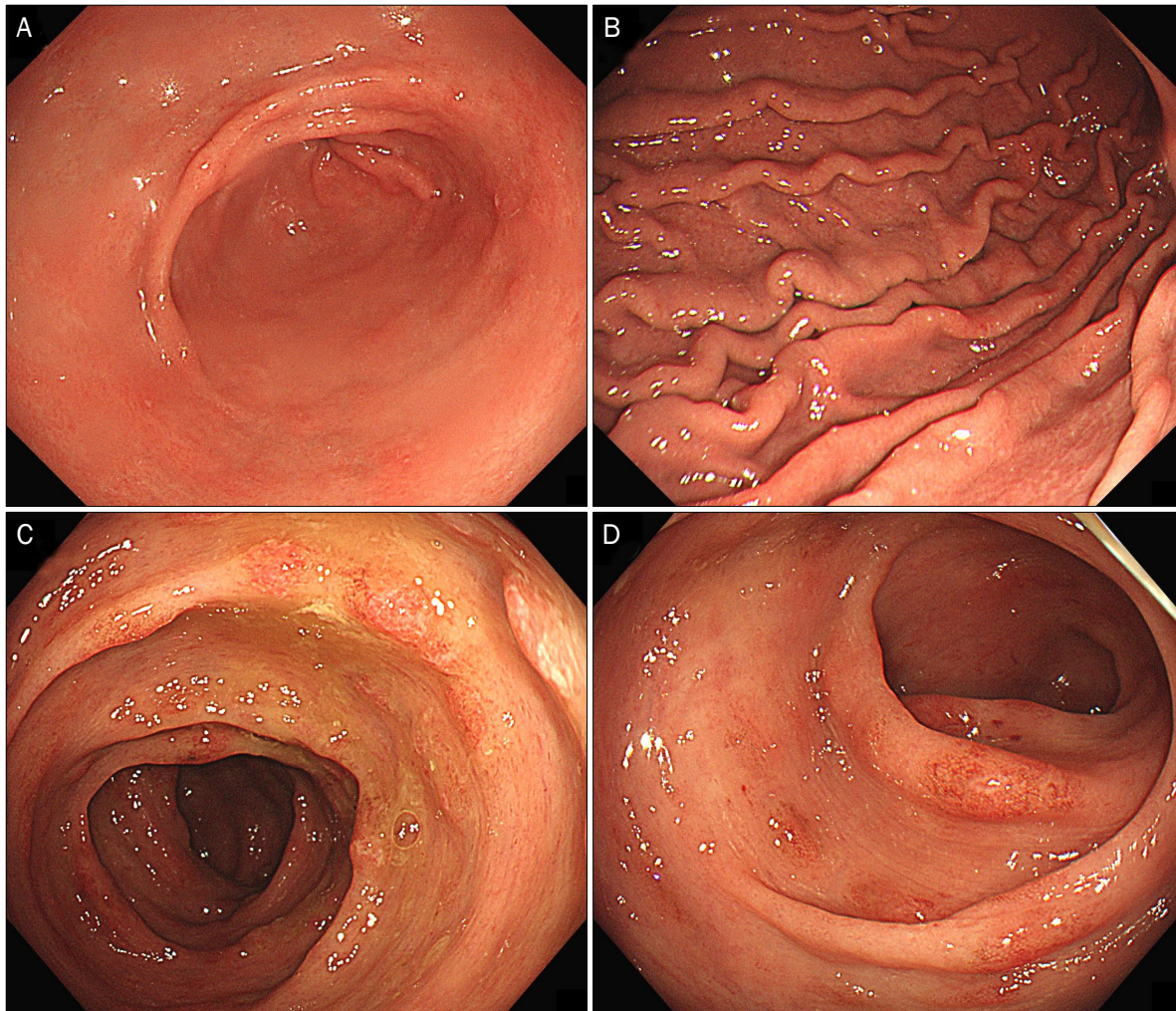
The initial vital signs were stable; she appeared chronically ill. Her height was 147 cm and weight was 42 kg (body mass index, 19.4 kg/m<sup>2</sup>). The initial laboratory data were as follows: white blood cell count 8,620/μL, hemoglobin 14.7 g/dL, platelet count 308,000/μL, protein 5.8 g/dL, albumin 3.8 g/dL, blood urea nitrogen 7.1 mg/dL, creatinine 0.57 mg/dL, and C-reactive protein 0.16 mg/dL. Serum antinuclear antibody and immunoglobulin G4 (IgG4) were absent. Carcinoembryonic antigen and cancer antigen 19-9 were within normal range. Upper and lower endoscopy were performed, which revealed numerous sessile polyps with mucosal edema and hyperemia involving the stomach, duodenum, and colon, except the esophagus (Fig. 2). The size of polyps was variable; however, there was no polyp with large enough size that required

endoscopic resection. Forceps biopsies revealed hyperplastic polyps in the stomach and juvenile polyps in colon, accompanied by inflammatory cell infiltration with dilated gland, cystic dilatation of crypt, and edema of lamina propria (Fig. 3). Tissue IgG4 staining result was negative. Rapid urease test result was positive. Abdomino-pelvic computed tomography and small bowel series showed no significant polyp-like lesion in the jejunum and ileum.

Based on these findings, the patient was finally diagnosed with Cronkhite-Canada syndrome (CCS), and admission for steroid treatment with nutritional support was recommended. However, the patient wanted ambulatory treatment for personal reasons. Thus, an oral corticosteroid (prednisolone, 40 mg per day) was administered in an outpatient setting. After 3 weeks, she regained appetite, sense of well-being, and formed stool, with improvement of skin hyperpigmentation



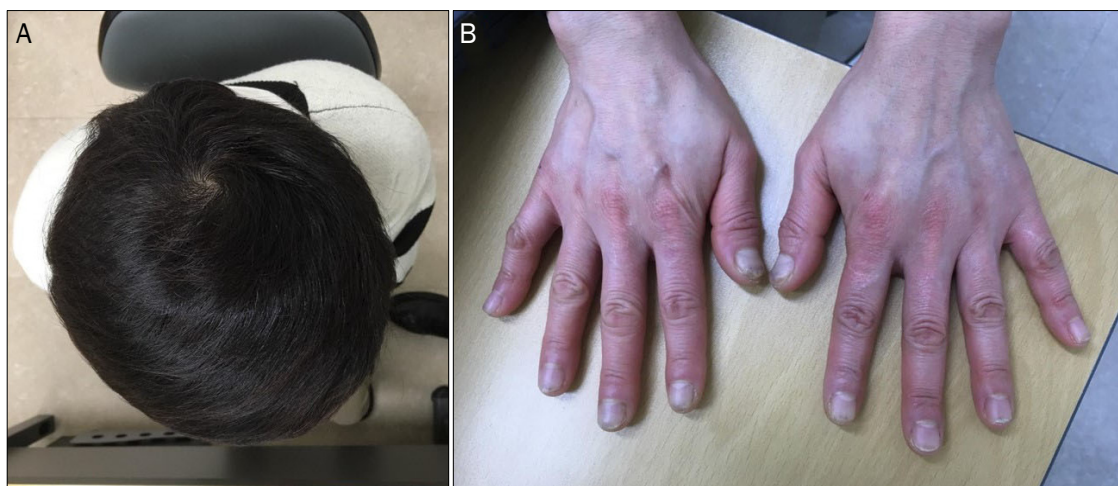**Fig. 3.** Histologic findings. (A) Dilatation of gland, and inflammatory cell infiltration in gastric mucosa (H&E, ×40). (B) Dilatation of gland, cystic dilatation of crypt, and edema of lamina propria in colonic mucosa (H&E, ×40).



**Fig. 4.** Follow-up upper and lower endoscopic findings. Marked regression of polyposis was observed in the (A, B) stomach, and (C, D) colon.

and tongue swelling; however, her hair loss continued. Considering the favorable treatment response, steroid dose was gradually tapered by 5 mg per week. Diarrhea improved

after 6 weeks. Follow-up upper endoscopy and colonoscopy after 3 months from the initial diagnosis showed marked regression of gastrointestinal polyposis with remaining mild



**Fig. 5.** Clinical improvement of the patient at 5 months after steroid administration. Recovery from (A) hair loss and (B) skin pigmentation and nail dystrophy.

mucosal edema and hyperemia (Fig. 4). Forceps biopsies revealed nonspecific inflammation. Hair loss, skin pigmentation, and nail dystrophy improved at 5 months after the start of steroid treatment (Fig. 5). Steroid dose was successfully tapered, and eradication of the *Helicobacter pylori* was performed. The patient remained stable without recurrence during the 9-month follow-up period from the initial diagnosis.

#### Diagnosis: Cronkhite-Canada syndrome (CCS)

CCS is a rare non-hereditary disorder characterized by 1) gastrointestinal polyposis and 2) characteristic ectodermal changes (hair, skin, nail, and tongue). Since the first report of two patients by Cronkhite and Canada,<sup>1</sup> more than 400 cases have been reported worldwide, and the majority of them were in Japan.<sup>2,3</sup> Until now, 15 cases of CCS have been reported in Korea.<sup>4,5</sup> According to previous reports, the mean age of patients at the time of diagnosis was between late 50s and early 60s, with greater occurrence in males (male to female ratio was 1.3-1.84:1).<sup>2,6</sup> Pathophysiology of CCS is still unclear, but some authors have suggested mental stress and physical fatigue as possible precipitating factors. Common complications are malnutrition, gastrointestinal bleeding, and infection. The overall prognosis is poor, and the mortality rate is reported to be as high as 55%, if not properly treated.<sup>6</sup> Recently, the autoimmune process is considered as the main pathophysiologic factor of CCS due to the good response in steroid treatment and IgG4-positive cells in tissue biopsy.<sup>7</sup>

Common presenting symptoms of CCS are diarrhea, weight loss, abdominal pain, and anorexia. Characteristic ec-

todermal changes, such as nail changes, hair loss, and skin hyperpigmentation are present in more than 70% of cases.<sup>6</sup> Polyps can involve the entire gastrointestinal tract, from the esophagus to the rectum; however, the esophagus is usually rarely involved (2-12%).<sup>2,6</sup> Histologic findings of polyps are usually nonspecific, showing hyperplastic polyp, hamartomatous or juvenile polyp, inflammatory polyp, and tubular adenoma.<sup>4</sup> At the initial presentation or during the follow-up period, gastrointestinal malignancies, such as colon or gastric cancer, are reported (15-25%).<sup>5</sup> However, whether polyps in CCS possess malignant potential has been controversial due to the difficulties distinguishing between premalignant adenomas and multiple inflammatory pseudopolyps.<sup>2</sup>

Given its rarity, standard treatment of CCS has not yet been established. However, steroid administration accompanied by nutritional support is known as the mainstay of treatment. Regression of polyposis and achievement of sustained endoscopic remission are the purpose for treating CCS. Watanabe et al. suggested that good early response (regression of polyposis within 6-12 months after the start of treatment or initial diagnosis) and good long-term response (maintenance of endoscopic remission over a 3-year period after initial treatment) are related with favorable prognosis.<sup>2</sup> Administration of histamine H2 receptor antagonist, proton pump inhibitor, 5-aminosalicylic acid, antibiotics, and *Helicobacter pylori* eradication also showed good results in previous reports.<sup>4</sup> During the follow-up period, CCS can recur even in patients with successful discontinuation of steroid and clinical remission; thus, minimal annual endoscopic surveillance is

usually recommended and maintenance treatment using a low-dose steroid, immunomodulator, and anti-tumor necrosis factor should also be considered.

In conclusion, CCS may be associated with significant complications, such as gastrointestinal bleeding, infection, and malignancy. However, early detection and proper steroid administration can achieve rapid clinical improvement and regression of polyposis, which can bring better overall outcome of CCS, as we have seen in this case. During long-term follow-up, recurrence of polyposis and CCS-related cancer can develop; thus, regular endoscopic surveillance is recommended.

## REFERENCES

1. Cronkhite LW Jr, Canada WJ. Generalized gastrointestinal polyposis; an unusual syndrome of polyposis, pigmentation, alopecia and onychotrophia. *New Engl J Med* 1955;252:1011-1015.
2. Watanabe C, Komoto S, Tomita K, et al. Endoscopic and clinical evaluation of treatment and prognosis of Cronkhite-Canada syndrome: a Japanese nationwide survey. *J Gastroenterol* 2016;51:327-336.
3. Wen XH, Wang L, Wang YX, Qian JM. Cronkhite-Canada syndrome: report of six cases and review of literature. *World J Gastroenterol* 2014;20:7518-7522.
4. Kang DU, Yang DH, Choi Y, et al. A case of Cronkhite-Canada syndrome showing spontaneous remission. *Intest Res* 2013;11:317-322.
5. Yun SH, Cho JW, Kim JW, et al. Cronkhite-Canada syndrome associated with serrated adenoma and malignant polyp: a case report and a literature review of 13 Cronkhite-Canada syndrome cases in Korea. *Clin Endosc* 2013;46:301-305.
6. Daniel ES, Ludwig SL, Lewin KJ, Ruprecht RM, Rajacich GM, Schwabe AD. The Cronkhite-Canada syndrome. An analysis of clinical and pathologic features and therapy in 55 patients. *Medicine (Baltimore)* 1982;61:293-309.
7. Sweetser S, Ahlquist DA, Osborn NK, et al. Clinicopathologic features and treatment outcomes in Cronkhite-Canada syndrome: support for autoimmunity. *Dig Dis Sci* 2012;57:496-502.