



Case report

Fusobacterium necrophorum presenting as isolated lung nodules



Rajiv Sonti*, Christine Fleury

Department of Pulmonary, Critical Care and Sleep Medicine, MedStar Georgetown University Hospital, USA

ARTICLE INFO

Article history:

Received 19 February 2015

Received in revised form

12 May 2015

Accepted 16 May 2015

Keywords:

Pulmonary nodule

Fusobacterium necrophorum

Lemierre's syndrome

ABSTRACT

Fusobacterium necrophorum causes Lemierre's syndrome - a dramatic and distinct condition beginning with pharyngitis before proceeding to internal jugular vein septic thrombophlebitis and respiratory tract infection in otherwise healthy individuals. It is rare, but by far the most common pathway to parenchymal lung disease with this organism. Here we describe we a 34 year old healthy lady who was nontoxic without any antecedent illness who presented with lung nodules due to fusobacterium necrophorum as the sole manifestation of disease. Leading diagnostic consideration prior to culture data was pulmonary vasculitis. Identifying her disease process was a somewhat chance occurrence, and it began to resolve prior to antibiotic therapy. Though it would be difficult to recommend keen awareness of this organism given its rarity, it is important to consider that its scope may be broader than traditionally considered.

© 2015 The Authors. Published by Elsevier Ltd. This is an open access article under the CC BY-NC-ND license (<http://creativecommons.org/licenses/by-nc-nd/4.0/>).

1. Introduction

Lemierre's syndrome is the most common condition associated with the gram negative anaerobe *Fusobacterium necrophorum*, though several other patterns of infection can occur. The infrequency with which those rarer presentations are encountered make consideration of this organism in settings outside of pharyngitis a challenge. Pulmonary involvement after persistent pharyngitis and internal jugular septic thrombophlebitis is well described [1], but here we describe a case of lung nodules related to *Fusobacterium necrophorum* without any antecedent illness.

2. Case

A healthy 34 year old woman presented to medical attention after experiencing several days of moderately severe pleuritic chest pain without other respiratory or constitutional symptoms. She was Ecuadorian where she lived until the age of 5 and had not recently been, worked at a local supermarket (although not in food handling capacity) and had moderate persistent asthma well controlled on combination long acting beta-agonist and medium dose inhaled

corticosteroid. Contrast CT scan of the chest demonstrated several bilateral pulmonary nodules without infiltrate, adenopathy or effusion. The largest was 1.5 × 1.5 cm in the left upper lobe with cavitation (Fig. 1). Active tuberculosis was ruled out. Blood cultures were negative and transthoracic echocardiogram did not demonstrate valvular vegetations. Nonspecific inflammatory markers were elevated: C-rp 61 mg/L (normal range: 0–3) and ESR 28 MM/h (normal range: 0–22) and ANA was positive with titer 1:80; however, ANCA were within the normal range. She did not have a leukocytosis (WBC 8300/uL). Serologic evaluation for fungal disease was negative. She had a mild transaminitis with alanine aminotransferase > aspartate aminotransferase and imaging of the liver via ultrasound and CT scan revealed steatosis without discrete lesions. Expecterated sputum grew *Mycobacterium avium* complex; however the clinical scenario seemed largely incompatible. Airway examination on bronchoscopy and bronchoalveolar lavage were also unrevealing. The patient underwent a surgical biopsy of the left upper lobe nodule - our leading diagnostic consideration of which at the time was seronegative pulmonary vasculitis. Pathology did not show granuloma, malignancy or AFB; rather, was an abscess (Fig. 3). Culture of the material grew *Fusobacterium necrophorum*. Notably, she had no upper respiratory symptoms, neck pain, febrile illness or dental work around the time of this presentation. On further detailed questioning she recalled a sore throat 5 months prior without fever, and enjoyed several months of good health in the intervening time. CT of sinus/neck were normal and in fact, on repeat chest CT several weeks later lung nodules

* Corresponding author. Medstar Georgetown University Hospital; Division of Pulmonary, Critical Care and Sleep Medicine; 3800 Reservoir Road 4Main; Washington DC 20007, USA.

E-mail address: rsonti@gmail.com (R. Sonti).

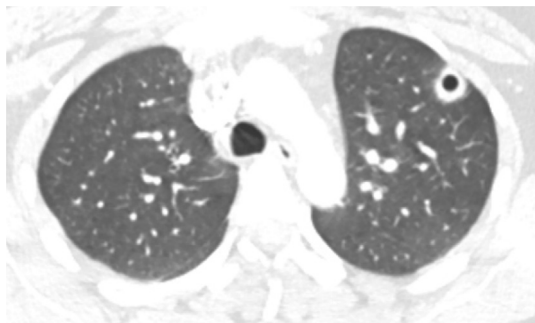


Fig. 1. 1.5 cm left upper lobe cavitary nodule.

contralateral to biopsy and prior to any therapy were smaller in size (Fig. 2). We elected to treat with ertapenem for 6 weeks and CT scan after therapy showed resolution of all dominant nodules. Of note, chest pain resolved well prior to initiation of therapy and has not recurred.

3. Discussion

Lemierre's syndrome is rare disease of healthy young individuals [1]. Case definition, though not universally agreed upon, includes a constellation of findings: persistent pharyngitis, internal jugular vein septic thrombophlebitis along with evidence of metastatic lesions with isolation of *Fusobacterium necrophorum* (or rarely other oral anaerobes [2]) from an infected site [3]. The lung is the site of metastasis in up to 97% of cases [4], appearing as nodules, infiltrate, empyema and ARDS [5]; occasionally joints, the CNS and the liver are involved as well. Although mortality is lower than originally described by Dr. Lemierre in 1936, infection can still be

lethal with a mortality rate around 5% [3]. Little is known about the pathogenesis; for example, there is limited data to support the traditional hypothesis that the organism is a normal oropharyngeal resident [6]. Infection may in fact be precipitated by consuming food or water contaminated with fecal material [7] during periods of pharyngeal epithelial inflammation from viral infection [8], although in most individuals, Lemierre's syndrome occurs without clear precipitating condition or discernible risk factor.

Normally invasive *Fusobacterium necrophorum* disease is dramatic and highly characteristic. Fever, tachycardia and marked leukocytosis are typical features, in contrast to our patient's largely asymptomatic presentation. Additionally, the presence of septic pulmonary emboli has been used as a surrogate for the presence of thrombophlebitis [3,9], thought to be required for the development of lung disease as either the origin of emboli or through direct extension of infectious material to the lung or pleural space. This was also absent in our case.

One possible explanation for our patient's atypical presentation is that her initial bacteremia was the consequence of subclinical rather than overt pharyngitis. There is a suggestion in the literature that the disease has a male predominance and peak age of incidence 16–23 [8] for reasons that are not clear. Perhaps disease, if present, is less likely to be severe and therefore underrecognized in a phenotype similar to our patient: female and slightly older. There is a small body of evidence supporting the existence of more minor forms of the disease – for example, in one study 10% of throat swabs in uncomplicated pharyngitis grew *Fusobacterium necrophorum* when cultured anaerobically (not common practice) [10], suggesting that full blown Lemierre's syndrome is not necessarily the only outcome of upper respiratory tract infection. Metastatic *Fusobacterium necrophorum* lesions separated from pharyngitis by weeks to months has been rarely described [11,12]; in one report, the organism was isolated from a liver abscess two months after a URI. Our patient's sore throat was five months prior, not associated

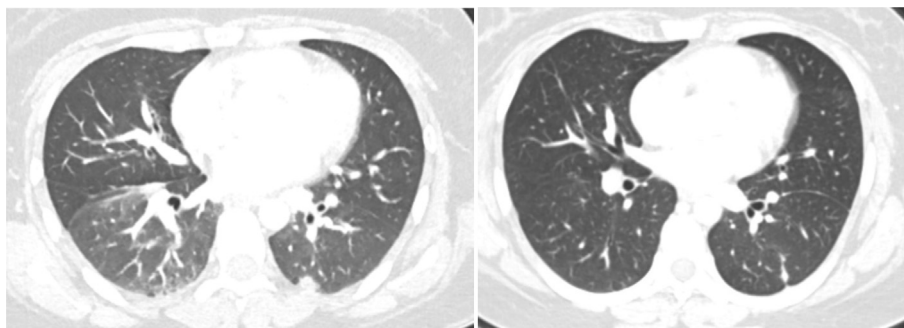


Fig. 2. Rounded inferio-medial left lower lobe nodule present on CT on original CT scan (left); absent just prior to initiation of treatment (right).

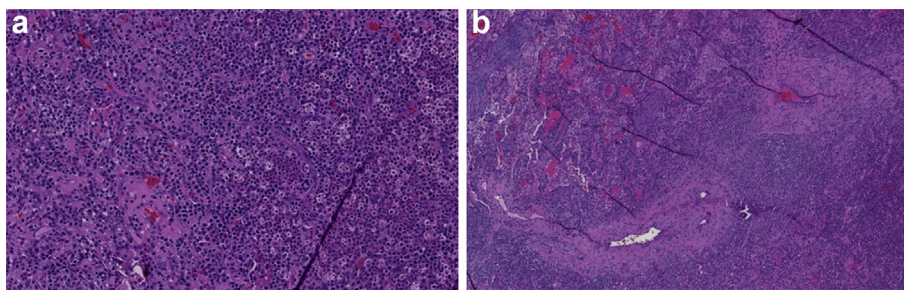


Fig. 3. a (left): H&E stain of left upper lobe nodule at high power demonstrating absent normal lung architecture and diffuse inflammatory cell infiltrate with both PMNs and plasma cells (indicating some degree of chronicity) present. 3b (right): Lower power view with blood vessels and bronchi present; though there is fibrotic reaction surrounding the blood vessel, there is no evidence of vasculitis.

with fever and therefore hard for us to imagine related to her lung lesions.

Another possibility is infection not coming from the oropharynx. The GI or GU tracts have been speculated to be additional sites of origin [13]; often described as “necrobacillosis” not fitting the case definition of Lemierre's syndrome. But, the lung is often *not* the metastatic site in invasive *Fusobacterium necrophorum* disease without sore throat [13,14] and more commonly the liver, bone and joints are involved. This perhaps reflects the routes of venous and lymphatic spread from the tissue of origin. We doubt that the organism was a bystander in a polymicrobial abscess as it was the sole organism that grew from a surgical biopsy specimen. Additionally, *Fusobacterium necrophorum* has never to our knowledge been isolated and thought to be a secondary passenger.

Though *Fusobacterium necrophorum* infections are curable, they are potentially lethal and mortality in the pre-antibiotic era was substantial. Their low incidence is thought in part related to widespread use of potent antibiotics; therefore, we were surprised to find resolution of nodules prior to antibiotics. Perhaps she would have cleared infection on her own (though we deemed it inappropriate to withhold treatment). It would be inconsistent based on our appraisal of the literature to recommend keen awareness of this organism in an otherwise unexplained pleuropulmonary syndrome given its rarity. Nevertheless, our patient had metastatic *Fusobacterium necrophorum* lung lesions, the source of which we can only speculate.

4. Conclusions

Metastatic spread of *Fusobacterium* is usually related to overt pharyngitis. Here we describe necrobacillosis with pulmonary nodules, one cavitory, as the sole manifestation of disease in a nontoxic patient without pharyngitis. Identifying her disease process was a somewhat chance occurrence, and it began to resolve prior to antibiotic therapy.

Contributorship

Rajiv Sonti and Christine Fleury cared for the patient; Rajiv Sonti wrote the manuscript with edits from Christine Fleury.

Conflict of interest

None Declared.

References

- [1] K. Afra, K. Laupland, J. Leal, T. Lloyd, D. Gregson, Incidence, risk factors, and outcomes of *Fusobacterium* species bacteremia, *BMC Infect Dis* 13 (2013) 264.
- [2] W.F. Wright, C.N. Shiner, J.A. Ribes, Lemierre syndrome, *South Med J* 105 (5) (2012 May) 283–288.
- [3] T. Riordan, Human infection with *Fusobacterium necrophorum* (Necrobacillosis), with a focus on Lemierre's syndrome, *Clin Microbiol Rev* 20 (4) (2007 Oct) 622–659.
- [4] C.P. Sinave, G.J. Hardy, P.W. Fardy, The Lemierre syndrome: suppurative thrombophlebitis of the internal jugular vein secondary to oropharyngeal infection, *Medicine* 68 (1989) 85–94.
- [5] J.I. Litmathe, P. Zardo, N. Dickgreber, G. May, C. Sucker, S. Fischer, Severe ARDS induced by fusobacterial infections: a rare clinical presentation of Lemierre syndrome, *Thorac Cardiovasc Surg* 61 (8) (2013 Dec) 754–757.
- [6] J.M. Alston, Necrobacillosis in Great Britain, *Br Med J* (1955) 1524–1528.
- [7] P.D. Karkos, S. Asrani, C.D. Karkos, S.C. Leong, E.G. Theochari, T.D. Alexopoulou, et al., Lemierre's syndrome: a systematic review, *Laryngoscope* 119 (8) (2009 Aug) 1552–1559.
- [8] Human infections with *Fusobacterium necrophorum*, *Anaerobe* 12 (4) (2006 Aug) 165–172.
- [9] C.A. Righini, A. Karkas, R. Tourniaire, J.M. N'Gouan, S. Scherber, E. Reyt, et al., Lemierre syndrome: study of 11 cases and literature review, *Head Neck* 36 (7) (2014 Jul) 1044–1051.
- [10] A. Batty, M.W. Wren, Prevalence of *Fusobacterium necrophorum* and other upper respiratory tract pathogens isolated from throat swabs, *Br J Biomed Sci* 62 (2) (2005) 66–70.
- [11] H. Brocard, C. Guidé, Les septicémies à *Bacillus fusiformis*, *Rev. Prat.* 7 1285–1300.
- [12] E. Harrington, M.A. Bleicher, Cryptogenic hepatic abscess in two uncompromised children, *J. Pediatr. Surg.* 15 660–662.
- [13] S.J. Eykyn, Necrobacillosis, *Scand. J. Infect. Dis.* 62 41–46.
- [14] J.L. Olson, N. Mandava, Bilateral intraocular involvement in Lemierre's syndrome, *Br. J. Ophthalmol.* 90 249–250.