

# Protective Effects of Rutin and Naringin in Testicular Ischemia-Reperfusion Induced Oxidative Stress in Rats

Butchi Raju Akondi\*, Siva Reddy Challa, Annapurna Akula

- Division of Pharmacology, Andhra University College of Pharmaceutical Sciences, Andhra University, Visakhapatnam, Andhra Pradesh, India

## Abstract

**Introduction:** Testicular torsion and detorsion causes reperfusion injury which damages the testicular tissue and affects the quality of sperm. Deterioration in the quality of sperm worldwide is the recent scenario and one of its reasons is testicular ischemic/ reperfusion (IR) injury. Therefore the present study aims at producing new drugs for the treatment of testicular IR injury.

**Methods:** 42 animals were selected for the study and divided into 7 groups, each containing 6 rats. Bioflavonoids were tested for their efficacy in reversing the damage done to the testicular tissue by causing testicular torsion and detorsion in rats. As oxidative stress produced in the above condition causes tissue damage, MDA level was measured and antioxidant enzymes SOD and catalase were evaluated. Histological examination was conducted to find the extent of damage and the protective effect of rutin and naringin. One-way ANOVA and Tukey's post-hoc test were used for data analysis. A p-value < 0.001 was considered statistically significant.

**Results:** MDA levels increased and antioxidant enzymes decreased drastically in the group of rats with testicular torsion and detorsion which clearly indicates a rise in oxidative stress (68% rise in the case of MDA and 20% and 16% decrease in SOD and catalase concentrations, respectively). Rutin and naringin-treated groups showed the beneficial effects of the medicinal drugs, particularly in higher doses. Rutin, 10 mg/kg, was effective when compared to naringin in providing protection. Compared to the animals in the control group, there was a 30% reduction in MDA levels and a 20% increment in SOD levels plus a five-fold increase in catalase in the rutin-treated group (10 mg/kg). Histological examination supported the above claims.

**Conclusion:** Oxidative stress in testicular injury affects the quality of sperm. Rutin and naringin in higher doses protected testicular tissue effectively. Further studies in this direction may prove beneficial.

**Keywords:** Ischemia, Ischemic reperfusion injury, Male infertility, Naringin, Reperfusion, Rutin, Testicular torsion.

**To cite this article:** Akondi BR, Challa SR, Akula A. Protective Effects of Rutin and Naringin in Testicular Ischemia-Reperfusion Induced Oxidative Stress in Rats. *J Reprod Infertil.* 2011;12(3):209-214.

\* Corresponding Author:  
Butchi Raju Akondi,  
Division of Pharmacology,  
Andhra University  
College of Pharmaceutical  
Sciences, Andhra  
University,  
Visakhapatnam, Andhra  
530003, India.  
E-mail:  
drraju2020@gmail.com

Received: Dec. 18, 2010

Accepted: Jun. 6, 2011

## Introduction

Testicular torsion (TT) is one of the pediatric emergency conditions which require immediate attention. The twisted spermatic cord may induce ischemia and damage the testicular tissues (1). Untwisting or testicular detorsion (TD) further aggravates the condition and leads to the generation of reactive oxygen species (ROS). This

particular condition can be termed as testicular Ischemia Reperfusion (IR) Injury (2). Under normal conditions, free radicals are produced and their effects are counterbalanced by the endogenous antioxidant system (3). When ROS generation exceeds the defense mechanism's capacity to control, oxidative stress is generated and contrib-

utes to reversible or irreversible cell injury (4 - 7).

The incidence of testicular torsion is very high. In one study 1 in 158 males by the age of 25 were affected by testicular torsion and majority (around 35%) of them suffered from poor ejaculate quality (8). Many studies recently reported loss of germ cells and disruption of the seminiferous epithelium after IR injury of the testis (9, 10). Therefore, testicular torsion is a serious problem in male children and, if not treated at the right time, can lead to sub-fertility and infertility.

Previously, several enzymes and drugs were used to treat testicular reperfusion injury. They were intended to inhibit oxidative stress. Zinc aspartate reduces IR injury and increases the activity of antioxidant enzyme systems (5). Cannabinoids, like anandamide, were tried successfully to reduce testicular IR injury (11). Wide varieties of drugs like curcumin and dexamethasone were also found protective in IR injury of testis (12, 13).

Bioflavonoids, like rutin and naringin, were proved beneficial as antioxidants particularly they were found useful in IR injury of other organs i.e. heart and kidneys. In this study, we wanted to evaluate bioflavonoids, rutin and naringin, for their protective role against testicular IR injury (14). Our aim is to provide therapeutically active compounds for the treatment of testicular IR injury.

### Methods

**Animals used in the study:** Forty-two male albino wistar rats (National Institute of Nutrition, Hyderabad, India) weighing 175-250 g were used in the study. Animals were maintained under standard laboratory conditions at  $20 \pm 25^\circ\text{C}$ , relative humidity of  $50 \pm 15\%$  and normal photoperiod (12 h dark/ 12 h light). Commercial pellet diet (Rayons biotechnologies Pvt. Ltd, India) and water were provided *ad libitum*. The experiment protocol was approved by the Institutional Animal Ethics Committee and by the Animal Regulatory Body of the Government (Regd. No. 516/01/A/CPCSEA).

**Experimental groups:** In total, 42 animals were selected for the study and divided into 7 groups, each containing 6 rats. Group 1 was the normal control group in which the rats, did not undergo any surgical procedure. Group 2 was the control groups which underwent 4 hours of testicular tor-

sion (TT) and 4 hours of testicular detorsion (TD). No drug was given to these animals. Group 3 was the vehicle control group and animals in this group underwent 4 hours of TT and 4 hours of TD. The animals in this group received 0.1% sodium carboxy methyl cellulose, half an hour before testicular torsion. Sodium carboxy methyl cellulose (Soduim CMC) was the vehicle used for the preparation of the drug solutions. Groups 4, 5, 6 and 7 were the test groups which received rutin 5 mg/kg, rutin 10 mg/kg, naringin 5 mg/kg, and naringin 10 mg/kg, respectively half an hour before the testicular detorsion. Rutin and naringin were obtained from Sigma Chemicals, USA. The doses of the above drugs were chosen from the reports of the pilot study conducted in our laboratory.

**Experimental protocol:** On the day of the experiment, the animals were anesthetized with thiopentone sodium (Neon Labs Limited, Mumbai) 30 mg/kg body weight and the surgical operation described below was performed. After the induction of anesthesia, a left scrotal incision was made. The tunica vaginalis was opened, and the testicle was delivered to the surgical field. The testicle was rotated  $720^\circ$  in a clockwise direction and maintained in this twisted position by fixing the testicle to the scrotum with a silk suture. The scrotum was closed and 4 hours later reentered for testicular detorsion. After spermatic cord detorsion the left testicle was replaced in to the scrotum and scrotum was closed. After completion of the 4- hour detorsion period, bilateral orchietomies were performed. The testes were washed with normal saline and stored in a  $-20^\circ\text{C}$  refrigerator for the evaluation of biochemical parameters (protein, malondialdehyde, SOD and Catalase). The experimental procedure was well-tolerated and no animal died during the experiment. All animals were sacrificed by cervical dislocation after completion of the procedure. The vehicle and the drugs (rutin and naringin) were injected Intraperitoneally (IP) half an hour before testicular detorsion 5.

**Biochemical parameters estimation:** Malanoldhyde (MDA) levels in the testicular tissue were measured by the method developed by Ohkawa (15). This is based on the measurement of thio-barbituric acid malanoldhyde absorbance. The tissue MDA levels were expressed as nmol/g

tissue. Super oxidizedismutase (SOD) activity was determined by the method developed by Beauchamp and Fridovich (16). This method was based on the inhibition of reaction between superoxide radicals and nitro blue tetrazolium chloride. The specific activity was expressed in terms of units for mg of protein. Catalase activity was measured based on Aebi's method (17). In this method, activity of catalase is based on the disappearance of hydrogen peroxide. Activity of catalase was expressed as  $\mu$ moles of H<sub>2</sub>O<sub>2</sub> metabolized/mg protein/min. One unit was defined as 1 pmol of H<sub>2</sub>O<sub>2</sub> consumed per minute, and the specific activity was reported as units per milligram of protein. Protein was estimated by the method developed by Lowry (18).

**Histopathological examination:** The testes were fixed in 10% formalin and embedded in paraffin. Five-micron thick sections were prepared and stained with hematoxylin and eosin (H&E). The tissue sections were evaluated under light microscopy by a blinded pathologist. The tissue sections were examined as given in the classification below:

Grade 1: Normal testicular architecture and orderly arrangement of germinal cells

Grade 2: Less orderly, noncohesive germinal cells and closely- packed seminiferous tubules

Grade 3: Disordered, sloughed germinal cells with shrunken pycnotic nuclei and less distinct seminiferous tubule borders

Grade 4: Seminiferous tubules that were closely packed with coagulative necrosis of the germinal cells (19).

**Statistical analysis:** The results are expressed as mean  $\pm$  SD. The differences in tissue lipid peroxide levels, superoxide dismutase (SOD) and Catalase (CAT) were determined by factorial one-way analysis of variance. Individual groups were compared using Tukey's test. Differences with a P-value<0.001 were considered statistically significant. Statistical analysis was performed using Graph Pad Prism software (Version 5).

## Results

MDA, SOD and catalase levels in the testicular tissue were evaluated in different groups of rats (Table 1). In group 1, MDA, SOD and catalase levels were found to be  $187.9 \pm 8.71$  nmol/g of tissue,  $1681.21 \pm 8.06$  units/mg protein, and 24.30

**Table 1.** Consolidated biochemical Parameters

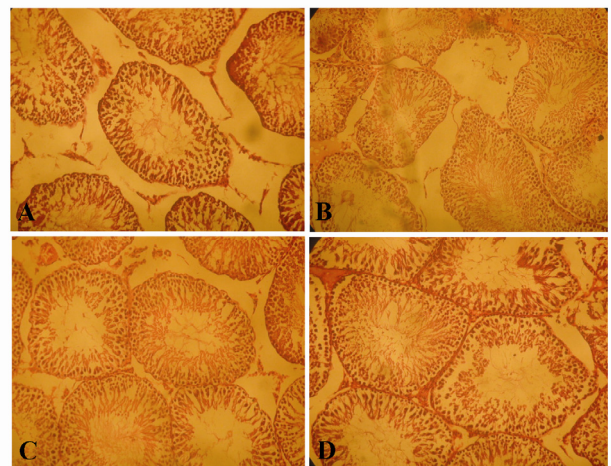
Groups	MDA (nmol/g tissue)	SOD (u/mg protein)	Catalase (u/mg protein)
Group 1	187.9 $\pm$ 8.7	1681.21 $\pm$ 8.06	24.30 $\pm$ 1.12
Group 2	315.43 $\pm$ 12.05 *	1374.96 $\pm$ 11.02 *	4.06 $\pm$ 0.41 *
Group 3	307.5 $\pm$ 4.05	1360.735 $\pm$ 8.38	4.151667 $\pm$ 0.31 **
Group 4	256.34 $\pm$ 10.86 **	1523.697 $\pm$ 7.31 **	15.87333 $\pm$ 0.88 **
Group 5	216.49 $\pm$ 6.68 **	1639.111 $\pm$ 16.41 **	20.06167 $\pm$ 1.24 **
Group 6	273.01 $\pm$ 10.11 **	1493.823 $\pm$ 9.36 **	10.88 $\pm$ 0.38 **
Group 7	232.82 $\pm$ 5.77 **	1588.807 $\pm$ 7.55 **	16.32 $\pm$ 0.71 **

Groups treated with rutin and naringin have shown reduced MDA levels and decreased SOD and catalase levels when compared to the control group

\* P<0.001 vs. Normal control group by one way ANOVA/Tukey's test

\*\* P<0.001 vs. Control group by one way ANOVA/Tukey's test

$\pm 1.12$  units/mg protein respectively. After 4 hours of torsion and 4 hours of detorsion, MDA levels significantly increased in Group 2 animals. Antioxidant enzymes, SOD and catalase, decrease significantly. In group 3, the vehicle-treated animals, did not show any improvement as there was no reduction in malonaldehyde concentration or increase in antioxidant enzymes when compared to group 2 or the control animals. Animals treated with 5 mg/kg and 10 mg/kg of rutin and naringin (Groups 4, 5, 6, 7) showed significant and dose-dependent reduction in MDA levels and increases in levels of antioxidant enzymes, SOD and cata-



**Figure 1.** A: Normal Testis with orderly arrangement of germinal cells (Hematoxylin and eosin; staining; magnification x100), B: Disordered, sloughed germinal cells within the seminiferous tubules in the torsion/detorsion group (Hematoxylin and eosin staining; magnification x100), C: Protective effect of rutin 10 mg/kg (Hematoxylin and eosin staining; magnification x100), D: Protective effect of naringin, 10 mg/kg (Hematoxylin and eosin staining; magnification x10)

lase.

Histological results also supported the above findings. Testes of rats from group 1 showed normal testicular architecture with an orderly arrangement of germinal cells. Testes of animals in Group 2 and 3 exhibited disordered, sloughed germinal cells with shrunken pycnotic nuclei and less distinct seminiferous tubule borders. The testes of rats in groups 4, 5, 6 and 7 witnessed improved histological architecture and orderly arrangement of germinal cells compared to group 2 (Figure 1).

When compared with naringin, rutin offered more degree of protection in all the three biochemical parameters and histological findings. It indicates that both bioflavonoids were effective in reducing the oxidative stress in testicular ischemia reperfusion (IR) injury.

### Discussion

The incidence of testicular torsion is a urologic emergency which occurs in 1 out of 158 males by the age of 25. The majority of the cases may suffer from poor ejaculate quality afterwards (8). Numerous studies have reported increases in oxidative stress in the testis after testicular ischemia reperfusion injury (20). Testicular ischemia reperfusion injury is a classic inducer of oxidative stress. Therefore, reperfusion may be considered as a double-edged sword as it is essential for the survival of the tissue but it, may actually exacerbate rather than diminish cell injury. There were reports about adverse effects on testicular function, including germ cell loss and disruption of the seminiferous epithelium. Testicular torsion is a serious problem in male children and, if not treated at the right time, can lead to sub-fertility and infertility.

As might be expected, inhibitors of oxidative stress provide significant beneficial effect on testicular ischemia reperfusion injury (21). Bioflavonoids, considered as classical examples for antioxidants have been already proved as effective agents in ischemia reperfusion injury of other organs. Bioflavonoid, rutin is a powerful radical scavenger (22) and its free radical scavenging ability may be due to its inhibitory activity on the enzyme xanthine oxidase. When oxygen is supplied during reperfusion, xanthine oxidase converts hypoxanthine to uric acid and superoxide radicals. Other flavonoids like quercetin and

silibin, also inhibit xanthine oxidase activity, thereby resulting in decreased oxidative injury (23 - 25).

As calcium influx into the neutrophils causes release of superoxide radicals, flavonoids are useful as they were proved to inhibit degranulation of neutrophils. The inhibitory effects of some flavonoids on mast cell degranulation were shown to be due to modulation of the receptor-directed Ca<sup>2+</sup> channels in the plasma membrane (26). Another interesting effect of flavonoids on enzyme systems is the inhibition of arachidonic acid metabolism (27). This feature might be responsible for flavonoids' anti-inflammatory and antithrombotic properties.

Free radicals react with lipids in cell membranes and form lipid peroxides and this changes the integrity of cells. Rutin, being an anti-lipoxidant agent, inhibits formation of lipid peroxides (28). Naringin also has antioxidant potentials. It acts by lowering the lipid peroxidation. Naringin scavenges free radicals and its activity is attributed to its structure (29). Recent study on two bioflavonoids, Rutin and quercetin, showed they decreased MDA levels and increased antioxidant enzyme levels in cardiac ischemia reperfusion injury. The mechanism of reperfusion injury induced oxidative stress is similar in cardiac reperfusion injury and testicular ischemia reperfusion injury (14).

In this study, MDA levels increased and SOD and catalase levels decreased significantly in Group 2 (the controls) when compared to group 1 (the normal controls). This shows testicular ischemia reperfusion injury. Histopathological examinations were in accordance with elevated testicular tissue MDA levels. Vehicle treated animals (group 3) shown similar results as group 2 (the controls). This shows that vehicle does not have any protective effects. Rutin and naringin- treated groups 4, 5, 6 and 7 showed dose- dependent, significant decreases in MDA levels and increases in SOD and catalase levels. This may be due to the acute antioxidant effects of bioflavonoids, rutin and naringin. When compared to naringin, rutin showed maximum benefit. Rutin had more antioxidant activity when compared to naringin, which seems to be correlated to its structure. In fact, rutin showed higher scavenger efficiency than naringin in 2,2-diphenyl-1-picrylhydrazyl



(DPPH), and thiobarbituric acid (TBA) tests. This effect may be attributable to the catechol structure of ring B, the 2, 3 double bond in conjugation with a 4-oxo function, and the presence of both 7- and 5-hydroxyl groups (30). Histopathological findings of the above groups also confirmed the same. There was improvement in testicular architecture in groups treated with rutin and naringin.

Much work has not been done on testicular ischemia reperfusion injury. Particularly to our knowledge, no bioflavonoid had been tested on testicular IR injury. Drugs other than bioflavonoids like zinc aspartate given to rats in a similar model proved effective as antioxidant. The results of our study are in accordance with their results. Ibuprofen, an NSAID, prevented lipid peroxidation and decreased MDA accumulation just as in our study (31). The model used was similar except the time period used for the ischemia and reperfusion. N-acetylcysteine was also proved effective in IR injury by decreasing malonaldehyde levels and increasing antioxidant enzyme levels (32). The results were in accordance with our results. Antioxidant, erdosteine was also proved beneficial in testicular IR injury. Results were similar and in accordance with our results. The protective effects of selenium was proved in testicular IR injury. The MDA levels decreased and SOD levels increased. Histopathological studies in treated rats showed almost normal architecture. In our study, both rutin and naringin showed similar effects (33, 34).

### Conclusion

We have selected this model of spermatic cord torsion to produce testicular IR injury based on the earlier reports and we are convinced that this method simulates the true clinical IR injury. Our findings, reduction of elevated MDA levels and normalization of SOD and catalase levels and less damage to the testicular architecture after treating the rats with rutin and naringin in testicular IR injury model might have place in therapeutic regimens to be used clinically prior to manual detorsion.

### References

1. Wei SM, Yan ZZ, Zhou J. Beneficial effect of taurine on testicular ischemia-reperfusion injury in rats. *Urology*. 2007;70(6):1237-42.
2. Koc A, Narci A, Duru M, Gergerlioglu HS, Akaydin Y, Sogut S. The protective role of erdosteine on testicular tissue after testicular torsion and detorsion. *Mol Cell Biochem*. 2005;280(1-2):193-9.
3. Salmasi AH, Beheshtian A, Payabvash S, Demehri S, Ebrahimkhani MR, Karimzadegan M, et al. Effect of morphine on ischemia-reperfusion injury: experimental study in testicular torsion rat model. *Urology*. 2005;66(6):1338-42.
4. Ozkan KU, Küçükaydin M, Muhtaroglu S, Kontaş O. Evaluation of contralateral testicular damage after unilateral testicular torsion by serum inhibin B levels. *J Pediatr Surg*. 2001;36(7):1050-3.
5. Ozkan KU, Boran C, Kiliç M, Garipardıç M, Kurutaş EB. The effect of zinc aspartate pretreatment on ischemia-reperfusion injury and early changes of blood and tissue antioxidant enzyme activities after unilateral testicular torsion-detorsion. *J Pediatr Surg*. 2004;39(1):91-5.
6. Can C, Töre F, Tunçel N, Uysal O, Gürer F, Ak D, et al. Protective effect of vasoactive intestinal peptide on testicular torsion-detorsion injury: association with heparin-containing mast cells. *Urology*. 2004;63(1):195-200.
7. Turrens JF, Boveris A. Generation of superoxide anion by the NADH dehydrogenase of bovine heart mitochondria. *Biochem J*. 1980;191(2):421-7.
8. Anderson JB, Williamson RC. Testicular torsion in Bristol: a 25-year review. *Br J Surg*. 1988;75(10):988-92.
9. Turrens JF. Superoxide production by the mitochondrial respiratory chain. *Biosci Rep*. 1997;17(1):3-8.
10. Lysiak JJ, Turner SD, Nguyen QA, Singbartl K, Ley K, Turner TT. Essential role of neutrophils in germ cell-specific apoptosis following ischemia/reperfusion injury of the mouse testis. *Biol Reprod*. 2001;65(3):718-25.
11. Rabani R, Sadeghipour-Roodsari HR, Sepehri H, Hassanzadeh-Salmasi AA, Dehpour AR. Effect of cannabinoids on testicular Ischemia-reperfusion injury in rat. 2006;44(6):365-370.
12. Wei SM, Yan ZZ, Zhou J. Curcumin attenuates ischemia-reperfusion injury in rat testis. *Fertil Steril*. 2009;91(1):271-7.
13. Mogilner JG, Elenberg Y, Lurie M, Shiloni E, Coran AG, Sukhotnik I. Effect of dexamethasone on germ cell apoptosis in the contralateral testis after testicular ischemia-reperfusion injury in the rat. *Fertil Steril*. 2006;85 Suppl 1:1111-7.

14. Annapurna A, Reddy CS, Akondi RB, Rao SR. Cardioprotective actions of two bioflavonoids, quercetin and rutin, in experimental myocardial infarction in both normal and streptozotocin-induced type I diabetic rats. *J Pharm Pharmacol.* 2009;61(10):1365-74.
15. Ohkawa H, Ohishi N, Yagi K. Assay for lipid peroxides in animal tissues by thiobarbituric acid reaction. *Anal Biochem.* 1979;95(2):351-8.
16. Beauchamp C, Fridovich I. Superoxide dismutase: improved assays and an assay applicable to acrylamide gels. *Anal Biochem.* 1971;44(1):276-87.
17. Aebi H. Catalase in vitro. *Methods Enzymol.* 1984;105:121-6.
18. Lowry OH, Rosebrough NJ, Farr AL, Randall RJ. Protein measurement with the Folin phenol reagent. *J Biol Chem.* 1951;193(1):265-75.
19. Cosentino MJ, Nishida M, Rabinowitz R, Cockett AT. Histopathology of prepubertal rat testes subjected to various durations of spermatic cord torsion. *J Androl.* 1986;7(1):23-31.
20. Turrens JF. Superoxide production by the mitochondrial respiratory chain. *Biosci Rep.* 1997;17(1):3-8.
21. Turner TT, Bang HJ, Lysiak JL. The molecular pathology of experimental testicular torsion suggests adjunct therapy to surgical repair. *J Urol.* 2004;172(6 Pt 2):2574-8.
22. Hanasaki Y, Ogawa S, Fukui S. The correlation between active oxygens scavenging and antioxidative effects of flavonoids. *Free Radic Biol Med.* 1994;16(6):845-50.
23. Shoskes DA. Effect of bioflavonoids quercetin and curcumin on ischemic renal injury: a new class of renoprotective agents. *Transplantation.* 1998;66(2):147-52.
24. Chang WS, Lee YJ, Lu FJ, Chiang HC. Inhibitory effects of flavonoids on xanthine oxidase. *Anti-cancer Res.* 1993;13(6A):2165-70.
25. Iio M, Ono Y, Kai S, Fukumoto M. Effects of flavonoids on xanthine oxidation as well as on cytochrome c reduction by milk xanthine oxidase. *J Nutr Sci Vitaminol (Tokyo).* 1986;32(6):635-42.
26. Bennett JP, Gomperts BD, Wollenweber E. Inhibitory effects of natural flavonoids on secretion from mast cells and neutrophils. *Arzneimittelforschung.* 1981;31(3):433-7.
27. Ferrándiz ML, Alcaraz MJ. Anti-inflammatory activity and inhibition of arachidonic acid metabolism by flavonoids. *Agents Actions.* 1991;32(3-4):283-8.
28. Nègre-Salvayre A, Affany A, Hariton C, Salvayre R. Additional antilipoperoxidant activities of alpha tocopherol and ascorbic acid on membrane-like systems are potentiated by rutin. *Pharmacology.* 1991;42(5):262-72.
29. Ali MM, El Kader MA. The influence of naringin on the oxidative state of rats with streptozotocin-induced acute hyperglycaemia. *Z Naturforsch C.* 2004;59(9-10):726-33.
30. Russo A, Acquaviva R, Campisi A, Sorrenti V, Di Giacomo C, Virgata G, et al. Bioflavonoids as anti-radicals, antioxidants and DNA cleavage protectors. *Cell Biol Toxicol.* 2000;16(2):91-8.
31. Dokmeci D, Kanter M, Inan M, Aydogdu N, Basaran UN, Yalcin O, et al. Protective effects of ibuprofen on testicular torsion/detorsion-induced ischemia/reperfusion injury in rats. *Arch Toxicol.* 2007;81(9):655-63.
32. Payabvash S, Salmasi AH, Kiumehr S, Tavangar SM, Nourbakhsh B, Faghihi SH, et al. Salutary effects of N-acetylcysteine on apoptotic damage in a rat model of testicular torsion. *Urol Int.* 2007;79(3):248-54.
33. Payabvash S, Salmasi AH, Kiumehr S, Tavangar SM, Nourbakhsh B, Faghihi SH, et al. Salutary effects of N-acetylcysteine on apoptotic damage in a rat model of testicular torsion. *Urol Int.* 2007;79(3):248-54.
34. Avlan D, Erdouğan K, Cimen B, Düşmez Apa D, Cinel I, Aksöyek S. The protective effect of selenium on ipsilateral and contralateral testes in testicular reperfusion injury. *Pediatr Surg Int.* 2005;21(4):274-8.