

# A Vinyl Chloride-exposed Worker with an Adrenal Gland Angiosarcoma: A Case Report

Mario CRISCUOLO<sup>1</sup>, Jacqueline VALERIO<sup>1</sup>, Maria Elena GIANICOLO<sup>3\*</sup>,  
Emilio A.L GIANICOLO<sup>4,5</sup> and Maurizio PORTALURI<sup>2,4</sup>

<sup>1</sup>Pathology Department, “Perrino” Hospital, Italy

<sup>2</sup>Radiotherapy Department, “Perrino” Hospital, Italy

<sup>3</sup>Euromediterranean Biomedical Scientific Institute (ISBEM), Italy

<sup>4</sup>National Research Council, Institute of Clinical Physiology (IFC-CNR), Italy

<sup>5</sup>Der Johannes Gutenberg-Universität, Instituts für Medizinische Biometrie, Epidemiologie und Informatik (IMBEI), Germany

Received March 1, 2013 and accepted November 21, 2013

Published online in J-STAGE December 2, 2013

**Abstract:** Adrenal epithelioidangiosarcoma (AEA) is a rare neoplasm that accounts for less than 1% of sarcomas. Due to its rarity, it can easily be misdiagnosed, both by the clinician and the pathologist. Data on the patient’s occupational history was collected and analyzed. The bibliographic data was found on the PUBMED bibliographic search site after entering the word “extrahepaticangiosarcoma”. We report a case of adrenal epithelioidangiosarcoma (AEA) in a 68 yr-old Caucasian male factory worker exposed to Vinyl Chloride (VC) for 15 yr. He underwent surgery, chemotherapy and radiotherapy. Hepatic angiosarcoma is a known consequence of VC exposure, but occupational causality of extra-hepatic angiosarcoma is controversial. Extra-hepatic angiosarcomas have been reported in VC workers, but never AEA. Cancerogenic effects of VC involve all endothelial areas of the body and extra-hepatic endothelial tumors may also be caused by this substance. This is the first published report of AEA diagnosed in a worker exposed to VC.

**Key words:** Adrenal angiosarcoma, Vinyl chloride, Extraepatic

## Introduction

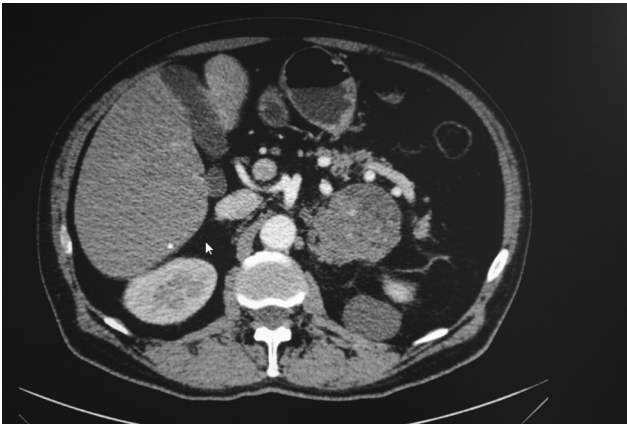
Angiosarcoma is a rare malignant tumor (less than 1% of sarcomas), mainly localized in the skin and superficial soft tissue<sup>1–3</sup>). Angiosarcomas have been reported as primary neoplasms in numerous other sites, including breast, thyroid, heart, lung, pulmonary artery, liver, spleen, kidney, adrenal gland, uterus, ovary, vagina, testis, bone, and serous membranes<sup>4–17</sup>). Etiologic factors related to angiosarcomas are exposure to arsenic<sup>18</sup>), thorium diox-

ide<sup>19–21</sup>), vinyl chloride monomers<sup>22, 23</sup>), and therapeutic irradiation<sup>24–27</sup>). Since 1974, several reports have appeared regarding a distinct relationship between exposure to vinyl chloride monomers and angiosarcomas of the liver<sup>28–34</sup>). Adrenal epithelioidangiosarcoma (AEA) is one such rare neoplasm, as reflected by its limited documentation in the literature. It is usually a very aggressive tumor, and surgery is the treatment of choice with or without adjuvant therapy, depending on the histopathological stage and subsequent prognostic factors. The most common presenting symptoms are non-specific and include slight fever, anorexia, fatigue and chronic pain, although the disease is frequently asymptomatic, as reported by Wenig *et al.*<sup>2, 35–37</sup>). Finally bibliographic evidence is presented, found on the

\*To whom correspondence should be addressed.

E-mail: elenagian@hotmail.com

©2014 National Institute of Occupational Safety and Health

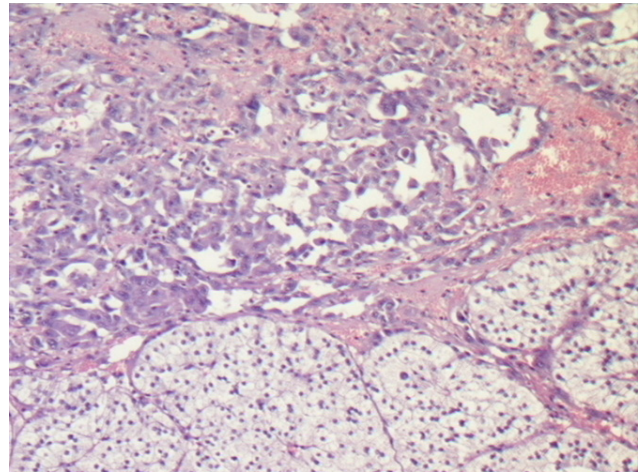


**Fig. 1.** Left suprarenal mass and metastasis near the posterior abdominal wall.

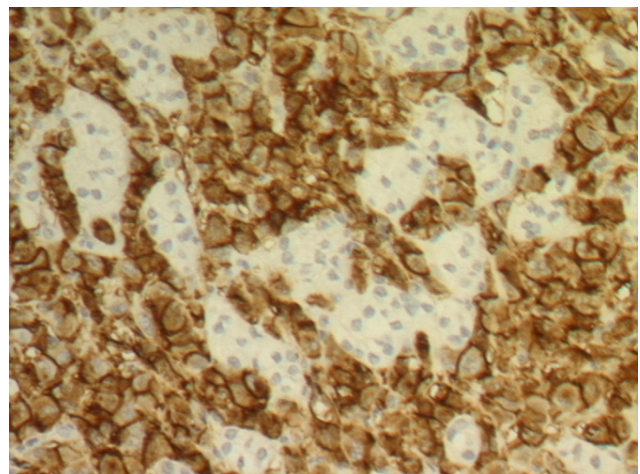
PUBMED bibliographic search site after entering the word “extrahepaticangiosarcoma”.

### Case Presentation

In April 2011, a 68 yr old Caucasian male was admitted to the surgery clinic at the General Hospital “Perrino” in Brindisi (Italy) because of a pain in the left thorax. A CT scan showed a suprarenal mass of 7 cm with intra-parenchymal calcifications and dishomogeneous enhancement in contact with the gastric wall, left renal vein and splenic vessels (Fig. 1). On April 20, the patient underwent a laparoscopic ablation of the suprarenal mass. Subsequently, in July 2011, a CT-PET showed metastatic lesions in T4 and T5 and chemotherapy with anthracyclines was started in the Oncology Clinic. In August 2011, a bone scan was required due to diffuse skeletal pain and showed vertebral and costal metastases. Radiotherapy with a single fraction of 8 Gy to the painful portion of the chest was performed. Pain control was unsuccessful since the Visual Analogue Scale score remained constant (score 7–8). The patient died of neoplastic cachexia in November 2011. The man had worked as a compressor operator from 1962–1972 at a chemical factory in southern Italy, in a storage facility with vinyl chloride (VC). In 1991, the sector management compiled a list of workers exposed to VC after 1970. On that list the man resulted exposed to >500 ppm of VC from 1970 to 1972. From 1988 to 1993, the man worked on the production of Polyvinyl Chloride (PVC) pipes from PVC waste material. The tumor was diagnosed in 2011, 39 yr after his last direct VC exposition and 18 yr after working with PVC. The tumor was surgically excised along with surrounding adipose tissue. The adrenal gland had a nodu-



**Fig. 2.** Clear cells as hyperplastic adrenal tissue (bottom) and neoplastic vascular channels (top) with malignant endothelial epithelioid cells (hematoxylin-eosin  $\times 32$ ).



**Fig. 3.** Immunohistochemical staining for CD31 antigen. Note intense brown coloration of the membrane of the endothelial neoplastic cells with residual negative adrenal tissue ( $\times 40$ ).

lar aspect and measured  $8 \times 5 \times 4.5$  cm, with a weight of 100 g. The cut surface showed a variegated aspect with hemorrhagic areas infiltrating the residual adrenal tissue, with a central zone of calcific fibrosis. Hematoxylin and eosin-stained sections of the adrenal gland revealed a neoplasm characterized by predominantly epithelioid malignant endothelial cells forming rudimentary vascular channels. These channels infiltrated the surrounding adrenal tissue, which was diffusely hyperplastic; they had an irregular shape and formed intercommunicating sinusoids with endothelial papillae (Fig. 2). Malignant epithelioid cells had abundant eosinophilic cytoplasm and high nuclear grade with vesicular nuclei and prominent

nucleoli. In some areas the neoplastic cells had a prevalent solid pattern with slit-like vascular spaces. Wide fibrosis with microcalcifications was also present. Immunohistochemically, the neoplastic cells were strongly and diffusely positive for platelet endothelial cell adhesion molecule (PECAM-1) also known as cluster of differentiation 31 (CD31) (Fig. 3), Human von Willebrand Factor (Factor VIII-related antigen) and focally positive for CKAE1AE3. Immunostains for is a cluster of differentiation molecule (CD34), Inhibin Alpha and S100 were negative.

## Discussion and Conclusion

AEA are extremely rare neoplasms. AEA must be differentiated from other neoplasms of the adrenal gland such as adrenal cortical carcinoma, pheochromocytoma, metastatic carcinoma, and metastatic malignant melanoma, but in all cases the immunohistochemical markers are a good tool for differential diagnosis. AEA is a biologically malignant neoplasm that can infiltrate locally and metastasize<sup>37</sup>. The etiology of the epithelioidangiosarcoma remains unknown. There are only four cases described in the literature where the malignancy could be linked with prolonged exposure to arsenic-containing insecticides and presence of mesenteric fibromatosis. No other connection or correlation with a family history of adrenal neoplasms (suggesting Multiple Endocrine Neoplasia syndrome), a prior history of abdominal radiotherapy or long-term androgenic anabolic steroid treatment could be found<sup>36, 38</sup>. The disease generally affects more men than women (21 men, 8 women, 1 not specified) with a wide age range from 34 to 85 yr, predominantly patients in their 60s and 70s. The disease usually starts with pain and presence of abdominal mass, followed by significant weight loss, fever episodes and weakness. In six cases described in the literature the disease was asymptomatic but in four cases it was associated with paraneoplastic syndrome and distant metastases to bone and liver<sup>38, 39</sup>. One patient had an unusual association with Cushing's disease while in one patient an adrenal tumor had accidentally been discovered<sup>40, 41</sup>. In the sixth asymptomatic patient, the angiosarcoma was revealed after surgery for abdominal trauma and suspected hepatic rupture was performed<sup>42</sup>. Rasore-Quartino and Kern published the first two cases in the late 1960s, but due to a lack of immunohistochemical analyses they are excluded from this study<sup>43, 44</sup>. The first case confirmed by immunohistochemical staining was published in 1988 by Kareti<sup>3</sup>. Several single case reports followed until Wenig *et al.* described the largest study in 1994 where nine cases

of adrenal angiosarcoma were analyzed (eight new cases plus one previously published by Karety)<sup>36, 40, 45–49</sup>. Macroscopically the tumors varied from well-circumscribed to invasive retroperitoneal masses, solid to cystic, with size from 5 to 16 cm in diameter. All the cases described in the literature tended toward an epithelioid appearance. Among them 19 had immunoreactivity for keratins while only 3 were negative<sup>35, 36, 38, 39, 42, 46, 47, 52, 54–59</sup>. Reactivity for cytokeratin is typical of epithelioid morphology and is believed to represent aberrant or “atavistic” expression. Human von Willebrand Factor (Factor VIII-related antigen) and platelet endothelial cell adhesion molecule (PECAM-1) also known as cluster of differentiation 31 (CD31) positivity was detected in 7 cases and 16 cases, respectively<sup>35, 36, 40–42, 47, 52–59</sup>. Prompt preoperative diagnosis is very complex since the tumors can appear well-circumscribed and non-contrast-enhancing, suggesting a benign, non-neoplastic formation. Their irregular histological and immunological attributes as well as their relatively low incidence can cause pathologists to mistake them for adrenal epithelial neoplasms. In clinical practice these neoplasms should always be differentiated from other vascular neoplasms, pheochromocytoma, adrenal cortical carcinoma, metastatic adenocarcinoma, metastatic malignant melanoma and other metastatic tumors as well as from benign neoplasms such as adrenal adenomas with hemorrhage and epithelioidhemangioendothelioma<sup>36, 38, 40, 50–52</sup>. The safest and easiest way to confirm or rule out this malignancy is by using immunohistochemistry. Endothelial-related markers (CD34, Factor VIII antigen and CD31) must be used in the antigen panel of these tumors, following their limitations in terms of sensitivity and specificity<sup>36</sup>. The adrenal angiosarcoma is a malignant neoplasm that can invade surrounding organs and tissue as well as metastasize in distant sites. Epithelioidangiosarcoma of the adrenal gland may mimic much more common primary and secondary tumors, and in view of cytokeratin positivity, especially metastatic carcinoma. Despite its rarity, knowledge of its existence is important as its pathobiologic characteristics may differ markedly from other primary and metastatic adrenal neoplasms. Because of the infrequency of this entity, optimal therapy other than surgical eradication is difficult to determine. The complete surgical resection of the adrenal gland with or without any surrounding tissue or organ infiltrated with the tumor has good outcome despite the biology of this tumor. Some cases may have been detected at an early enough stage to enable surgical cure. In view of the aggressive nature of angiosarcoma in all sites, adjuvant therapy appears justified for patients in whom

complete surgical extirpation cannot be ensured. Complete eradication combined with 3- to 6-month control intervals are essential for detection of presence of local recurrence or distant metastases and their treatment with adjuvant chemo- or radiotherapy. Presence of local or distant metastases at the time of the primary detection of the tumor or in the first 6 months postoperatively is a negative prognostic parameter that shortens the overall survival of the patient. This is the first published report of adrenal angiosarcoma diagnosed in a worker exposed to VC.

## References

- 1) Enzinger FM (2001) Malignant vascular tumors. In: *Soft Tissue tumors*, 4th Ed. Mosby, St. Louis.
- 2) Lack EE, Graham CW, Azumi N (1991) Primary leiomyosarcoma of the adrenal gland: case report with immunohistochemical and ultrastructural study. *Am J Surg Pathol* **15**, 899–905. [[Medline](#)]
- 3) Kareti LR, Katlein S, Siew S, Blauvelt A (1988) Angiosarcoma of the adrenal gland. *Arch Pathol Lab Med* **112**, 1163–5. [[Medline](#)]
- 4) Macías-Martínez V, Murrieta-Tiburcio L, Molina-Cardenas H, Domínguez-Malagón H (1997) Epithelioidangiosarcoma of the breast: clinicopathological, immunohistochemical, and ultrastructural study of a case. *Am J Surg Pathol* **21**, 599–604. [[Medline](#)]
- 5) Eusebi V, Carcangiu ML, Dina R, Rosai J (1990) Keratin-positive epithelioidangiosarcoma of the thyroid: a report of four cases. *Am J Surg Pathol* **14**, 737–47. [[Medline](#)]
- 6) Wakely PE Jr (1987) Angiosarcoma of the heart in an adolescent. *Arch Pathol Lab Med* **111**, 472–5. [[Medline](#)]
- 7) Sheppard MN, Hansell DM, Du Bois RM, Nicholson AG (1997) Primary epithelioidangiosarcoma of the lung presenting as pulmonary hemorrhage. *Hum Pathol* **28**, 383–5. [[Medline](#)] [[CrossRef](#)]
- 8) Goldblum JR, Rice TW (1995) Epithelioidangiosarcoma of the pulmonary artery. *Hum Pathol* **26**, 1275–7. [[Medline](#)] [[CrossRef](#)]
- 9) Popper H, Thomas LB, Telles NC, Falk H, Selikoff IJ (1978) Development of hepatic angiosarcoma in man induced by vinyl chloride, thorotrast, and arsenic: comparison with cases of unknown etiology. *Am J Pathol* **92**, 349–76. [[Medline](#)]
- 10) Falk H, Thomas LB, Popper H, Ishak KG (1979) Hepatic angiosarcoma associated with androgen-anabolic steroids. *Lancet* **2**, 1120–3. [[Medline](#)] [[CrossRef](#)]
- 11) Falk S, Krishnan J, Meis JM (1993) Primary angiosarcoma of the spleen: a clinicopathologic study of 40 cases. *Am J Surg Pathol* **17**, 959–70. [[Medline](#)]
- 12) Schammel DP, Tavassoli FA (1998) Uterine angiosarcomas: a morphologic and immunohistochemical study of four cases. *Am J Surg Pathol* **22**, 246–50. [[Medline](#)]
- 13) Nucci MR, Krausz T, Lifschitz-Mercer B, Chan JK, Fletcher CD (1998) Angiosarcoma of the ovary: clinicopathologic and immunohistochemical analysis of four cases with a broad morphologic spectrum. *Am J Surg Pathol* **22**, 620–30. [[Medline](#)]
- 14) McAdam JA, Stewart F, Reid R (1998) Vaginal epithelioidangiosarcoma. *J Clin Pathol* **51**, 928–30. [[Medline](#)]
- 15) Masera A, Ovcak Z, Mikuz G (1999) Angiosarcoma of the testis. *Virchows Arch* **434**, 351–3. [[Medline](#)] [[CrossRef](#)]
- 16) Marthya A, Patinharayil G, Puthezeth K, Sreedharan S, Kumar A, Kumaran CM (2007) Multicentric epithelioidangiosarcoma of the spine: a case report of a rare bone tumor. *Spine J* **7**, 716–9. [[Medline](#)] [[CrossRef](#)]
- 17) Lin BTY, Colby T, Gown AM, Hammar SP, Mertens RB, Churg A, Battifora H (1996) Malignant vascular tumors of the serous membranes mimicking mesothelioma: a report of 14 cases. *Am J Surg Pathol* **20**, 1431–9. [[Medline](#)]
- 18) Regelson W, Kim U, Ospina J, Holland JF (1968) Hemangioendothelial sarcoma of liver from chronic arsenic intoxication by Fowler's solution. *Cancer* **21**, 514–22. [[Medline](#)]
- 19) Ito Y, Kojiro M, Nakashima T, Mori T (1988) Pathomorphologic characteristics of 102 cases of thorotrast-related hepatocellular carcinoma, cholangiocarcinoma, and hepatic angiosarcoma. *Cancer* **62**, 1153–62. [[Medline](#)] [[CrossRef](#)]
- 20) Macmahon HE, Murphy AS, Bates MI (1947) Endothelial cell sarcoma of liver following thorotrast injections. *Am J Pathol* **23**, 585–611. [[Medline](#)]
- 21) Naka N, Ossawa M, Tomita Y, Kanno H, Uchida A, Aozasa K (1995) Angiosarcoma in Japan. A review of 99 cases. *Cancer* **75**, 989–96. [[Medline](#)] [[CrossRef](#)]
- 22) Falk H (1983) Vinyl chloride and polyvinyl chloride. In: *Environmental and occupational medicine*, Rom W (Ed.), pp 579–588, Little, Brown, Boston.
- 23) Thomas LB, Popper H, Berk P, Selikoff I, Falk H (1975) Vinyl-chloride-induced liver disease. From idiopathic portal hypertension to angiosarcomas. *N Engl J Med* **292**, 17–22. [[Medline](#)] [[CrossRef](#)]
- 24) Brady MS, Gaynor JJ, Brennan MF (1992) Radiation-associated sarcoma of bone and soft tissue. *Arch Surg* **127**, 1379–85. [[Medline](#)] [[CrossRef](#)]
- 25) Cafiero F, Gipponi M, Peressini A, Queirolo P, Bertoglio S, Comandini D, Percivale P, Sertoli MR, Badellino F (1996) Radiation associated angiosarcoma: diagnostic and therapeutic implications—two case reports and a review of the literature. *Cancer* **77**, 2496–502. [[Medline](#)] [[CrossRef](#)]
- 26) Chen KTK, Hoffman KD, Hendricks EJ (1979) Angiosarcoma following therapeutic irradiation. *Cancer* **44**, 2044–8. [[Medline](#)] [[CrossRef](#)]
- 27) Fineberg S, Rosen PP (1994) Cutaneous angiosarcoma and atypical vascular lesions of the skin and breast after radiation therapy for breast carcinoma. *Am J Clin Pathol* **102**, 757–63. [[Medline](#)]
- 28) Baxter PJ, Anthony PP, MacSween RN, Scheuer PJ (1977)

- Angiosarcoma of the liver in Great Britain, 1963–73. *BMJ* **2**, 919–21. [[Medline](#)] [[CrossRef](#)]
- 29) Creech J LJr, Johnson MN (1974) Angiosarcoma of the liver in the manufacture of polynyl chloride. *J Occup Med* **16**, 150–1. [[Medline](#)]
  - 30) Doll R (1988) Effects of exposure to vinyl chloride. An assessment of the evidence. *Scand J Work Environ Health* **14**, 61–78. [[Medline](#)] [[CrossRef](#)]
  - 31) Jones RD, Smith DM, Thomas PG (1988) A Mortality study of vinyl chloride monomer workers employed in the United Kingdom in 1940–1974. *Scand J Work Environ Health* **14**, 153–60. [[Medline](#)] [[CrossRef](#)]
  - 32) Pirastu R, Comba P, Reggiani A, Foa V, Masina A, Maltoni C (1990) Mortality from liver disease among Italian vinyl chloride monomer/polyvinyl chloride manufacturers. *Am J Ind Med* **17**, 155–61. [[Medline](#)] [[CrossRef](#)]
  - 33) Wong O, Whorton MD, Foliart DE, Ragland D (1991) An industry-wide epidemiologic study of vinyl chloride workers, 1942–1982. *Am J Ind Med* **20**, 317–34. [[Medline](#)] [[CrossRef](#)]
  - 34) Wu W, Steenland K, Brown D, Wells V, Jones J, Schulte P, Halperin W (1989) Cohort and case-control analyses of workers exposed to vinyl chloride. *J Occup Med* **31**, 518–23. [[Medline](#)] [[CrossRef](#)]
  - 35) MayayoArtal E, Gomez-Aracil V, Sole-Poblet JM, Pereira Lopez JA (2002) Epithelioidangiosarcoma of the adrenal gland. Report of a case. *Arch Esp Urol* **55**, 261–4. [[Medline](#)]
  - 36) Wenig BM, Abbondanzo SL, Heffess CS (1994) Epithelioidangiosarcoma of the adrenal gland. A clinicopathological study of nine cases with a discussion of the implication of finding epithelial specific markers. *Am J Surg Pathol* **18**, 62–73. [[Medline](#)]
  - 37) Stavridis S, Mickovski A, Filipovski V, Banev S, Dohcev S, Lekovski L, (2010) Epithelioid Angiosarcoma of the Adrenal Gland. Report of a case and Rewiew of the Literature. *Macedonian Journal of Medical Sciences* **3**, 388–94.
  - 38) Jochum W, Schroder S, Risti B, Marincek B, von Hochstetter A (1994) Cytokeratin-positive angiosarcoma of the adrenal gland. *Pathologe* **15**, 181–6. [[Medline](#)] [[CrossRef](#)]
  - 39) Bosco PJ, Silverman ML, Zinman LM (1991) Primary angiosarcoma of adrenal gland presenting as paraneoplastic syndrome: case report. *J Urol* **146**, 1101–3. [[Medline](#)]
  - 40) Croitoru AG, Klausner AP, Mc Williams G, Unger PD (2001) Primary epithelioidangiosarcoma of the adrenal gland. *Ann Diagn Pathol* **5**, 300–303. [[Medline](#)]
  - 41) Ferrozzi F, Tognini G, Bova D, Zuccoli G, Pavone P (2001) Hemangiosarcoma of the adrenal glands: CT findings in two cases. *Abdom Imaging* **26**, 336–9. [[Medline](#)]
  - 42) Gambino G, Mannone T, Rizzo A Scio A, Branca M, Airò Farulla M, Guccione M, Spallitta IS, Nicoli N (2008) Adrenalepithelioid angiosarcoma: a case report. *Chir Ital* **60**, 463–7. [[Medline](#)]
  - 43) Rasore-Quartino A (1967) Congenitaladrenaltumor (angiosarcoma) in a monozygotic twin. *Pathologica* **59**, 153–8. [[Medline](#)]
  - 44) Kern WH, Smart RD, Sherwin RP (1967) Angiosarcoma of lungs and adrenal gland: unusual clinical and pathologic manifestations. *Minn Med* **50**, 1339–43. [[Medline](#)]
  - 45) Caplan RH, Kiskan WA, Huiras CM (1991) Incidentally discovered adrenal masses. *Minn Med* **74**, 23–6. [[Medline](#)]
  - 46) Livaditou A, Alexiou G, Floros D, Filippidis T, Dosios T, Bays D (1991) Epithelioid angiosarcoma of the adrenal gland associated with cronic arsenic intoxication? *Pathol Res Pract* **187**, 284–9. [[Medline](#)] [[CrossRef](#)]
  - 47) Ben-Izhak O, Auslander L, Rabinson S, Lichtig C, Sternberg A (1992) Epithelioidangiosarcoma of the adrenal gland with cytokeratin expression. Report of a case with accompanying mesenteric fibromatosis. *Cancer* **69**, 1808–12. [[Medline](#)] [[CrossRef](#)]
  - 48) Fiordelise S, Zangrandi A, Tronci A, Rovereto B, Valentino RV, Bezzi E (1992) Angiosarcoma of the adrenal gland: case report. *Arch Ital Urol Nefrol Androl* **64**, 341–3. [[Medline](#)]
  - 49) Schwenk W, Sarbia M, Haas R, Stock W (1994) Primary hemangiosarcoma as a rare form of an incidentally discovered mass of the adrenal glands. *Dtsch Med Wochenschr* **119**, 217–21. [[Medline](#)] [[CrossRef](#)]
  - 50) McCleary AJ (1994) Massive haemothorax secondary to angiosarcoma. *Thorax* **49**, 1036–7. [[Medline](#)] [[CrossRef](#)]
  - 51) Sasaki R, Tachiki Y, Tsukada T, Miura K, Kato T, Saito K (1995) A case of adrenal angiosarcoma. *Nippon Hinyokika Gakkai Zasshi* **86**, 1064–7 (in Japanese). [[Medline](#)]
  - 52) Abboud E, Weisenberg E, Khan S, Rhone DP (1999) Pathologic quiz case. *Arch Pathol Lab Med* **123**, 157–8. [[Medline](#)]
  - 53) Invitti C, PecoriGiraldi F, Cavagnini F, Sonzogni A (2001) Unusual association of adrenal angiosarcoma and Cushing's disease. *Horm Res* **56**, 124–9. [[Medline](#)] [[CrossRef](#)]
  - 54) Krüger S, Kujath P, Johannisson R, Feller AC (2001) Primary epithelioidangiosarcoma of the adrenal gland. Case report and review of the literature. *Tumori* **87**, 262–5. [[Medline](#)]
  - 55) Rodríguez-Pinilla SM, Benito-Berlinches A, Ballestin C, Usera G (2002) Angiosarcoma of adrenal gland report of a case and review of the literature. *Rev Esp Patol* **352**, 227–32.
  - 56) Pasqual E, Bertolissi F, Grimaldi F, Beltrami CA, Scott CA, Bacchetti S, Waclaw BU, Cagol PP (2002) Adrenal angiosarcoma: report of a case. *Surg Today* **32**, 563–5. [[Medline](#)]
  - 57) Sidoni A, Magro G, Cavaliere A, Scheibel M, Bellezza G (2003) Primaryadrenal angiosarcoma. *Pathologica* **95**, 60–3. [[Medline](#)]
  - 58) Galmiche L, Morel HP, Moreau A, Labrosse PA, Coindre JM, Heymann MF (2004) Primaryadrenal angiosarcoma. *Ann Pathol* **24**, 371–3. [[Medline](#)]
  - 59) Azurmendi Sastre V, Llarena Ibarguren R, Eizaguirre Zarza B, Pertusa Peña C (2004) Adrenalspindlecell angiosarcoma. Report of one case. *Arch Esp Urol* **57**, 156–60. [[Medline](#)]