

Contents lists available at [ScienceDirect](https://www.sciencedirect.com)

## International Journal of Surgery Case Reports

journal homepage: [www.casereports.com](http://www.casereports.com)

## Small bowel obstruction after laparoscopic gastrectomy: An atypical clinical presentation. Report of a case

Giuseppe Di Buono\*, Federica Ricupati, Salvatore Buscemi, Giulia Bonventre, Giorgio Romano, Antonino Agrusa

Department of Surgical, Oncological and Oral Sciences, Section of General and Urgent Surgery, University of Palermo, Italy

### ARTICLE INFO

#### Article history:

Received 1 July 2020

Received in revised form 27 July 2020

Accepted 27 July 2020

Available online 25 August 2020

#### Keywords:

Postoperative adhesions

Adhesiolysis

Laparoscopic gastrectomy

Small bowel obstruction

Laparoscopy

### ABSTRACT

**INTRODUCTION:** Postoperative adhesions represent the most common cause of acute small bowel obstruction (80%) and are usually a consequence of abdomino-pelvic surgery performed with open technique.

**PRESENTATION OF CASE:** A 45-year-old black man arrived at the emergency room with abdominal pain and distension three months after laparoscopic distal gastrectomy with Roux-en-Y anastomosis performed for benign pyloric stenosis. CT abdominal scan revealed some air-fluid levels in the center of the abdomen with distension of proximal jejunal loops caused by intestinal adhesions. Laparoscopic adhesiolysis was performed to restore the intestinal transit.

**DISCUSSION:** The formation of adhesions is more frequent after abdomino-pelvic surgery. CT abdominal scan is very useful tool to identify the level and the aetiology of obstruction and it may predict the need for surgery, the location of different adhesive bands in order to identify which patients are likely candidates for laparoscopic treatment.

**CONCLUSION:** In selected cases, laparoscopic approach for small bowel obstruction is a good surgical option. In patients with abdominal dense adhesions or clinical signs of intestinal ischemia, conversion to laparotomy should be considered an alternative.

© 2020 Published by Elsevier Ltd on behalf of IJS Publishing Group Ltd. This is an open access article under the CC BY-NC-ND license (<http://creativecommons.org/licenses/by-nc-nd/4.0/>).

### 1. Introduction

Adhesive small bowel obstruction (ASBO) is one of the main causes of surgical emergency with significant morbidity and even some mortality [1]. Postoperative adhesions represent the most common cause of acute small bowel obstruction (80%) [2], are typically a consequence of peritoneal irritation and are formed mainly following abdominal or pelvic surgery performed with the open technique. The definitive diagnosis confirmation of the adhesive etiology of bowel obstruction is made during surgical procedure. In this article, we report an atypical case of small bowel obstruction after laparoscopic distal gastrectomy caused by adhesion phenomena on a jejunal loop in line with the SCARE criteria [3,4].

### 2. Case report

A 45-year-old black man arrived at the emergency room with abdominal pain and distension three months after laparoscopic distal gastrectomy with Roux-en-Y anastomosis performed for benign pyloric stenosis. In that previous surgery we performed an intracorporeal, side to side, trans-mesocolic gastro-jejunal anastomosis using a blue-load stapler (Echelon Flex™ GST; Ethicon Endo-Surgery, USA) and an intracorporeal, side to side jejunal-jejunal anastomosis using a white-load stapler (Echelon Flex™ GST). The continence of the gastro-jejunal anastomosis was assessed by the administration of methylene blue from the naso-gastric tube (NGT) with no evidence of leakage. Our patient had no postoperative complications and was discharged on postoperative day (POD) 7. Three months later, he came to our attention with nausea and vomiting for 3 days with no evacuation of faeces. He had no other systemic symptoms or comorbidity and his family history was negative for other diseases. On arrival WBC count and C-reactive protein values were in normal range. A contrast-enhanced CT abdominal scan revealed multiple air-fluid levels with distension of some proximal jejunal loops. On clinical observation the patient was hemodynamically stable and there were no signs of necrosis on CT scan and on blood tests, so we decided to attempt a conservative management with fluid and electrolyte administration and nasogastric decompression. We also dispensed via NGT methylglucamine diatrizoate (Gastrografin®), an hyperosmolar fluid typically

\* Corresponding author at: Department of Surgical, Oncological and Oral Sciences (Di.Chir.On.S.), University of Palermo - Italy, Via L. Giuffrè, 5, 90127, Palermo, Italy.

E-mail addresses: [giuseppe.dibuono@unipa.it](mailto:giuseppe.dibuono@unipa.it)

(G. Di Buono), [fede.ricup90@gmail.com](mailto:fede.ricup90@gmail.com) (F. Ricupati), [buscemi.salvatore@gmail.com](mailto:buscemi.salvatore@gmail.com) (S. Buscemi), [giulia.bonv@gmail.com](mailto:giulia.bonv@gmail.com) (G. Bonventre), [giorgio.romano@unipa.it](mailto:giorgio.romano@unipa.it) (G. Romano), [antonino.agrusa@unipa.it](mailto:antonino.agrusa@unipa.it) (A. Agrusa).

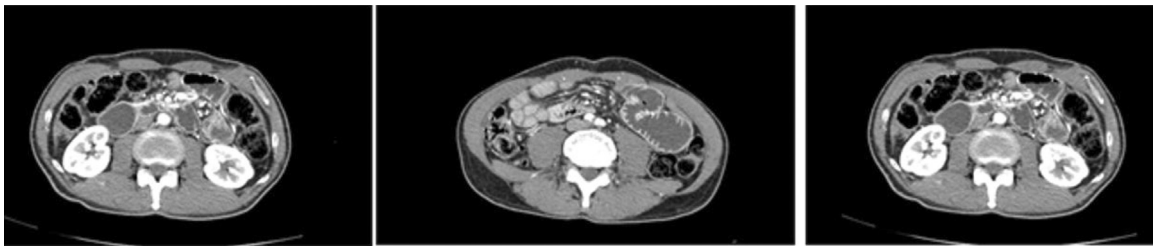


Fig. 1. A contrast-enhanced CT abdominal scan revealed some air-fluid levels in the center of the abdomen with distension of some proximal jejunal loops.

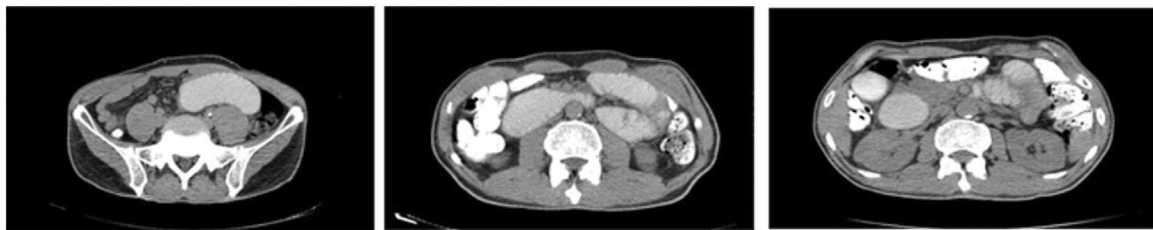

Fig. 2. CT abdominal scan after administration of Gastrografin revealed an increase of air-fluid levels.

used in gastrointestinal radiology. After 48 h we repeated an abdominal CT scan with no therapeutic benefit of conservative management and increased air-fluid levels related to a local inflammatory/aedematous state. Considering the hemodynamic stability of the patient and the absence of previous laparotomies, we chose a laparoscopic approach with possible conversion to open surgery in presence of excessive intestinal distension and an inadequate laparoscopic working space. The procedure was performed by a senior resident with an equipe experienced in laparoscopic surgery. We induced pneumoperitoneum with trans-umbilical Hasson technique and we used a laparoscopic 3D vision system [5,6]. We placed other two 5-mm trocars respectively in right and left flank. On initial laparoscopic surgical exploration we identified several adhesions between the small bowel loop and the abdominal wall. Continuing the exploration we found the angulation of a jejunal loop located 40 cm from Roux-en-Y anastomosis due to an adhesive band on trans-mesocolic passage point of the jejunal loop, responsible for the occlusive syndrome. Given the absence of signs of intestinal ischemia, we performed an adequate adhesiolysis with the restoration of the intestinal transit. The patient also underwent an intraoperative endoscopy to exclude the presence of bleeding, endoluminal obstruction or unknown anastomosis leakage. No other macroscopically evident lesions were observed in the peritoneal organs explored. The patient was satisfied with the treatment received for the rapid postoperative recovery and advantages of laparoscopic surgery; he had no postoperative complications and was discharged on POD 3 with indication to liquid semi liquid diet for two weeks (Figs. 1 and 2).

### 3. Discussion

The existence of a relationship between postoperative adhesions and intestinal obstruction dates back to 1872, when Briant for the first time described a fatal case of intestinal obstruction caused by intra-abdominal adhesions developed after the removal of an ovarian tumor [7]. Despite the advancements achieved with laparoscopy, abdominal adhesions still remain the most frequent cause of mechanical intestinal obstruction (60–70% of cases) [8,9]. They can be defined as abnormal fibrous bands between two or more viscera or between viscera and abdominal wall, normally separated, consequent to postoperative inflammation [10,11]. Most

of them are formed following an abdomino-pelvic surgical procedure performed with open technique; less frequent causes are represented by inflammatory conditions such as Crohn's disease, intraperitoneal infections or abdominal trauma [12]. The interval between laparotomy and the onset of adhesion syndrome is quite variable with an average time around 6 years. The extent of adhesions formation changes from one patient to another and depends on the type and entity of surgery and the development of any postoperative complications. It is estimated that the formation of adhesions is more frequent after open colorectal surgery [13], appendectomy [14,15] and pelvic surgery [16,17]. However, upper GI surgery can also lead to its formation. Inaba et al. report that patients undergoing to gastrectomy are at a high risk of developing intestinal obstruction (incidence 11.7–38.5%) [18]. In these cases a central role seems to have the omentum. In a retrospective study reported by Fujita et al., the preservation of the greater omentum in patients with T2 or T3 gastric cancer underwent to a curative gastrectomy, reduces the formation of intestinal adhesions and therefore the incidence of small bowel obstruction [19]. In literature we find only few cases of postoperative small bowel obstruction (SMO) in patients undergoing gastrectomy. In 2010 Masaru et al. published a retrospective study on an unusual cause of SBO: afferent loop obstruction in patients underwent distal gastrectomy followed by Roux-en-Y reconstruction with open technique. In particular, the causes of the afferent loop obstruction were internal herniation in two patients, adhesions formation in one patient and peritoneal tumor recurrence in one patient [20]. In 2017 Sung Ho Jang et al. described a rare case of SBO after total laparoscopic distal gastrectomy performed using V-Loc barbed absorbable suture for anastomosis. In this case, occlusive syndrome was due to internal herniation of the proximal jejunal loop through the space created by V-Loc suture after jejunojunctionostomy [21]. The diagnosis of SBO is based on the presence of some typical symptoms such as abdominal pain, nausea, vomiting, distention and constipation (absence of defecation or flatus within the previous 24 h). However, some of them can be not always present, mainly in the elderly [22]. Clinical history is the most important approach because allows to assess potential causes of bowel obstruction (previous surgery, radiotherapy, inflammatory bowel disease). During physical examination signs of peritonitis and the possible presence of hernias of the abdom-

inal wall must be considered. The clinical observation is followed by a series of radiological tests necessary to confirm the diagnosis and to study its severity and evolution. The first radiological examination that is performed to confirm the presence of SBO is an abdominal X-ray. However, X-ray is often unable to give more accurate information about the cause and the exact location of the occlusion as well as on early signs of peritonitis or strangulation [23]. Over the past decade, small bowel X-ray series using water-soluble contrast agents became particularly important and acquired a diagnostic and therapeutic role [24]. Today, CT abdominal scan, especially with administration of oral or intravenous contrast medium, is the first line imaging modality. It's very useful to identify the level and the aetiology of SBO and may predict the need for surgery. Also, because it can distinguish the different adhesive bands, allows us to select patients candidates for laparoscopic treatment [25]. Ultrasound and MRI can be useful in specific situations, such as pregnancy or when CT scan is unavailable. Except for clinical evidence of an acute abdomen, the treatment of the patient with SBO due to adhesions is initially medical. Rehydration, fasting and placement of NGT are approximately effective in 70–90% of patients [26]. The administration of Gastrografin®, an hyperosmolar fluid used in gastrointestinal radiology, has a diagnostic and therapeutic effect in those patients who show no signs of ischemia [27]. Duration of non-operative management is subject to a strong debate. It should not extend beyond 3–5 days even in the absence of clinical deterioration [28]. Many authors consider a 72-h observation period as safe and appropriate. Teixeira et al. reported that surgery after 72 h increases mortality and systemic infectious complications three times compared to surgery performed within 24 h after presentation [29]. Schraufnagel et al. report an higher complications rate and an increased mortality when surgical procedures are performed after 4 days in patients with SBO [30]. The treatment of a refractory SBO due to adhesion syndrome is exclusively surgical. In past years, the treatment of choice for adhesive small bowel obstruction was abdominal exploration through laparotomy. However, the new incision of the abdomen once again triggered the pathophysiological mechanism responsible for the formation of the adhesions and them recurred in 80% of cases with renewed pain symptoms. In some studies a correlation has also been demonstrated between laparotomy size and formation of new adhesions [31]. The first laparoscopic adhesiolysis dates back to 1991 and today represent the surgical gold standard [32]. In a recent systematic review and meta-analysis of 14 non-randomized studies, laparoscopic approach shows a reduction in overall morbidity and a better postoperative outcome with the reappearance of postoperative adhesions only in 20% of cases [33]. Laparoscopic approach can only be practiced in selected cases. It should not be performed in hemodynamically unstable patients with an acute abdomen and in presence of abdominal dense adhesions. Conversely, it is safe and effective in patients with single adhesions, simple enteral angulation without need for resection [34]. Farinella et al. reported that laparoscopic success depends on: early treatment ( $\leq 24$  h from onset of symptoms), maximum two previous laparotomies, single band adhesion as cause of small bowel obstruction and no signs of peritonitis [35]. Excessive intestinal distension and hemodynamic instability during pneumoperitoneum induction are possible events that justify the conversion to open surgery. The conversion rate, in some cases, reaches values around 50% of all procedures [36]. The factor that most influences this incidence is the presence of intestinal ischemia.

#### 4. Conclusions

SBO develops rarely after laparoscopic upper GI surgery and we reported a rare case. In selected cases, laparoscopic approach

for SBO is associated with better postoperative outcomes, shorter hospitalization and a decreased in postoperative adhesions formation. An early treatment increases the probability of success. Laparotomy represents a risk factor in the management of adhesive small bowel obstruction for developing of new episodes and does not seem to be the best treatment. In patients with abdominal dense adhesions or clinical signs of intestinal ischemia, conversion to laparotomy should be considered. In patients with previous laparoscopic surgery it is appropriate to perform a re-laparoscopic approach because it has a higher success rate [37].

#### Declaration of Competing Interest

Di Buono Giuseppe and other co-authors have no conflict of interest.

#### Funding

Di Buono Giuseppe and other co-authors have no study sponsor.

#### Ethical approval

Ethical Approval was not necessary for this study. We obtained written patient consent to publication.

#### Consent

Written informed consent was obtained from the patient for publication of this case report and accompanying images. A copy of the written consent is available for review by the Editor-in-Chief of this journal on request.

#### Author contribution

Di Buono Giuseppe: study design, data collections, data analysis and writing.

Ricupati Federica: study design, data collections, data analysis and writing.

Buscemi Salvatore: data collections.

Bonventre Giulia: data collections.

Romano Giorgio: study design, data collections, data analysis and writing.

Agrusa Antonino: study design, data collections, data analysis and writing.

#### Registration of research studies

Not applicable.

#### Guarantor

Di Buono Giuseppe.

Agrusa Antonino.

#### Availability of data and materials

The datasets used and/or analysed during the current study are available from the corresponding author on reasonable request.

#### Acknowledgements

This article is part of a supplement entitled Case reports from Italian young surgeons, published with support from the Department of Surgical, Oncological and Oral Sciences – University of Palermo.

## References

- [1] R.P. Ten Broek, Y. Issa, E.J. van Santbrink, N.D. Bouvy, R.F. Kruitwagen, J. Jeekel, et al., Burden of adhesions in abdominal and pelvic surgery: systematic review and meta-analysis, *BMJ* 347 (2013) f5588, <http://dx.doi.org/10.1136/bmj.f5588>.
- [2] C.N. Gutt, T. Oniu, P. Schemmer, A. Mehrabi, M.W. Buchler, Fewer adhesions induced by laparoscopic surgery? *Surg. Endosc.* 18 (2004) 1202–1207, <http://dx.doi.org/10.1007/s00464-004-0056>.
- [3] R.A. Agha, A.J. Fowler, A. Saetta, I. Barai, S. Rajmohan, D.P. Orgill, for the SCARE Group, The SCARE statement: consensus-based surgical case report guidelines, *Int. J. Surg.* 34 (2016) 180–186.
- [4] R.A. Agha, M.R. Borrelli, R. Farwana, K. Koshy, A. Fowler, D.P. Orgill, For the SCARE Group, The SCARE 2018 statement: updating consensus surgical Case Report (SCARE) guidelines, *Int. J. Surg.* 60 (2018) 132–136.
- [5] A. Agrusa, G. Di Buono, S. Buscemi, G. Cucinella, G. Romano, G. Gulotta, 3D laparoscopic surgery: a prospective clinical trial, *Oncotarget* 9 (April (25)) (2018) 17325–17333, <http://dx.doi.org/10.18632/oncotarget.24669>, eCollection 2018 Apr 3.
- [6] A. Agrusa, G. Romano, G. Cucinella, G. Cocorullo, S. Bonventre, G. Salamone, G. Di Buono, G. De Vita, G. Frazzetta, D. Chianetta, V. Sorce, G. Bellanca, G. Gulotta, Laparoscopic, three-port and SILS cholecystectomy: a retrospective study, *G. Chir.* 34 (September–October (9–10)) (2013) 249–253.
- [7] T. Bryant, Clinical lectures on intestinal obstruction, *Med. Times Gaz.* 1 (1872) 363–365.
- [8] M.C. Parker, H. Ellis, B.J. Moran, J.N. Thompson, M.S. Wilson, D. Menzies, A. McGuire, A.M. Lower, R.J.S. Hawthorn, F. O'Brien, S. Buchan, A.M. Crowe, Postoperative adhesions, *Dis. Colon Rectum* 44 (6) (2001) 822–829.
- [9] G. Miller, J. Boman, I. Shrier, P.H. Gordon, Etiology of small bowel obstruction, *Am. J. Surg.* 180 (1) (2000) 33–36.
- [10] W.W. Vrijland, J. Jeekel, H.J. van Geldorp, et al., Abdominal adhesions: intestinal obstruction, pain, and infertility, *Surg. Endosc.* 17 (2003) 1017–1022.
- [11] W.W. Vrijland, L.N. Tseng, H.J. Eijkman, et al., Fewer intraperitoneal adhesions with use of hyaluronic acid-carboxymethylcellulose membrane: a randomized clinical trial, *Ann. Surg.* 235 (2002) 193–199.
- [12] F.R. Dijkstra, M. Nieuwenhuijzen, M.M. Reijnen, et al., Recent clinical developments in pathophysiology, epidemiology, diagnosis and treatment of intra-abdominal adhesions, *Scand. J. Gastroenterol. Suppl.* 232 (2000) 52–59.
- [13] D.E. Beck, F.G. Opelka, H.R. Bailey, et al., Incidence of small-bowel obstruction and adhesiolysis after open colorectal and general surgery, *Dis. Colon Rectum* 42 (1999) 241–248.
- [14] R.I. Zbar, W.B. Crede, C.F. McKhann, et al., The postoperative incidence of small bowel obstruction following standard, open appendectomy and cholecystectomy: a six-year retrospective cohort study at Yale-New Haven Hospital, *Conn. Med.* 57 (1993) 123–127.
- [15] A. Agrusa, G. Romano, G. Di Buono, G. Frazzetta, D. Chianetta, V. Sorce, V. Billone, G. Cucinella, G. Gulotta, Acute appendicitis and endometriosis: retrospective analysis in emergency setting, *GIOG* 35 (2013) 728–732.
- [16] G. Cucinella, S. Rotolo, G. Calagna, R. Granese, A. Agrusa, A. Perino, Laparoscopic management of interstitial pregnancy: the “purse-string” technique, *Acta Obstet. Gynecol. Scand.* 91 (August (8)) (2012) 996–999, <http://dx.doi.org/10.1111/j.1600-0412.2012.01437.x>, Epub 2012 Jun 1.
- [17] G. Cucinella, A. Perino, G. Romano, G. Di Buono, G. Calagna, V. Sorce, L. Gulotta, M. Triolo, V. Billone, G. Gulotta, A. Agrusa, Endometrial cancer: robotic versus laparoscopic treatment. Preliminary report, *GIOG* 37 (November–December (6)) (2015), 283–273.
- [18] T. Inaba, K. Okinaga, R. Fukushima, H. Iinuma, T. Ogihara, F. Ogawa, et al., Prospective randomized study of two laparotomy incisions for gastrectomy: midline incision versus transverse incision, *Gastric Cancer* 7 (2004) 167–171.
- [19] J. Fujita, Y. Tsukahara, K. Ikeda, K. Akagi, K. Kan, S. Hata, et al., Evaluation of omentum preserving gastrectomy for advanced gastric cancer (in Japanese with English abstract), *Jpn. J. Gastroenterol.* 36 (2003) 1151–1158.
- [20] M. Aoki, M. Saka, S. Morita, T. Fukagawa, H. Katai, Afferent loop obstruction after distal gastrectomy with Roux-en-Y reconstruction, *World J. Surg.* 34 (10) (2010) 2389–2392, <http://dx.doi.org/10.1007/s00268-010-0602-5>.
- [21] Sung Ho Jang, Yun Kyung Jung, Sungji Choi, Tae Kyung Ha, Postoperative mechanical small bowel obstruction induced by V-Loc barbed absorbable suture after laparoscopic distal gastrectomy, *Ann. Surg. Treat. Res.* 92 (May (5)) (2017) 380–382.
- [22] H. Laurell, L.E. Hansson, U. Gunnarsson, Acute abdominal pain among elderly patients, *Gerontology* 52 (6) (2006) 339–344.
- [23] T. Loftus, F. Moore, E. VanZant, T. Bala, S. Brakenridge, C. Croft, et al., A protocol for the management of adhesive small bowel obstruction, *J. Trauma Acute Care Surg.* 78 (1) (2015) 13–19.
- [24] M. Ceresoli, F. Coccolini, F. Catena, et al., Water-soluble contrast agent in adhesive small bowel obstruction: a systematic review and meta-analysis of diagnostic and therapeutic value, *Am. J. Surg.* 211 (6) (2016) 1114–1125, <http://dx.doi.org/10.1016/j.amjsurg.2015.06.012>.
- [25] R.J. Nauta, Advanced abdominal imaging is not required to exclude strangulation if complete small bowel obstructions undergo prompt laparotomy, *J. Am. Coll. Surg.* 200 (6) (2005) 904–911, <http://dx.doi.org/10.1016/j.jamcollsurg.2004.12.027>.
- [26] M.Z. Fazel, R.W. Jamieson, C.J. Watson, Long-term follow-up of the use of the Jones' intestinal tube in adhesive small bowel obstruction, *Ann. R. Coll. Surg. Engl.* 91 (1) (2009) 50–54.
- [27] B.C. Branco, G. Barmparas, B. Schnüriger, K. Inaba, L.S. Chan, D. Demetriades, Systematic review and meta-analysis of the diagnostic and therapeutic role of water-soluble contrast agent in adhesive small bowel obstruction, *Br. J. Surg.* 97 (4) (2010) 470–478, <http://dx.doi.org/10.1002/bjs.7019>.
- [28] A.A. Maung, D.C. Johnson, G.L. Piper, R.R. Barbosa, S.E. Rowell, F. Bokhari, J.N. Collins, J.R. Gordon, J.H. Ra, A.J. Kerwin, Evaluation and management of small-bowel obstruction, *J. Trauma Acute Care Surg.* (2020).
- [29] P.G. Teixeira, E. Karamanos, P. Talving, K. Inaba, L. Lam, D. Demetriades, Early operation is associated with a survival benefit for patients with adhesive bowel obstruction, *Ann. Surg.* 258 (3) (2013) 459–465.
- [30] D. Schraufnagel, S. Rajaei, F.H. Millham, How many sunsets Timing of surgery in adhesive small bowel obstruction, *J. Trauma Acute Care Surg.* 74 (1) (2013) 181–189.
- [31] D.E. Beck, F.G. Opelka, H.R. Bailey, S.M. Rauh, C.L. Pashos, Incidence of small bowel obstruction and adhesiolysis after open colorectal and general surgery, *Dis. Colon Rectum* 42 (1999) 241–248.
- [32] D.F. Bastug, S.W. Trammell, J.P. Boland, E.P. Mantz, E.H. Tiley, Laparoscopic adhesiolysis for small bowel obstruction, *Surg. Laparosc. Endosc.* 1 (1991) 259–262.
- [33] S. Farid, A. Iqbal, Z. Gechev, Adhesive intestinal obstruction in laparoscopic versus open colorectal resection, *Colorectal Dis.* (April (15)) (2013), <http://dx.doi.org/10.1111/codi.12247>.
- [34] S. Yao, E. Tanaka, A. Ikeda, T. Murakami, T. Okumoto, T. Harada, Outcomes of laparoscopic management of acute small bowel obstruction: a 7-year experience of 110 consecutive cases with various etiologies, *Surg. Today* 47 (4) (2017) 432–439.
- [35] E. Farinella, R. Cirocchi, F. La Mura, U. Morelli, L. Cattorini, P. Delmonaco, C. Migliaccio, A.A. De Sol, L. Cozzaglio, F. Sciannameo, Feasibility of laparoscopy for small bowel obstruction, *World J. Emerg. Surg.* 4 (1) (2009) 3, <http://dx.doi.org/10.1186/1749-7922-4-3>.
- [36] J.J. Duron, N. Jourdan-Da Silva, S. Tezenas du Montcel, A. Berger, F. Muscari, H. Hennes, M. Veyrieres, J.M. Hay, Adhesive postoperative small bowel obstruction: incidence and risk factors of recurrence after surgical treatment. A multicenter prospective study, *Ann. Surg.* 244 (2006) 750–757.
- [37] A. Agrusa, G. Frazzetta, D. Chianetta, S. Di Giovanni, L. Gulotta, G. Di Buono, V. Sorce, G. Romano, G. Gulotta, “Relaparoscopic” management of surgical complications: The experience of an Emergency Center, *Surg. Endosc.* 30 (2016) 2804–2810.

## Open Access

This article is published Open Access at [sciencedirect.com](https://www.sciencedirect.com). It is distributed under the [IJSCR Supplemental terms and conditions](#), which permits unrestricted non commercial use, distribution, and reproduction in any medium, provided the original authors and source are credited.