

Functional medicine

Chronic recurrent priapism: A high flow state secondary to an arteriovenous fistula of the corpus cavernosum

Catherine M. Fiore^a, Melissa L. Pellegrino^b, Meghna C. Trivedi^{b,*}^a Department of Medicine, University of Massachusetts Medical School, 55 Lake Ave North, Worcester, MA, 01655, USA^b Division of Hospital Medicine, Department of Medicine, University of Massachusetts Medical School, 55 Lake Ave North, Worcester, MA, 01655, USA

ARTICLE INFO

Keywords:

Priapism
Non-ischemic
Embolization

ABSTRACT

Priapism is clinically defined as an erect penis for more than 4 h unrelated to sexual stimulation. There are two main types of priapism-high flow and low flow, based on the pathophysiology. In this case report we will mainly focus on high flow, non-ischemic priapism, which is the less common form. High flow priapism occurs secondary to congenital malformation or from the development of arteriovenous malformation from genital trauma. This case highlights the importance of differentiation and recognition of posttraumatic high flow priapism and unveils the role of selective internal pudendal artery angiography and embolization in its management.

Introduction

Priapism is a condition in which the penis is erect for a period of more than 4 hours that is unrelated to sexual stimulation. Epidemiological studies have seen the incidence of priapism to be between 0.3 and 1.0 per 100,000 males per year.¹ It is categorized as ischemic (low flow) priapism and non-ischemic (high flow) priapism. Similar to compartment syndrome, there is no or minimal blood flow to the penis in ischemic priapism which causes pain and rigidity.² Ischemic priapism is a medical emergency and needs emergent urologic attention to prevent necrosis and erectile dysfunction. Ischemic priapism accounts for 95% of cases.² This is usually caused by blood disorders like sickle cell anemia and leukemia; and medications like phosphodiesterase 5 inhibitors, anti-depressants, alpha blockers, antipsychotics, testosterone etc. Less commonly observed in the clinical setting is non-ischemic priapism. In this scenario there is excess arterial blood flow into the corpus cavernosum. Although this condition may be uncomfortable and disturbing for the patient there is no concern for ischemia as arterial blood is oxygenated. High flow non-ischemic priapism is typically caused by congenital malformation or can arise as a delayed manifestation of genital trauma secondary to formation of arteriovenous malformations.

It is imperative to distinguish between the two forms of priapism due to the emergent nature of ischemic priapism and the high risk for ischemia. A diagnosis can be made with a cavernous blood gas sampling.

A pH below 7.25 indicates an ischemic condition whereas pH above 7.25 and oxygen level above 60 mmHg indicates non-ischemic priapism.³ A low pH occurs in ischemic priapism as oxygen is consumed as acidic byproducts build up in the blood due to anaerobic metabolism. The pH will remain in the normal range in high flow priapism due to the continued flow of arterial blood. A physical exam finding that can help differentiation is perineal compression also known as the “compression sign”. Upon compression one can obstruct the arterio-corporal fistula leading to the cessation of the erection demonstrating high flow priapism.¹ Further evaluation can include doppler ultrasonography which could show a lack of a cavernosal arterial pulse indicating low flow ischemic priapism.

Case presentation

A 37-year-old Hispanic male presented to the emergency department with an episode of painful priapism. He had a history of a car accident in 2005 which resulted in spinal injury, details of which were not available for review. Since then, he has had more than 20 recurrent episodes of priapism. He reported having multiple phenylephrine injections, aspirations and two shunt procedures performed in the past without improvement in symptoms. Exam revealed an erect but not completely rigid penis. Venous blood gas from the corpus cavernosum showed pH of 7.37 indicating high flow (non-ischemic) priapism. He received 2 doses of phenylephrine, 1 dose of terbutaline and a penile aspiration with little

* Corresponding author.

E-mail addresses: Catherine.fiore@umassmemorial.org (C.M. Fiore), Melissa.pellegrino@umassmemorial.org (M.L. Pellegrino), Meghna.trivedi@umassmemorial.org (M.C. Trivedi).<https://doi.org/10.1016/j.eucr.2019.101068>

Received 14 October 2019; Received in revised form 28 October 2019; Accepted 1 November 2019

Available online 1 November 2019

2214-4420/© 2019 The Authors.

Published by Elsevier Inc.

This is an open access article under the CC BY-NC-ND license

<http://creativecommons.org/licenses/by-nc-nd/4.0/>.

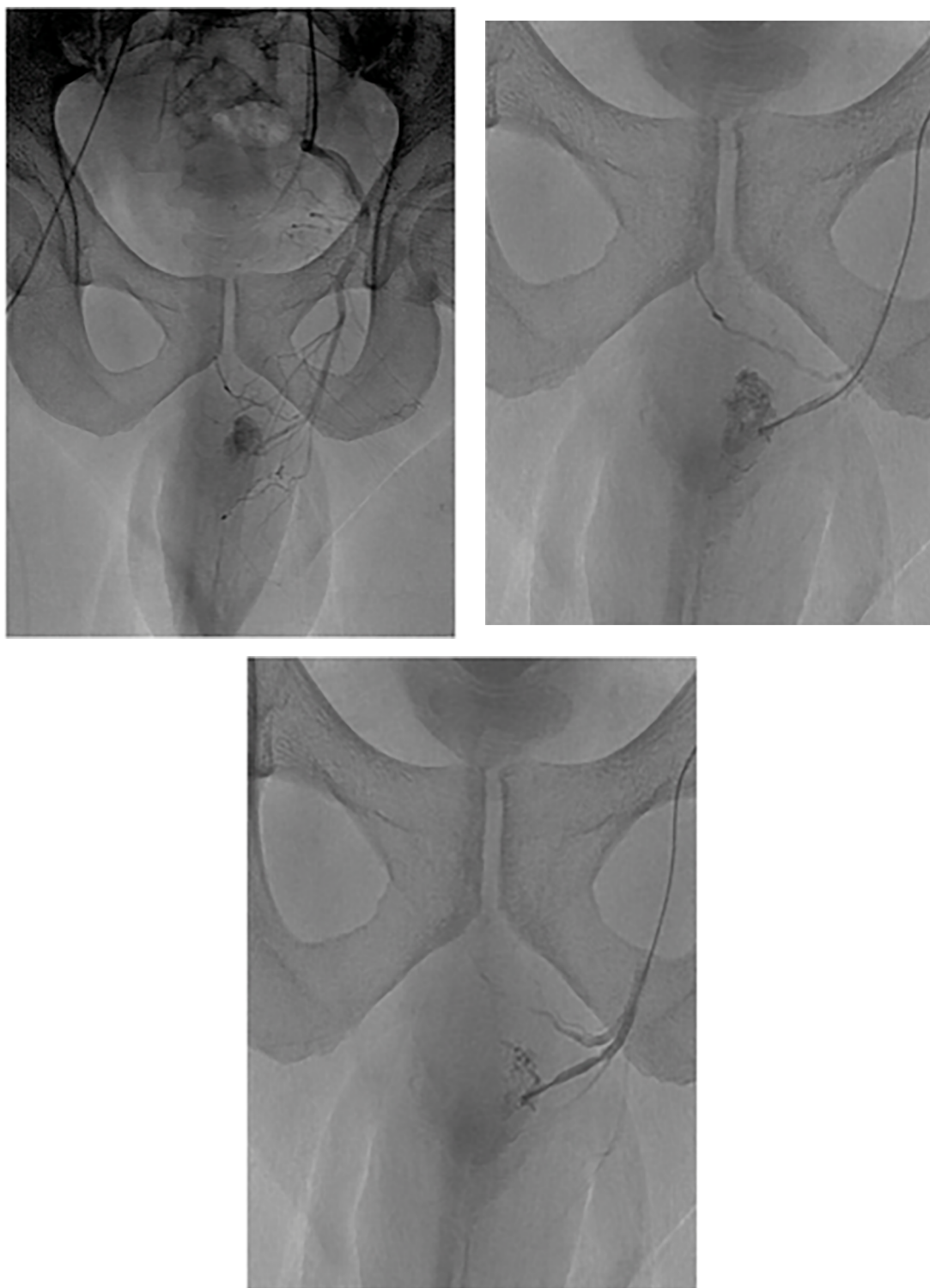


Fig. 1. (A, B, C): Arterial Lacunar Fistula. The angiography clips above show the different time lapse stages as dye is injected into the internal pudendal artery. One can appreciate the fistula best in picture A. The arrow in figure B is pointing at the pathognomonic finding of the arterial lacunar fistula with its characteristic intracavernosal cone shaped blush of contrast.

effect on pain and erection. He was admitted to the medicine service for further management.

Urology team evaluated the patient and recommended consultation by Interventional Radiology for angiography and/or embolization. He underwent pelvic aortogram, bilateral internal iliac arteriogram, and left external pudendal arteriogram. A left internal pudendal arterio-cavernosal fistula was identified. The branch of the left internal

pudendal artery contributing to the fistula was embolized with platinum fibered coils. Patient reported improvement in pain and resolution in priapism.

He was seen in Urology clinic for follow up where he reported having more episodes of priapism since the embolization, so consideration was given to repeating the procedure. Further investigations including work up for sickle cell anemia and spinal imaging were recommended.

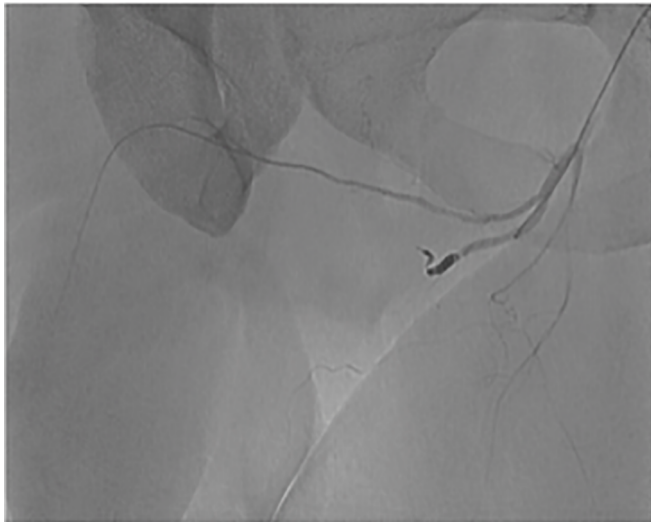

Fig. 2. The Embolized Artery. CT angiography image that shows the platinum coil located in the internal pudendal artery. One can appreciate there is no longer flow into the fistula or distal to the coil indicating successful occlusion.

Unfortunately, he was lost to further follow up.

Discussion

High flow, non-ischemic priapism is an uncommon etiology of priapism and while most are painless, this can be a condition of great distress for males. High flow priapism occurs secondary to congenital malformation or from the development of arteriovenous malformation secondary to genital trauma. Anatomically in most males the penis is supplied by the penile artery, a branch off the internal pudendal artery which arises from the anterior internal iliac artery. When arteriovenous malformations develop in these vessels, uncontrolled arterial overflow can result in recurrent high-flow priapism as described in our patient. As non-ischemic priapism is not a medical emergency the recommended first line therapy is observation.³ Conservative measures include ice, and site-specific compression (can be both diagnostic and therapeutic if the erection remits upon compression).⁴

Once priapism is deemed to be non-ischemic based on diagnostic aspiration, there is no value to performing therapeutic aspiration or injecting vasoconstrictive agents.³ There remains a risk of extravasation of the injected vasoconstrictive agents into the penis. In patients with recurrent symptoms of priapism without sustained resolution with

observation more aggressive measures should be followed. A CT angiogram is the next step to locate the fistula anatomically. The pathognomonic arteriographic finding is an arterial-lacunar fistula; a characteristic intracavernosal cone shaped blush of contrast can be seen at the site of the cavernous artery or arterial laceration as seen in Fig. 1.³ Selective embolization and coiling have shown to be favorable treatment modalities with high success rates. Various materials are currently available to Interventional Radiologists for temporary or permanent angioembolization. In the case above a permanent platinum coil was used for embolization as shown in Fig. 2, however generally temporary materials are used due to the risk of subsequent erectile dysfunction.¹ Other notable adverse effects of embolization are penile gangrene, gluteal ischemia, purulent cavernositis and perineal abscess.⁵

Conclusion

Priapism requires rapid determination of etiology as the management and urgency depends on the pathophysiology behind the diagnosis. Ischemic priapism is a medical emergency and the management hence forth depends on relieving the backed up venous blood. Non-ischemic priapism is not a medical emergency and should not be treated as such. A good understanding of the pathophysiology of priapism is necessary to care and manage these patients.

Funding

This research did not receive any specific grant from funding agencies in the public, commercial, or not-for-profit sectors.

Declaration of competing interest

None.

References

1. Shigehara K, Namiki M. *Clinical Management of Priapism: A Review*. 2016. <https://doi.org/10.5534/wjmh.2016.34.1.1>.
2. Broderick GA, Kadioglu A, Bivalacqua TJ, Ghanem H, Nehra A, Shamloul R. Priapism: pathogenesis, epidemiology, and management. *J Sex Med*. 2010;7(1 PART 2): 476–500. <https://doi.org/10.1111/j.1743-6109.2009.01625.x>.
3. Halls JE, Patel D V, Walkden M, Patel U. Priapism: Pathophysiology and the Role of the Radiologist. doi:10.1259/bjr/62360925.
4. Ridgley J, Raison N, Iqbal Sheikh M, Dasgupta P, Shamim Khan M, Ahmed K. Systematic Review 1 ANDROLOGY Ischaemic priapism: a clinical review. *Urol Times*. 2017;43(1):1–8. <https://doi.org/10.5152/tud.2017.59458>.
5. Sandock DS, Seftel AD, Herbener TE, Goldstein I, Greenfield AJ. Perineal abscess after embolization for high-flow priapism. *Urology*. 1996;48(2):308–311. [https://doi.org/10.1016/S0090-4295\(96\)00176-8](https://doi.org/10.1016/S0090-4295(96)00176-8).