



Chronic sinusitis-associated antrolith

Nyla Manning^a, Patrick Wu^a, Jana Preis^{b,*}, Hector Ojeda-Martinez^a, Michael Chan^b

^aSUNY Downstate Medical Center, 450 Clarkson Ave, Brooklyn, NY 11203, USA

^bVA NY Harbor Healthcare System, Brooklyn Campus, 800 Poly Place, Brooklyn, NY 11209, USA

ARTICLE INFO

Article history:

Received 14 June 2018

Received in revised form 31 October 2018

Accepted 31 October 2018

Keywords:

Antrolith
Rhinolith
Rhinolithiasis
Sinolith
Sinusitis
Chronic sinusitis

ABSTRACT

An antrolith is a calcified mass found in the nasal cavity or sinus, usually maxillary, described in literature as a rare phenomenon. Its presenting symptoms are variable and include symptoms associated with chronic sinusitis. We describe a 66 year old man with chronic sinusitis who presented with facial pain and epistaxis and upon further evaluation was found to have an antrolith of the left maxillary sinus.

© 2018 Published by Elsevier Ltd. This is an open access article under the CC BY-NC-ND license (<http://creativecommons.org/licenses/by-nc-nd/4.0/>).

Introduction

An antrolith is considerably rare, usually described in medical literature by ENT or dental specialists [1–6], with an estimated occurrence of 1 in 10,000 ENT patients [2]. It is a calcified mass found in the anterior nasal cavity, the maxillary sinus, and less often the frontal sinus [1,3,7]. Formation of the mass results from the deposition of calcium and magnesium salts around an organic or inorganic nucleus at the site of local inflammation caused by a foreign body [2–5], which can either be endogenous (intrinsic) or exogenous (extrinsic) in origin [2,5,8,9].

Although most antroliths tend to be small and asymptomatic [5], cases have been reported of antroliths found in patients with a history of chronic sinusitis [6,8]. Most often antroliths are unilateral, but bilateral occurrences have also been described [7]. Diagnosis is first established with imaging, which may incidentally discover an antrolith in an asymptomatic patient [10]. The mainstay of treatment is surgical removal. The technique for removal depends on the size and the location of the antrolith.

Description of this entity was first published by Bartholin in 1654 [2–4,10–12]. Radiologic features were described by MacIntyre in 1900 [2–4]. The term rhinolith was later defined by Polson in 1943 [12]. Subsequently in 1969, Bowerman introduced the term antrolith [8]. The terms rhinolith, rhinolithiasis, sinolith, and

antrolith are currently used interchangeably in medical literature and refer to the same diagnosis.

We report a case of an antrolith found to be the cause of recurrent sinusitis in a patient with prior left maxillary trauma.

Case report

A 66-year-old man presented to the hospital with epistaxis. He reported that while he was using his CPAP machine, he noted moisture on his face and realized it was blood. Two days prior to admission, the patient felt a blister around the left nare accompanied by cough, mild headache, and tearing. The day prior to admission, the patient was evaluated by ENT for left facial pain and chronic nasal congestion. He denied fever, chills, rhinorrhea, dizziness, nausea, or vomiting.

In the past, the patient suffered trauma to his left maxillary region as a result of a physical altercation with subsequent surgery to the area of injury. Afterwards for years, he reported multiple left maxillary sinus infections for which he received antimicrobials. The patient's past medical history also included hypertension, coronary artery disease, diabetes mellitus complicated by diabetic gastroparesis and nephropathy, obstructive sleep apnea on CPAP, schizophrenia, chronic depression, glaucoma, and erectile dysfunction. His surgical history was significant for lipoma removal, root canals, and teeth extractions involving the left maxillary premolars in addition to the adjacent left maxillary surgery after trauma sustained in 1969.

The patient quit smoking twenty years prior to this presentation, reported no history of ethanol abuse, and reported no illicit

* Corresponding author.

E-mail address: jana.preis@va.gov (J. Preis).

drug abuse. He was originally from Puerto Rico, served in the U.S. Army, was never stationed overseas, and did not have any significant travel except for returning from Puerto Rico a week prior to this presentation.

On physical assessment, the patient's vital signs were within normal limits besides a slightly elevated blood pressure of 143/76 mm Hg. His exam was remarkable for left maxillary sinus tenderness with no surrounding erythema, warmth, or notable compromise of the surrounding skin. The patient wore superior and inferior dentures with no noted abnormalities of the soft or hard palate, tongue, or oropharynx. There was no cervical, submandibular, preauricular, retroauricular, or supraclavicular lymphadenopathy detected. The remainder of the physical examination was unremarkable.

On laboratory studies, the patient was noted to have a mild leukocytosis with neutrophil predominance. His hemoglobin, hematocrit, and platelets were within normal limits. Chronically elevated BUN and creatinine levels were found, unchanged from his baseline. His ESR was elevated at 29. On imaging studies, the patient's chest X-ray was unremarkable. CT of the head without contrast and CT of the sinuses without contrast were performed, and the findings are described below (Figs. 1 and 2).

Further laboratory work-up revealed that the patient was negative for HIV. Other laboratory tests such as complement levels, ANA, pANCA, myeloperoxidase, proteinase, and cytoplasmic Ab were negative or unremarkable.

On admission, a left nare swab was obtained at the site of the patient's previous blister. The patient subsequently received renally dosed vancomycin and ampicillin-sulbactam. The swab yielded MSSA, after which vancomycin was discontinued. Due to concerns for an underlying osteomyelitis from the erosion found on imaging, the history of chronic infections in the same area, and his underlying condition of diabetes, a biopsy of the affected area was recommended once the patient was off of antimicrobial therapy for a few days.

AFB, bacterial, and mycology left maxillary tissue cultures were all negative.

The patient underwent rhinoscopy by ENT during which a calcification was removed. The pathology report of the specimen taken from the left maxillary sinus revealed a "calcifying nasal polyp (rhinolithiasis)." Afterwards, the patient made a full recovery with no recurrent episodes of pain or infection.

Discussion

Antroliths are rare calcified masses generally located in the anterior nasal cavity or maxillary sinus and are of endogenous or exogenous origin. Among the exogenous causes are grains, wood, small stone fragments, seeds, and insects, while endogenous causes include blood clots, tooth fragments, and mucosal necrosis

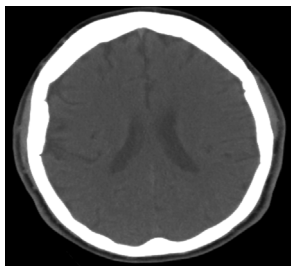


Fig. 1. CT of the head without contrast: No evidence of acute territorial infarct, hemorrhage, mass effect, or extra-axial collections. Findings suggestive of age related atrophy and chronic microvascular ischemic changes. Intracranial atherosclerotic disease.

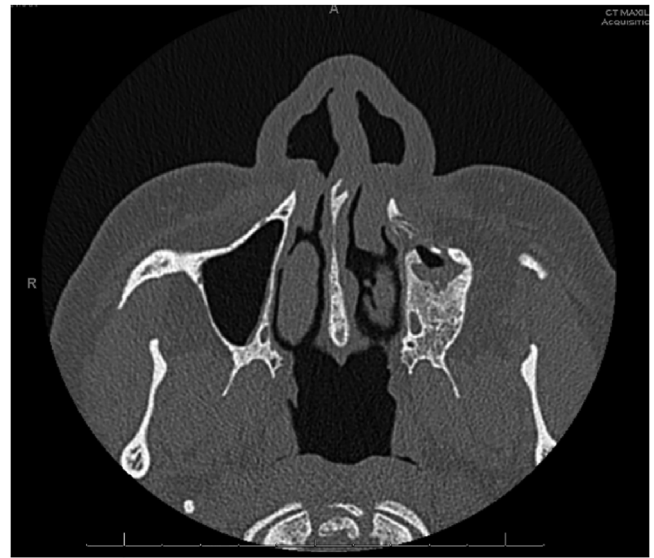

Fig. 2. CT of the sinuses without contrast: Chronic left maxillary sinusitis with associated erosion of the anterior/inferior wall of the left maxillary sinus as well as the left maxillary alveolar ridge and hard palate. There is focal defect at the floor of the left maxillary sinus. There is mild soft tissue prominence anterior to the left alveolar ridge, overlying the area of osseous erosion, without evidence for drainable fluid collection.

[2,5–9]. The exact pathogenesis of antroliths are not clear, although it is suspected that generally a foreign body causes surrounding inflammation, encouraging mineral deposition and serving acts as a nidus for mineral deposition [3,4], over a span of years [10,11]. Antroliths can be the cause of chronic sinusitis as obstruction can provide an environment for infection to occur. Alternatively, chronic sinusitis itself can encourage the development of an antrolith as chronic inflammation and long standing infection can foster deposition of calcium and other mineral salts in the affected area [2]. In our patient, it is unclear whether an antrolith preceded or was caused by his chronic sinusitis. It is possible that his prior trauma to the left maxillary region provided an inflammatory environment for the formation of the antrolith around a nasal polyp causing chronic sinusitis. It is also possible that post-trauma, the sinus structure was altered such that flow between sinuses became limited, predisposing the patient to infections in the area and thus encouraging antrolith formation.

Antroliths appear to be found more commonly in women and young adults although they may be found across all age groups [12]. Predisposing factors for antroliths include long standing infection, poor sinus drainage, and the presence of a foreign body in the sinus. It has been reported that the presence of fungal masses can also favor the formation of antroliths [6,7,9]. Patients with certain underlying conditions such as diabetes mellitus, HIV, radiotherapy, chemotherapy, or long-term antimicrobial therapy can be predisposed to fungal infections [9]. Although our patient had underlying diabetes, his negative mycology culture and negative fungal pathology excluded a fungal cause for his left maxillary sinus antrolith.

Our patient had clinical reports of facial pain and epistaxis in addition to his chronic recurrent sinusitis. Other general clinical features reported in patients with antroliths include nasal obstruction, purulent discharge, foul smelling post nasal drip, oronasal fistula, otorrhea, anosmia, cacosmia (inability to properly identify smell), hyposmia, palatal perforation, dacryocystitis, blood-tinged discharge, and halitosis [3,7,11,12].

Imaging is crucial in the assistance of establishing the diagnosis, especially if anterior rhinoscopy is negative. Imaging

modalities which can be employed include dental periapical films, panoramic X-rays, and CT of the sinuses [13]. Radiologically, antroliths can have a variety of presentations. They can be of homogenous or heterogeneous consistency; the radiodensity can be radiopaque or less commonly radiolucent; the outline can be rugged or smooth; the shape can be round, oval, or irregular; the location can be at the maxillary sinus or less commonly at frontal sinus; and they can be unilateral or less commonly bilateral [7,8]. Even if suspicion is high for radiographical antroliths, the differential diagnosis remains wide and includes osteomyelitis, impacted teeth, calcified mucus retention cysts, displaced follicular cysts, chronic inflammatory processes such as syphilis and tuberculosis, benign tumors (such as nasal glioma, septal dermoid tumor, osteoma, chondroma, calcifying angiofibroma, and odontoma) and malignant tumors (such as squamous cell carcinoma, chondrosarcoma and osteosarcoma) [2–5,9]. In the case of unilateral masses, malignant tumor must be ruled out with nasal endoscopy and CT imaging [1]. In our patient, CT of the sinuses revealed an erosion in the left maxillary sinus. Due to this abnormal finding in correlation with the patient's symptoms, investigational biopsy of the abnormality was performed, leading to identification and removal of the entity.

Surgery is the treatment of choice for antrolith removal [12], whether performed by endoscopic sinus surgery (ESS), Caldwell-Luc surgery, or a combination of the two [6–8]. Antimicrobials are given if there is a suspected superinfection of the sinuses. Removal of antroliths can improve or resolve chronic sinusitis and associated symptoms. Asymptomatic antroliths are not typically removed but are generally followed up in case they do become symptomatic.

Conclusion

Although a rare entity, the antrolith should be included in the differential diagnosis of a mass or erosion found on imaging of a patient with chronic sinusitis. Diagnosis requires a high level of suspicion based on history and imaging, which is important as the treatment involves surgical removal of the mass. While also encountered by ENT and dental specialists, antroliths must also be considered by infectious diseases specialists when confronted with a patient with symptoms of chronic sinusitis.

Conflicts of interest

There are no conflicts of interest to declare.

Consent

Written informed consent was obtained from the patient for publication of this case report and accompanying images. A copy of the written consent is available for review by the Editor-in-Chief of this

Funding source

None.

Authorship

All authors had access to the data and a role in writing this manuscript.

Acknowledgments

We would like to acknowledge the VA NY Harbor Healthcare System and the U.S. Department of Veterans Affairs for providing the opportunity to care for patients with exposure to a variety of clinical cases.

References

- [1] Varadharajan K., Stephens J, Madani G, Parikh A. Rhinolith causing unilateral chronic maxillary sinusitis. *BMJ Case Rep* 2014;2014(April (17)).
- [2] Sharouny H, Raman R. Rhinolith in a 13-year-old boy: a case report of a rare condition. *Thrita* 2015;4(1):e24905.
- [3] Singh R, Varshney S, Bist S, Gupta N, Bhatia R, Kishore S. Rhinolithiasis and value of nasal endoscopy: a case report. *Int J Otorhinolaryngol* 2007;7(2):1–5.
- [4] Ayub-ur-Rehman MN Muhammad, Moallam FA. Endoscopy in rhinolithiasis. *J Coll Physicians Surg Pak* 2012;22(September (9)):601–3.
- [5] Ozkan O, Bingol F, Budak A. The importance of endoscopy in the diagnosis and treatment of rhinolithiasis: a case report. *J Acute Dis.* 2013;70–2.
- [6] Nair S, James E, Dutta A, Goyal S. Antrolith in the maxillary sinus: an unusual complication of endoscopic sinus surgery. *Indian J Otolaryngol Head Neck Surg* 2010;62(January (1)):81–3.
- [7] Shenoy V, Maller V, Maller V. Case report: maxillary antrolith: a rare cause of recurrent sinusitis. *Case Rep Otolaryngol* 2013;2013:527152.
- [8] Ahire D. Chronic sinusitis leads to sinolith formation in maxillary sinus – a rare case. *Sci Rep* 2013;2(3):670.
- [9] Rodrigues MT, Munhoz ED, Cardoso CL, de Freitas CA, Damante JH. Chronic maxillary sinusitis associated with dental impression material. *Med Oral Patol Oral Cir Bucal* 2009;14(April (4)):E163–6.
- [10] Shah FA, George S, Reghunandan N. A case presentation of a large rhinolith. *Oman Med J* 2010;25(July (3)):230–1.
- [11] Brehmer D, Riemann R. The rhinolith—a possible differential diagnosis of a unilateral nasal obstruction. *Case Rep Med* 2010;2010:845671.
- [12] Pinto LSS, Campagnoli EB, Azevedo RS, Lopes MA, Jorge J. Rhinoliths causing palatal perforation: case report and literature review. *Oral Surg Oral Med Oral Pathol Oral Radiol Endod* 2007;104(December (6)):e42–6.
- [13] Barros CA, Martins RR, Silva JB, Souza JB, Ribeiro-Rotta RF, Batista AC, Mendonça EF. Rhinolith: a radiographic finding in a dental clinic. *Oral Surg Oral Med Oral Pathol Oral Radiol Endod* 2005;100(October (4)):486–90.