




Case Report

Trigeminal schwannoma presenting with malocclusion: A case report and review of the literature

Brandon Emilio Bertot¹, Melissa Lo Presti¹, Katie Stormes¹, Jeffrey S. Raskin², Andrew Jea², Daniel Chelius³, Sandi Lam⁴

¹Department of Neurosurgery, Baylor College of Medicine/Texas Children's Hospital, Houston, Texas, United States, ²Department of Neurosurgery, Indiana University School of Medicine/Riley Children's Hospital, Indianapolis, Indiana, United States, ³Department of Otolaryngology, Baylor College of Medicine/Texas Children's Hospital, Houston, Texas, United States, ⁴Department of Neurosurgery, Northwestern University Feinberg School of Medicine, Ann and Robert H. Lurie Children's Hospital, Chicago, Illinois, United States.

E-mail: Brandon Emilio Bertot - brandon.bertot@bcm.edu; Melissa Lo Presti - melissa.lopresti@bcm.edu; Katie Stormes - katie.stormes@bcm.edu; Jeffrey S. Raskin - jraskin@iuhealth.org; Andrew Jea - aja@iuhealth.org; Daniel Chelius - dchelieu@texaschildrens.org; *Sandi Lam - slam@luriechildrens.org



*Corresponding author:

Sandi Lam,
Professor/Division Chief,
Department of Neurosurgery
/Division of Pediatric
Neurosurgery, Northwestern
University Feinberg School
of Medicine, Ann and Robert
H. Lurie Children's Hospital,
Chicago, Illinois, United States.
slam@luriechildrens.org

Received : 11 September 2019

Accepted : 01 May 2020

Published : 08 August 2020

DOI

10.25259/SNI_482_2019

Quick Response Code:



ABSTRACT

Background: Trigeminal schwannomas are rare tumors of the trigeminal nerve. Depending on the location, from which they arise along the trigeminal nerve, these tumors can present with a variety of symptoms that include, but are not limited to, changes in facial sensation, weakness of the masticatory muscles, and facial pain.

Case Description: We present a case of a 16-year-old boy with an atypical presentation of a large trigeminal schwannoma: painless malocclusion and unilateral masticatory weakness. This case is the first documented instance; to the best of our knowledge, in which a trigeminal schwannoma has led to underbite malocclusion; it is the 19th documented case of unilateral trigeminal motor neuropathy of any etiology. We discuss this case as a unique presentation of this pathology, and the relevant anatomy implicated in clinical examination aid in further understanding trigeminal nerve pathology.

Conclusion: We believe our patient's underbite malocclusion occurred secondary to his trigeminal schwannoma, resulting in associated atrophy and weakness of the muscles innervated by the mandibular branch of the trigeminal nerve. Furthermore, understanding the trigeminal nerve anatomy is crucial in localizing lesions of the trigeminal nerve.

Key words: Cranial neuropathy, Malocclusion, Pediatric neurosurgery, Skull base tumor, Trigeminal schwannoma

INTRODUCTION

Schwannomas of the trigeminal nerve are rare; they constitute about 0.07–0.3% of all intracranial tumors and 0.8–5% of intracranial schwannomas.^[1] Uncommon in pediatrics, the incidence of trigeminal schwannomas is highest in the middle decades of life with 38–40 years being most common.^[18] However, in an analysis of 73 cases, Goel *et al.* found the highest incidence of trigeminal schwannomas to be in young adults between the ages of 21 and 30, 28.7%.^[10] Glasauer and Tandon report the incidence of trigeminal schwannomas to be at least 10% in adolescents,^[9] while Goet *et al.* report an incidence of 17.8%.^[10]

Common presenting symptoms of trigeminal schwannomas include facial numbness (65.8%), headaches (58.9%), gait disturbance (42.5%), hearing deterioration (24.7%), diplopia (24.7%), facial pain (20.5%), visual deterioration (17.8%), pathological laughter (12.3%), proptosis (10.9%),

This is an open-access article distributed under the terms of the Creative Commons Attribution-Non Commercial-Share Alike 4.0 License, which allows others to remix, tweak, and build upon the work non-commercially, as long as the author is credited and the new creations are licensed under the identical terms.

©2020 Published by Scientific Scholar on behalf of Surgical Neurology International

limb weakness (9.6%), and seizures (4.1%).^[10] In addition, cranial nerve palsies are common, ranging from V1 to V3, including the sensory and motor divisions to central nervous III, IV, VI, and VII-X.^[10,16,21] Furthermore, on physical examination, patients with trigeminal schwannomas may demonstrate diminished facial sensation, weakness of the muscles of mastication, signs of pyramidal, cerebellar, or long tract involvement/dysfunction, exophthalmos, papilledema, or altered sensorium.^[16,21]

We present a case of a 16-year-old boy with an atypical presentation of a large trigeminal schwannoma: painless malocclusion and unilateral masticatory weakness. This case is the first documented instance; to the best of our knowledge, in which a trigeminal schwannoma has led to underbite malocclusion. We aimed to discuss this case as a unique presentation of this pathology and the key role understanding relevant anatomy holds in diagnosis and understanding of trigeminal nerve pathology.

CASE DESCRIPTION

A 16-year-old boy with a history of the right-sided Bell's Palsy presented with complaints of a severe underbite and excessive drooling on the left side. These symptoms were progressive over several years to the point that the patient could not comfortably close his mouth. The patient had an unremarkable dental history with no previous oral trauma/procedures. On examination, the patient had facial asymmetry at rest, with the normal function of the facial nerve bilaterally. The facial sensation was intact symmetrically in the V1, V2, and V3 distributions to light touch. He had nystagmus on the right lateral gaze and mild weakness of the left masseter. There was no other indication of brainstem or cranial nerve dysfunction. The remainder of the physical examination was normal.

A computed tomography (CT) scan maxillofacial without contrast was performed, demonstrating a $5.2 \times 6.6 \times 4.3$ cm intra-axial mass with compression and displacement of the brainstem [Figure 1]. There was slight dilatation of the third and lateral ventricles representing mild obstructive hydrocephalus and erosion of the base of the skull involving the carotid canal, foramen rotundum, pterygoid canal, foramen ovale, middle cranial fossa floor, and the internal auditory canal [Figure 1]. An underbite occlusion was noted with associated atrophy of the left masticator, mylohyoid, and anterior belly of digastric muscles and underdeveloped left mandible body and ramus [Figure 1].

CT angiography (CTA) of the head and magnetic resonance imaging (MRI) brain with and without contrast was performed for further evaluation. CTA demonstrated bony remodeling of the left sphenoid and petrous portion of the temporal bones related to the mass with external compression (approximately 50% narrowing) of the cavernous and petrous segment of the

left internal carotid artery (ICA) [Figure 2]. MRI brain showed a $5.2 \times 7.8 \times 5.1$ cm heterogeneously extra-axial enhancing mass centered in the left mesial temporal region with involvement of the skull base and left foramen ovale, rotundum and spinosum, encasement and moderate narrowing of the left ICA, mild obstructive hydrocephalus, and marked compression of the brainstem [Figure 3]. In addition, there was associated atrophy of the left masticator muscles with underdevelopment of the left mandible body and ramus [Figure 4].

The patient underwent a left orbitozygomatic craniotomy for resection. Pathology of the resected tumor was consistent with the World Health Organization Grade I Schwannoma. Postoperative imaging demonstrated near-complete resection with a thin rim of the residual tumor along the lateral dural margin of the left cavernous sinus/lesser sphenoid wing and at the floor of the left middle cranial fossa extending

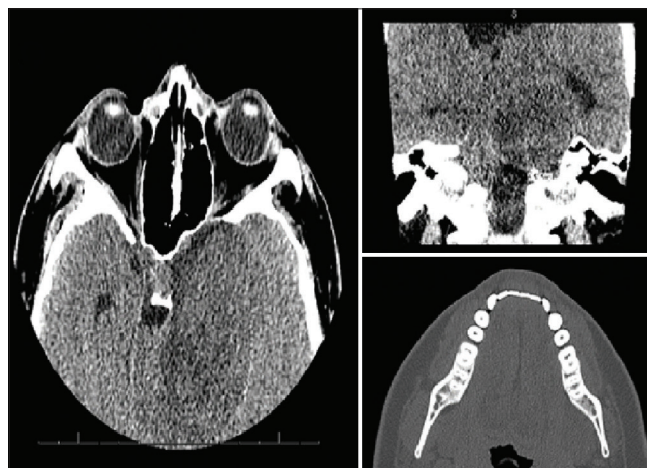

Figure 1: Diagnostic computed tomography maxillofacial images figure description: images a and b demonstrate axial and coronal views of a $5.2 \times 6.6 \times 4.3$ cm intra-axial mass with compression and displacement of the brainstem. Image C demonstrates an axial view of the mandible, showing asymmetry of the left mandibular ramus and muscular hypotrophy on the left side.

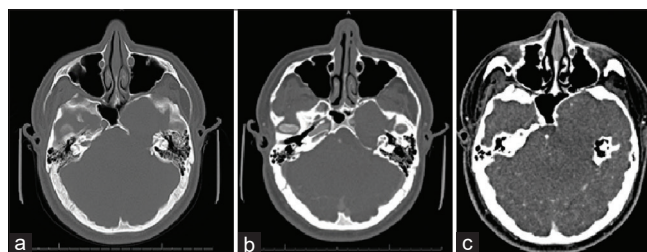


Figure 2: Diagnostic computed tomography angiogram figure description: bony erosion and remodeling of the left sphenoid and petrous temporal bones are seen, related to the mass (a and b). On contrasted imaging (c), angiography demonstrates external compression (approximately 50% narrowing) of the cavernous and petrous segment of the left internal carotid artery.

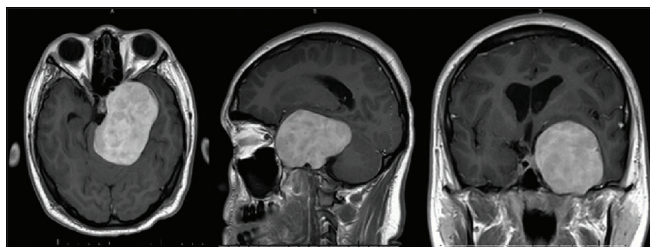


Figure 3: Preoperative magnetic resonance imaging figure description: contrasted T1-weighted magnetic resonance imaging with axial, sagittal, and coronal views of the 5.2 × 7.8 × 5.1 cm heterogeneously extra-axial enhancing mass centered in the left mesial temporal region with involvement of the skull base and left foramen ovale, rotundum and spinosum, encasement and moderate narrowing of the left internal carotid artery, mild obstructive hydrocephalus, and marked compression of the brainstem.

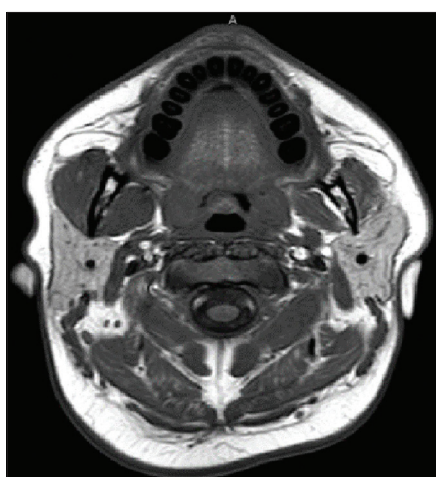

Figure 4: Mandibular and muscular atrophy figure description: contrasted T1-weighted magnetic resonance imaging demonstrates asymmetric of the mandibular rami, with left smaller than right, as well as atrophy of the muscles of mastication.

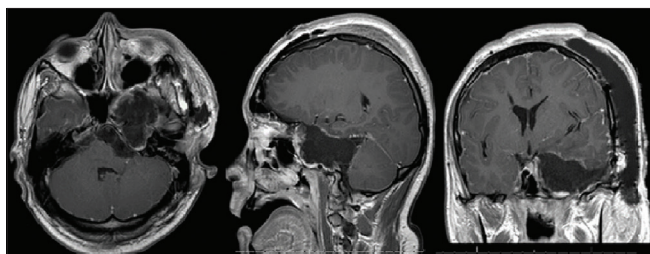


Figure 5: Postoperative magnetic resonance imaging figure description: contrasted T1-weighted magnetic resonance imaging with axial, sagittal, and coronal views demonstrates near complete resection with a thin rim of residual tumor along the lateral dural margin of the left cavernous sinus/lesser sphenoid wing and at the floor of the left middle cranial fossa extending posteriorly to the roof of the remodeled left petrous temporal bone.

posteriorly to the roof of the remodeled left petrous temporal bone [Figure 5]. He was evaluated by occupational therapy, physical therapy, speech-language pathology, and physical medicine and rehabilitation physicians while inpatient and was discharged to inpatient rehabilitation on a postoperative day 16. The patient experienced the left cranial nerve IV, V, VI, and VII neuropathies, manifesting as abnormal left eye adduction and external rotation, absent left-sided corneal reflex, left-sided facial weakness, left-sided lagophthalmos, and dysarthria/slurred speech. On follow-up, the patient continues to show significant improvement in the left cranial nerve VI palsy and with improvement, though some residual impairment of the left cranial nerve IV, V, and VII function. Despite these deficits, he is functionally independent with normal breathing and swallowing function. Imaging at 12-month follow-up showed the stable residual tumor. He is currently enrolled in a community college in good standing.

DISCUSSION

This is a unique case of a 16-year-old boy with an atypical presentation of a unilateral trigeminal motor neuropathy (UTMN) and severe underbite malocclusion attributable to a large trigeminal schwannoma. This patient experienced only weakness and atrophy of the muscles innervated by the mandibular branch of the trigeminal nerve, which likely resulted in his severe underbite malocclusion due to chronic compression of the trigeminal nerve in this location causing underdevelopment and muscle atrophy. This specific presentation of trigeminal nerve dysfunction is referred to as

Table 1: Reported cases of pure unilateral trigeminal motor neuropathy and suspected etiology.

Study, year	Age/Sex	Suspected etiology
Chia, 1988 ^[5]	30M	Viral infection
	29M	Viral infection
	20M	Viral infection
	22F	Unknown
	24M	Unknown
Andonopoulos et al., 1990 ^[2]	Unknown	Sjogren's syndrome
Chiba et al., 1990 ^[7]	57M	Unknown
Moon et al., 1993 ^[17]	58M	Viral infection
Beydoun, 1993 ^[4]	29M	Neurofibromatosis Type 2
		Multiple sclerosis
Takamatsu et al., 1993 ^[22]	38M	Multiple sclerosis
Ko and Chan, 1995 ^[14]	70F	Head trauma
Kang et al., 2000 ^[13]	38M	Viral infection
Park et al., 2006 ^[19]	64F	Trigeminal schwannoma
		Unknown
Chiba and Echigo, 2012 ^[6]	70F	Unknown
Tsugawa et al., 2014 ^[23]	67F	Viral infection
Lee et al., 2015 ^[15]	77F	Unknown
Wilson et al., 2016 ^[24]	29F	Stroke
Kamppi et al., 2018 ^[12]	57M	<i>Borrelia burgdorferi</i>

a pure UTMN. In fact, before this case, only 18 other cases of pure UTMN have been reported in the literature [Table 1]. The most common cause of pure UTMN is postviral neuropathy following viral infection of the upper respiratory tract (6/18).^[5,13,17,23] Other less common causes include tumors (2/18),^[4,19] stroke (1/18),^[24] trauma (1/18),^[14] multiple sclerosis (1/18),^[22] *Borrelia burgdorferi* (1/18),^[12] Sjogren's syndrome (1/18),^[2] and unknown etiologies (5/18).^[5,6,7,15]

The clinical presentations of trigeminal schwannomas vary depending on the location of the trigeminal nerve, from which the tumor arises, the degree of extension into other areas of the brain, and the overall size of the tumor. Clinical suspicion for trigeminal schwannomas should be raised in the presence of slowly progressive symptoms with a predominance of trigeminal nerve-related symptoms, including facial numbness and masticatory muscle wasting.^[10] To understand, the signs and symptoms caused by trigeminal schwannomas, it is important to understand the anatomy of the trigeminal nerve and the classification of trigeminal schwannomas.

Anatomy of the trigeminal nerve

Trigeminal nerve anatomy is complex but crucial in understanding the localization of symptomatology and pathology of related lesions. The trigeminal nerve is the largest of the 12 cranial nerves. It originates from the brainstem as four nuclei, three sensories, and one motor.^[8] Exiting the brainstem is fibers composing the trigeminal root, of which there are two parts, the sensory and motor roots.^[8] Going further distal, the somas of the unipolar sensory neurons, whose axons compose the sensory root, convene at the trigeminal ganglion, which is located within Meckel's cave.^[8] Arising from the trigeminal ganglion is the three divisions into which the trigeminal nerve is classically divided: V1 (ophthalmologic division), V2 (maxillary division), and V3 (mandibular division), each of which gives off terminal branches.^[8] Of these, V1 and V2 are purely sensory, and V3 is mixed supplying both sensations to the face as well as motor innervation to the muscles of mastication (temporalis, masseter, medial, and lateral pterygoids), tensor tympani, tensor veli palatini, mylohyoid, and anterior belly of the digastric.^[8] Each of these trigeminal nerve branches enters/exits the skull through different pathways (the superior orbital fissure for V1, foramen rotundum for V2, and foramen ovale for V3).^[8]

In addition, the trigeminal nerve is commonly discussed by segments: brainstem, cisternal, Meckel's cave, cavernous, and peripheral segments.^[3] This classification system is most helpful during the radiographic interpretation of the trigeminal nerve.^[3] Lesions to the trigeminal nerve arising at any of these segments can cause a characteristic clinical presentation that can be used to further localize the lesion and

determine, which imaging modality would be most useful in helping to make the diagnosis.^[3] In our case, UTMN points to V3 involvement, with the symptomatology pointing to motor involvement only. Similarly, several trigeminal segments were involved in the lesion in this case, including the cisternal, Meckel's cave, cavernous, and peripheral segments.

Other systems were developed to further classify trigeminal schwannomas by location; Jefferson described Type A, B, or C trigeminal schwannomas, depending on their location in the middle, posterior, or both middle and posterior fossas, respectively.^[11] Type D was later added by Samii *et al.* to describe tumors originating predominately in the extracranial space.^[20] The location of trigeminal schwannomas is important to describe/classify as it corresponds to the signs and symptoms with which patients present. For example, Type A and C trigeminal schwannomas, which have middle fossa involvement, originating at the trigeminal ganglion, located in Meckel's cave, commonly present with facial pain.^[18,21] Type B or C schwannomas, which have posterior fossa involvement, can compress the brainstem, cerebellum, and cerebellar peduncles, resulting in lower cranial nerve deficits as well as pyramidal, cerebellar, and long tract signs. Type D schwannomas that originate or extend predominately along with V1, V2, or V3 can affect the cavernous sinus segments of V1 or V2, or the peripheral segments of V1–V3. This, in turn, can result in facial sensory deficits, compression of cranial nerves III, IV, and/or VI within the cavernous sinus if there is the involvement of these portions of V1 or V2, proptosis if it extends along the length of V1 as it travels through the superior orbital fissure, and atrophy/weakness of the muscles of mastication if it involves V3. Our case is best described as a Type D trigeminal schwannoma because it consisted of a predominately extra-axial mass with involvement of multiple cranial foramina, isolated pathology of the motor division of V3 presenting with UTMN, mild obstructive hydrocephalus, and marked compression of the brainstem.

The mandibular division/V3 can be divided into three trunks: the undivided trunk, the anterior trunk, and the posterior trunk.^[8] Each trunk gives off a specific branch or branches that innervate certain muscles supplied by V3. Branching from the undivided trunk is the tensor tympani, tensor veli palatini, and medial pterygoid nerves, which supply the muscles, from which they are named.^[8] Coming from the anterior trunk is the masseteric and deep temporal nerves, as well as the nerve to the lateral pterygoid, which supply the muscles, from which they are named.^[8] Coming from the posterior trunk is the nerve to mylohyoid, which supplies both the mylohyoid muscle and the anterior belly of the digastric.^[8] Thus, knowing the anatomy of the trigeminal nerve, specifically the trunks of V3 and their branches, can allow for better localization of trigeminal nerve lesions when it is causing motor deficits to the muscles innervated

by V3. In our case, this helps us identify the main area of symptomatology related to our patient's lesion as consisting of all three of the V3 trunks since muscles innervated by each trunk were affected, as evidenced by physical examination and imaging findings. For example, there was atrophy of the anterior belly of digastric, mylohyoid, and left masticatory muscles seen on imaging. Since these muscles are involved in retracting and elevating the mandible, our patient's underbite may have been a result of the weakness of these motions as well as impaired jaw mechanics due to disruption of normal movements and developmental asymmetry.

CONCLUSION

This case demonstrates a unique presentation of an adolescent patient presenting with a trigeminal schwannoma manifesting with a pure UTMN, resulting in severe underbite malocclusion, which is the first documented instance of this etiology. Although most trigeminal schwannomas present with sensory loss and pain, our patient presented with a severe underbite as a result of the weakness of the muscles innervated by the mandibular branch of the trigeminal nerve. Due to a complex anatomy, trigeminal nerve tumors can present with a variety of symptoms. Understanding relevant anatomy is key to localizing pathology.

Declaration of patient consent

The authors certify that they have obtained all appropriate patient consent.

Financial support and sponsorship

Nil.

Conflicts of interest

There are no conflicts of interest.

REFERENCES

- Agarwal A. Intracranial trigeminal schwannoma. *Neuroradiol J* 2015;28:35-41.
- Andonopoulos A, Lagos G, Drosos A, Moutsopoulos H. The spectrum of neurological involvement in Sjögren's syndrome. *Br J Rheumatol* 1990;29:21-4.
- Bathla G, Hegde A. The trigeminal nerve: An illustrated review of its imaging anatomy and pathology. *Clin Radiol* 2013;68:203-13.
- Beydoun SR. Unilateral trigeminal motor neuropathy as a presenting feature of neurofibromatosis Type 2 (NF2). *Muscle Nerve* 1993;16:1136-7.
- Chia LG. Pure trigeminal motor neuropathy. *Br Med J (Clin Res Ed)* 1988;296:609-10.
- Chiba M, Echigo S. Unilateral atrophy of the masticatory muscles and mandibular ramus due to pure trigeminal motor neuropathy: A case report. *Oral Surg Oral Med Oral Pathol Oral Radiol* 2012;113:e30-4.
- Chiba S, Motoi Y, Noro H, Asakura K, Matsumoto H. A case of pure trigeminal motor neuropathy. *Rinsho Shinkeigaku* 1990;30:883-7.
- Fillmore EP, Seifert MF. Anatomy of the trigeminal nerve. In: *Nerves and Nerve Injuries*. San Diego: Academic Press; 2015. p. 319-50.
- Glasauer FE, Tandon PN. Trigeminal neurinoma in adolescents. *J Neurol Neurosurg Psychiatry* 1969;32:562-8.
- Goel A, Muzumdar D, Raman C. Trigeminal neuroma: Analysis of surgical experience with 73 cases. *Neurosurgery* 2003;52:783-90.
- Jefferson G. The Trigeminal neurinomas with some remarks on malignant invasion of the gasserian ganglion. *Neurosurgery* 1955;1:11-54.
- Kamppi A, Kämppi L, Kemppainen P, Kanerva M, Toppila J, Auranen M. Focal atrophy of the unilateral masticatory muscles caused by pure trigeminal motor neuropathy: Case report. *Clin Case Rep* 2018;6:939-43.
- Kang Y, Lee E, Hwang M. Pure trigeminal motor neuropathy: A case report. *Arch Phys Med Rehabil* 2000;81:995-8.
- Ko KF, Chan KL. A case of isolated pure trigeminal motor neuropathy. *Clin Neurol Neurosurg* 1995;97:199-200.
- Lee D, Ha Y, Kim M, Yoo B. Pontine infarction presenting with isolated trigeminal motor neuropathy. *J Neurol Sci* 2015;357:e390.
- McCormick PC, Bello JA, Post KD. Trigeminal schwannoma. Surgical series of 14 cases with review of the literature. *J Neurosurg* 1988;69:850-60.
- Moon JS, Park YK, Sunwoo IN. A case of pure trigeminal motor neuropathy. *J Korean Neurol Assoc* 1993;11:136-7.
- Nager GT. Neurinomas of the trigeminal nerve. *Am J Otolaryngol* 1984;5:301-33.
- Park KS, Chung J, Jeon BS, Park S, Lee K. Unilateral trigeminal mandibular motor neuropathy caused by tumor in the foramen ovale. *J Clin Neurol* 2006;2:194-7.
- Samii M, Migliori MM, Tatagiba M, Babu R. Surgical treatment of trigeminal schwannomas. *J Neurosurg* 1995;82:711-8.
- Sharma BS, Ahmad FU, Chandra PS, Mahapatra AK. Trigeminal schwannomas: Experience with 68 cases. *J Clin Neurosci* 2008;15:738-43.
- Takamatsu K, Takizawa T, Miyamoto T. A case of pure trigeminal motor neuropathy. *Rinsho Shinkeigaku* 1993;33:541-5.
- Tsugawa J, Ouma S, Fukae J, Tsuboi Y, Maki Y, Hokezu Y. Pure trigeminal motor neuropathy with an antecedent infection: A case report. *Rinsho Shinkeigaku* 2014;54:515-7.
- Wilson M, Hodgson E, Felstead A. Focal atrophy of the masticatory muscles caused by pure trigeminal motor neuropathy: Case report. *Br J Oral Maxillofac Surg* 2016;54:e13-4.

How to cite this article: Bertot BE, Presti ML, Stormes K, Raskin JS, Jea A, Chelius D, *et al.* Trigeminal schwannoma presenting with malocclusion: A case report and review of the literature. *Surg Neurol Int* 2020;11:230.