



Case report

A case report of reversible bronchiectasis in an adult: Pseudobronchiectasis

Canan Kucuk^{a,*}, Mustafa Hamidullah Turkkan^b, Kemal Arda^c^a Ankara 29 Mayıs Hospital Anesthesiology and Reanimation Department, Turkey^b Ankara Dr. Nafiz Körez Sincan Hospital Chest Disease Department, Turkey^c SBU Gülhane Education and Research Hospital Radiology Department, Turkey

A B S T R A C T

Bronchiectasis is a sequel to permanent chronic airway inflammation and defined as 'irreversible bronchial dilatation'. It is increasingly being recognized with the wider availability of high-resolution computed tomography. Children with noncystic fibrosis can be seen with improvement in bronchiectasis even resolution, as opposed to adults. We report a case of reversible bronchial dilatation in an adult as evidenced by high-resolution computed tomography, which demonstrates that, although quite rare in adults, spontaneous resolution may occur.

1. Introduction

Classical definition of bronchiectasis is permanent, irreversible, localized abnormal dilatation of bronchi that ends with fibrosis [1–6]. There is no well-defined guide for diagnosis of bronchiectasis and handling of managing this issue is still difficult by all means. The reason for that may be the variety of causes. One of the causes of bronchiectasis is transmural lung infections (pulmonary tuberculosis, pneumonia). Chronic inflammation result with failure to clear mucoid secretions and destruction of lung tissue especially elastic fibers [7].

This also can be genetic. In cystic fibrosis there is more viscous sputum. In primary ciliary dyskinesia the problem is inability to clear sputum because of genetic reasons. The pathophysiology of bronchiectasis is still not well defined.

The other causes are primary and secondary immunodeficiencies, connective tissue diseases, allergic bronchopulmonary aspergillosis. Bronchiectasis has also been associated with chronic obstructive pulmonary disease and asthma. There is high percentage of patients with no identifiable cause making the etiological diagnosis difficult and considered idiopathic.

During pneumonia, sometimes reversible dilatations may develop without destruction of segmental bronchi. These recurrent bronchial dilatations in acute infectious illnesses can be mistakenly defined as bronchiectasis. It is called pseudobronchiectasis for bronchial dilatation that develops frequently following an infection and resolves after the acute infection heals. It is usually cylindrical, rarely cystic [8].

2. Case report

A 64-year-old female patient with HT and DM type 2, nonsmoker,

presented with acute cough, purulent sputum production and fever. Vital findings were stable except for the fever of 37.8 °C.

Inspiratory rale was present at the basal area of lung. Posteroanterior (PA) chest X-ray showed infiltration of the left lung including the costophrenic sinus. The patient had clarithromycin and ceftriaxone therapy started. Moxifloxacin treatment was initiated on continuing infiltration at control PA chest X-ray after 15 days. Computed tomography of thorax was performed. In CT examination, the structure including the pleura in the basal segment of the left lower lobe of the lung and the localized bronchiectasis appearance in the adjacent area were detected (Fig. 1). However, after 10 months from first CT examination, the appearance of bronchiectasis was not detected in second CT examination (Fig. 2).

3. Discussion

Bronchiectasis is a progressive, irreversible bronchial dilatation that has been shown to be resistant to long-term follow-up. Inflammation and infectious damage to the bronchial and bronchial walls result in a vicious cycle and ultimately bronchiectasis. In pneumonia, dilatations may occur in bronchi. However, these dilatations are temporary and return to normal with treatment. This type of bronchiectasis is called pseudobronchiectasis. It disappears in the following months of pneumonia. Reversible bronchiectasis with bronchography is reported. But reversible bronchiectasis with CT/HRCT is rarely reported [9].

The definition of pseudobronchiectasis in early recycling remains uncertain in the pathogenesis of bronchiectasis; either it is a different clinical situation or a misinterpretation of radiology [10]. Pseudobronchiectasis may represent an early stage in the pathogenesis of bronchiectasis. On the contrary, pseudobronchiectasis may be an over-

* Corresponding author.

E-mail address: canankuc@yahoo.com (C. Kucuk).

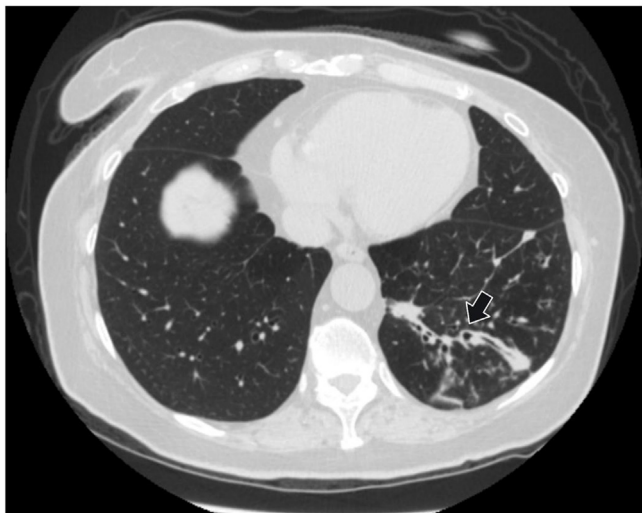


Fig. 1. First CT examination reveals bronchiectasis and peribronchovascular thickening on left lower lobe of the lung (arrow).

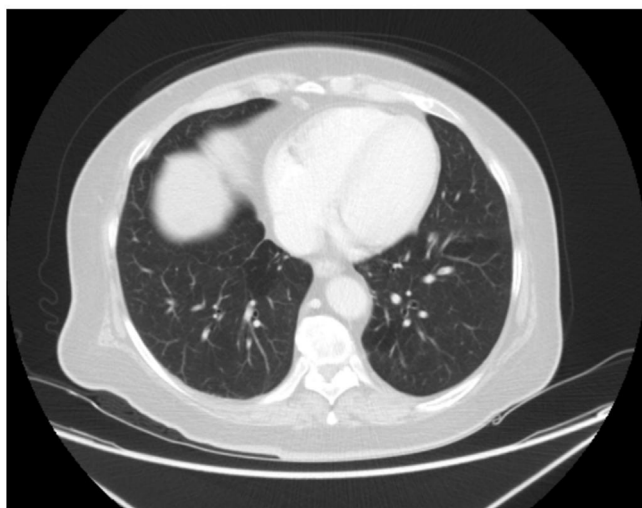


Fig. 2. After 10 months on control CT examination, bronchiectasis appearance could not be seen.

read of radiology [11].

‘Irreversible dilatation of the bronchi’ is the definition of bronchiectasis and reversible form has been seen rarely but in 6 non-cystic fibrosis patients bronchiectasis is reversed and in 8 patients improvement was seen in pediatric group that is reviewed by Gaillard et al. Of course a single study would not be sufficient for explanation of complete reversal [12].

We think that careful interpretation of bronchiectasis in the assessment of CT/HRCT of patients with brief symptoms of pneumonia and it should be mentioned in the report that may be pseudo-bronchiectasis. All the bronchiectasis are not permanent after infection and should be followed up.

Conflict of interest statement

There is no conflict of interest.

Appendix A. Supplementary data

Supplementary data to this article can be found online at <https://doi.org/10.1016/j.rmcr.2019.03.002>.

References

- [1] L.M. Reid, Reduction in bronchial subdivision in bronchiectasis, *Thorax* 5 (3) (1950) 233–247.
- [2] M.A. Morechi, S.B. Fiel, An update on bronchiectasis, *Curr. Opin. Pulm. Med.* 1 (1995) 119–124.
- [3] E.Y. Kang, R.R. Miller, N.L. Müller, Bronchiectasis: comparison of preoperative thin-section CT and pathologic findings in resected specimens, *Radiology* 195 (3) (1995) 649–654.
- [4] A.F. Barker, Bronchiectasis, *N. Engl. J. Med.* 346 (2002) 1383–1393.
- [5] N. Müller, R. Fraser, K. Lee, T. Johkoh, Large airway disease, in: N. Müller, R. Fraser, K. Lee, T. Johkoh (Eds.), *Diseases of the Lung: Radiologic and Pathologic Correlations*, first ed., Lippincott Williams and Wilkins, Philadelphia, 2003, pp. 266–286.
- [6] P.T. King, S.R. Holdsworth, N.J. Freezer, E. Villanueva, P.W. Holmes, Characterisation of the onset and presenting clinical features of adult bronchiectasis, *Respir. Med.* 100 (2006) 2183–2189.
- [7] P.J. Cole, Inflammation: a two-edged sword—the model of bronchiectasis, *Eur. J. Respir. Dis. Suppl.* 147 (1986) 6–15.
- [8] N.E. Wiseman, The diagnosis of foreign body aspiration in childhood, *J. Pediatr. Surg.* 19 (1984) 531–535.
- [9] V.L. Yap, M.L. Metersky, Reversible bronchiectasis in an adult: a case report, *J. Bronchol. Interv. Pulmonol.* 19 (4) (2012) 336–337.
- [10] A.K. Aung, P.J. Thompson, B.M. Teh, C. McGrath, Pseudobronchiectasis after pertussis and mycoplasma infection, *Am. J. Respir. Crit. Care Med.* 1 (3) (2012) 292–294 186.
- [11] R. Agarwal, Bronchiectasis in acute pneumonia...pseudobronchiectasis, *Chest* 132 (2007) 2054–2055.
- [12] E.A. Gaillard, H. Carty, D. Heaf, R.L. Smyth, Reversible bronchial dilatation in children: comparison of serial high-resolution computer tomography scans of the lungs, *Eur. J. Radiol.* 47 (3) (2003) 215–220.