

# Phosphaturic Mesenchymal Tumor in the Proximal Femur Presenting as Tumor-induced Osteomalacia: A Case Report and Literature Review

Shubham Tungenwar<sup>1</sup>, S Subith<sup>1</sup>, Moin Mukadam<sup>1</sup>, Sagar Kokate<sup>1</sup>, Siddharth Gunay<sup>1</sup>

## Learning Point of the Article:

It is imperative to consider tumor-induced osteomalacia as a potential cause for patients experiencing muscle weakness and pain. Swiftly locating and removing the tumor is paramount in relieving symptoms and restoring bone health.

## Abstract

**Introduction:** An uncommon medical disorder known as tumor-induced osteomalacia (TIO) is characterized by severe hypophosphatemia, renal phosphate wasting, and osteomalacia due to a tumor. TIO has recently been linked to a particular kind of tumor known as phosphaturic mesenchymal tumor (PMT). PMTs release phosphatonins, such as fibroblast growth factor-23 (FGF23), which elevates serum levels of FGF23, leading to phosphate wasting and osteomalacia. However, due to their infrequent occurrence and vague symptoms, such as bone pain, myopathies, arthralgias, fractures, and weakness, the diagnosis of PMTs is often delayed or misdiagnosed. In this case report, a rare case of PMT in the proximal femur resulted in TIO, and it highlights the long and difficult journey from symptom onset to correct diagnosis and successful surgical management.

**Case Report:** A 51-year-old woman endured persistent joint pain, muscle weakness, and fatigue for 2 years. Despite having no known health issues, she suffered from hip pain that spreads to her knees and ankles, and tingling and paresthesia in her legs, making it difficult to bear weight. She underwent surgery to remove a parathyroid adenoma, but unfortunately, her symptoms returned. Her magnetic resonance imaging revealed a lesion in her proximal femur, which was promptly removed. The tissue examination results verified the identity of the tumor as a PMT. The patient's phosphorus levels returned to normal and after a year of follow-up, she was able to resume normal daily activities, bear weight on the affected limb and showed no signs of the tumor recurrence.

**Conclusion:** Adult patients experiencing bone pain, progressive weakness, and multiple fractures with no family history of similar conditions should consider TIO as a potential cause. It is rare and often misdiagnosed and complete surgical removal of the tumor is the optimal treatment for TIO, resulting in the resolution of long-standing symptoms and biochemical abnormalities. Timely recognition, localization, and surgical removal of the tumor are crucial for symptom resolution and the restoration of normal bone mineralization.

**Keywords:** Hypophosphatemia, fibroblast growth factor 23, phosphaturic mesenchymal tumor, tumor-induced osteomalacia.

## Introduction

The unusual condition known as phosphaturic mesenchymal tumors (PMT) induces paraneoplastic tumor-induced osteomalacia (TIO). This condition is characterized by the release of phosphatonins, particularly fibroblast growth factor 23

(FGF23). FGF23, in turn, reduces the reabsorption of phosphate in the proximal renal tubules and inhibits the production of 1,25-dihydroxycholecalciferol by 1- $\alpha$ -hydroxylase [1]. These tumors are often small and challenging to identify during physical examination. Symptoms of osteomalacia, such as bone pain and generalized muscle weakness, typically precede

Access this article online

Website:  
www.jocr.co.in

DOI:  
<https://doi.org/10.13107/jocr.2024.v14.i02.4204>

## Author's Photo Gallery



Dr. Shubham Tungenwar



Dr. S Subith



Dr. Moin Mukadam



Dr. Sagar Kokate



Dr. Siddharth Gunay

<sup>1</sup>Department of Orthopaedics, T N Medical College and BYL Nair Ch Hospital, Mumbai, Maharashtra, India.

### Address of Correspondence:

Dr. Shubham Tungenwar,  
Department of Orthopaedics, T N Medical College and BYL Nair Ch Hospital, Mumbai, Maharashtra, India.  
E-mail: tungenwarshubham@gmail.com

Submitted: 16/11/2023; Review: 03/12/2023; Accepted: January 2024; Published: February 2024

DOI: <https://doi.org/10.13107/jocr.2024.v14.i02.4204>

This is an open access journal, and articles are distributed under the terms of the Creative Commons Attribution-NonCommercial-ShareAlike 4.0 License <https://creativecommons.org/licenses/by-nc-sa/4.0/>, which allows others to remix, tweak, and build upon the work non-commercially, as long as appropriate credit is given and the new creations are licensed under the identical terms

Parameter	Patient test values	Normal range
Po4 Levels	1.7 mg/dL	2.5–4.5 mg/d
iPTH Levels	23.1 pg/mL	14–65 pg/mL
Vitamin D 25 hydroxy, Total	25 ng/mL	50–70 ng/mL
FGF-23c terminal	2209 RU/mL	5–210 RU/mL
Alkaline Phosphatase	870 U/L	20–140 U/L
Serum Calcium	8.9 mg/dL	8.6–10.3 mg/dL
24 hr Urine Phosphorus	54 mmol/day	13–42 mmol/day
iPTH: Intact parathyroid hormone, PO4: Inorganic phosphate, FGF-23: Fibroblast growth factor 23		

**Table 1: Laboratory investigations.**

the tumor diagnosis by several years, leading to significant morbidity [2, 3]. While cases of PMT are primarily reported in individual case studies, the imaging features of these tumors vary widely. Once diagnosed, complete resection with wide margins is typically performed to prevent local recurrence. This approach usually leads to rapid resolution of laboratory abnormalities and symptoms and is often considered curative [4].

### Case Report

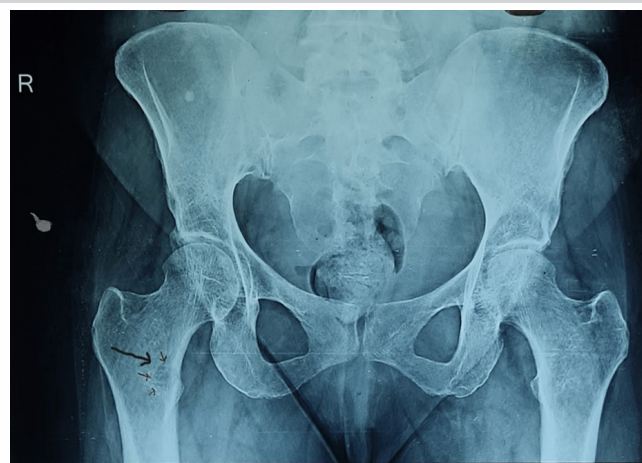
We present the case of a 51-year-old female who complained of multiple joint pain, fatigue, and muscle weakness, persisting for 2 years. The patient had no known co-morbidities and initially experienced bilateral hip pain, gradually extending to both knees and ankles. In addition, she reported tingling and

	Post Op Day 7	Post Op 3 Months	Post Op 6 Months
Sr PO4	4.2	4.1	4.6
iPTH	23.5	40.7	72.3
FGF 23	2209	150	87.4
iPTH: Intact parathyroid hormone, Sr PO4: Serum inorganic phosphate, FGF-23: Fibroblast growth factor 23			

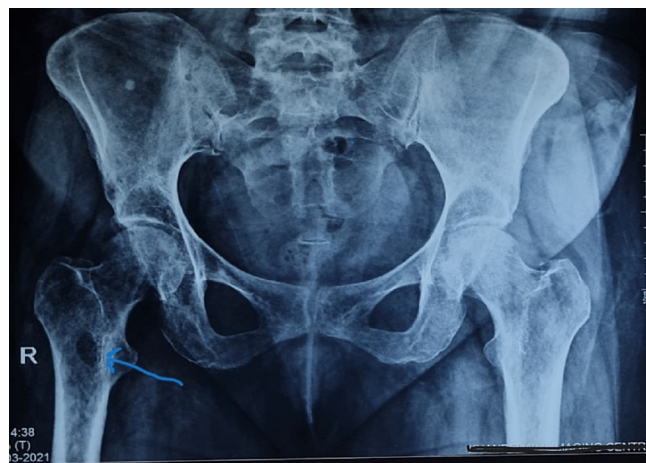**Table 2: Post-operative laboratory investigations.**

paresthesia in both lower limbs, making it difficult to bear weight. The patient was referred to the endocrinology department for evaluation because of concerns over bone fragility. There were no reports of falls, kidney stones, hereditary osteoporosis, or metabolic bone disease throughout her medical history.

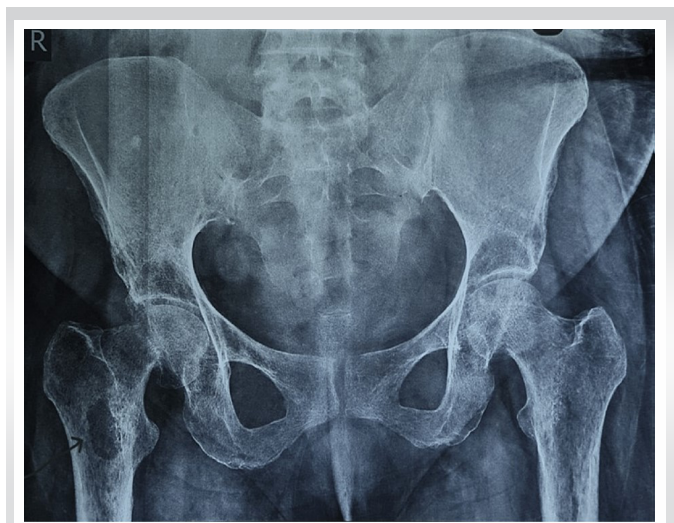
In addition, she denied ever having smoked, drunk alcohol, used steroids, or used recreational drugs. Laboratory investigations revealed hypophosphatemia, reduced 1,25(OH)2D3, high serum ALP and significantly high FGF-23 levels (Table 1). Based on her medical and family history, there were no indications of a genetic cause of hypophosphatemia, and she had not been exposed to medications or toxins known to cause acquired hypophosphatemia. An X-ray of the pelvis with both hips revealed an osteolytic lesion in the proximal femur which gradually increased in size over the course of 1 year along with osteopenia and insufficiency fracture in the right femoral neck (Fig. 1-3). A neck ultrasound was performed, revealing the presence of a parathyroid adenoma. Subsequently, the patient underwent surgery for the excision of the parathyroid adenoma. Following the procedure, she experienced significant improvement in pain and could mobilize with support for 9 months. However, the symptoms



**Figure 1: X-ray showing osteolytic lesion in the proximal femur.**



**Figure 2: 6 Months Later. Lesion can be visualized more clearly with well-defined margins.**



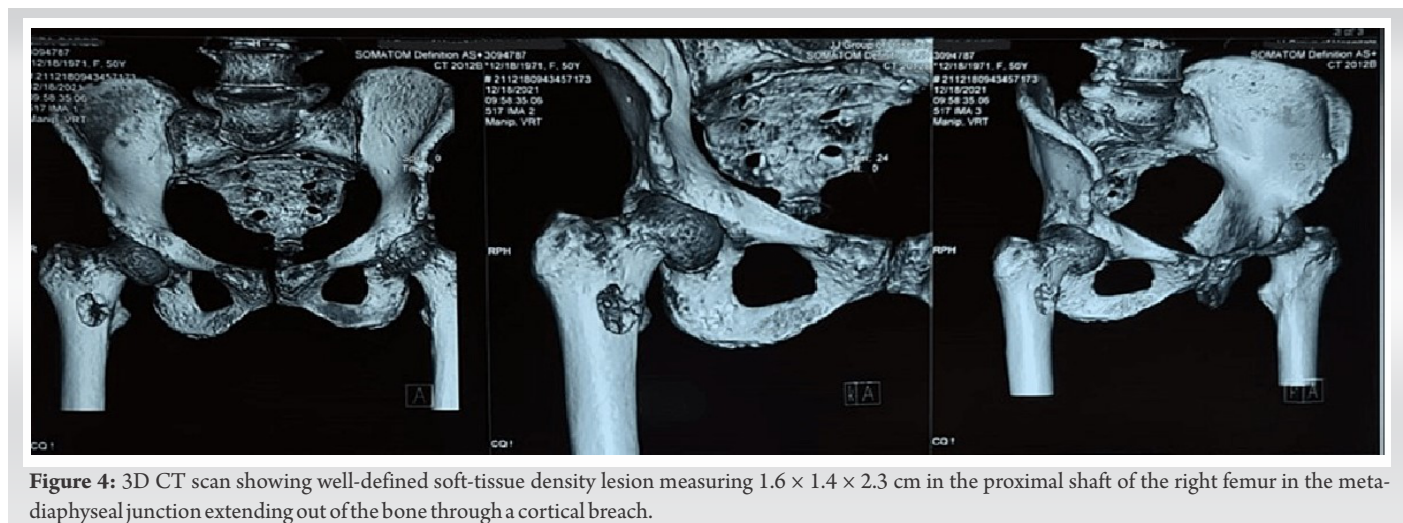
**Figure 3:** 1 year later. Size of the lesion seems to be significantly increased. Generalized osteopenia with insufficiency fracture in the right femoral neck seen.

recurred after this initial improvement. 3D CT scan showed well-defined soft-tissue density lesion measuring  $1.6 \times 1.4 \times 2.3$  cm in the proximal shaft of right femur in the meta-diaphyseal junction with cortical breach (Fig. 4). The patient's magnetic resonance imaging (MRI) revealed generalized osteopenia with bilateral avascular necrosis of femoral heads and insufficiency fracture of right femoral neck and a well-defined exophytic lesion measuring  $3 \times 2 \times 3$  cm, arising from the anterior part of the proximal shaft of the right femur (Fig. 5). The lesion involved both the cortex and medulla of the bone. The patient also had muscle atrophy in the gluteal and thigh muscles. In addition, the patient's neck ultrasound revealed two oval-shaped nodules (measuring  $2.2 \times 16 \times 25$  mm) on the right thyroid lobe. These nodules had an uneven texture and indicated an active parathyroid adenoma and the possibility of recurrence.

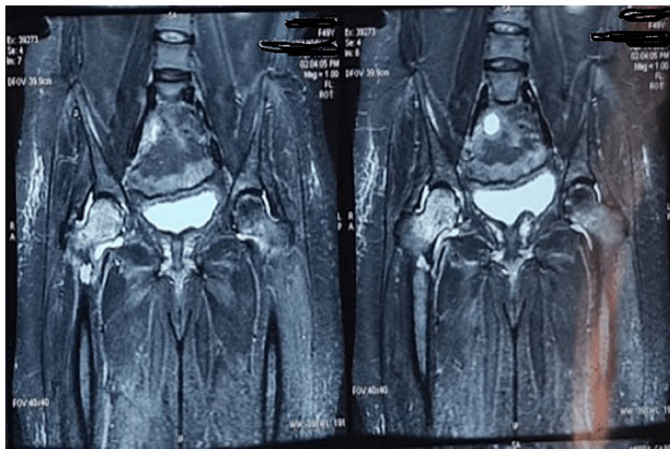
Further evaluation with a Ga68 DotA scan showed a  $1.5 \times 1$  cm

nodule in the soft tissue near the patient's right femur. This nodule had a high concentration of  $^{68}\text{Ga}$  DOTATATE and a standard uptake value (max) of 4.89. The medical team suspected that the patient may have TIO due to the presence of this nodule. An additional clinicopathological correlation was required for confirmation. A whole-body FDG PET scan showed metabolic activity in the soft-tissue near the patient's right femur. The nodule expressed SSTR, further supporting the suspicion that it was the primary lesion causing TIO. However, further clinicopathological correlation was still needed for confirmation. The patient received phosphate, calcium, and Vitamin D supplements as part of their treatment while undergoing evaluation. Based on consultation with the endocrinologist, it was decided to perform an excisional biopsy and curettage of the lesion. This procedure was done under spinal anesthesia and with the help of C-arm fluoroscopy. The orthopedic team removed a  $2.5 \times 3.5$  cm mass from the proximal femur (Fig. 6) and chemically cauterized the area with bone cement (Fig. 7). They also conducted prophylactic fixation using DHS plating. The histopathological examination of the removed tumor confirmed that it was a phosphaturic mesenchymal tumor, consistent with the suspected diagnosis (Fig. 8 and 9).

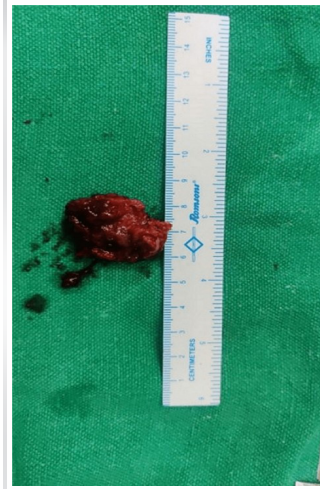Serum phosphorus levels normalized on the 7th post-operative day with a marked decreased in serum FGF 23 levels at 3-month post-operative and resulted in dramatic and remarkable clinical improvement (Table 2). TIO diagnosis is often delayed, causing patients to suffer from symptoms for years before receiving proper treatment. The rarity of the disease and the vague symptoms are reasons for this delay. Critical indicators of TIO are low phosphorus levels, high serum ALP, reduced  $1,25(\text{OH})_2\text{D}_3$ , and most notably, elevated FGF-23 levels in the blood. The patient underwent regular follow-up appointments at 3–4-month intervals, during which serum phosphorus, parathyroid hormone (PTH), and calcium levels were



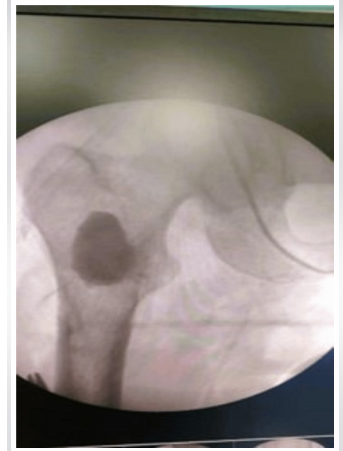
**Figure 4:** 3D CT scan showing well-defined soft-tissue density lesion measuring  $1.6 \times 1.4 \times 2.3$  cm in the proximal shaft of the right femur in the meta-diaphyseal junction extending out of the bone through a cortical breach.



**Figure 5:** MRI pelvis with both hips showing bilateral avascular necrosis of femoral heads and insufficiency fracture of the right femoral neck with exophytic lesion arising from anterior part of shaft of proximal femur.



**Figure 6:** 2.5 x 3.5 cm mass excised.

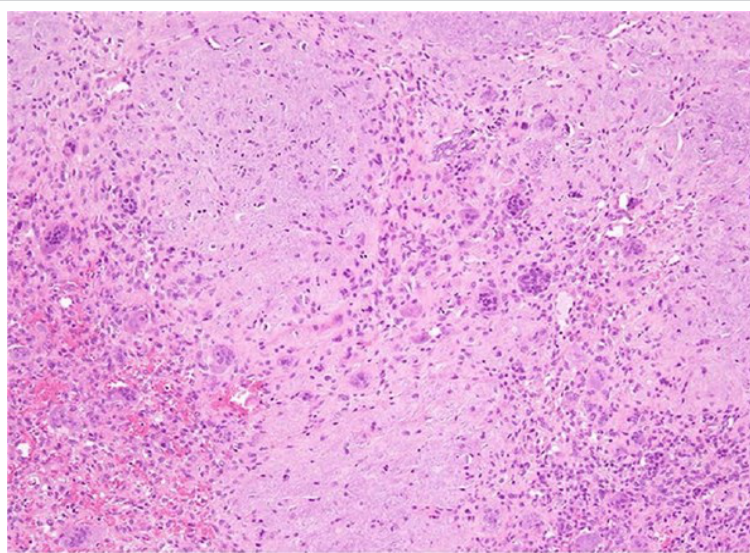


**Figure 7:** Intra Op C-Arm image shows chemical cauterization of the cavity with bone cement.

monitored. The patient's phosphorus levels remained within the normal range with oral phosphorus supplementation. After 1 year of follow-up, the patient could bear total weight on the affected limb, resumed normal day-to-day activities, and showed no signs of recurrence (Fig. 10).

### Discussion

Osteomalacia is a condition characterized by inadequate or delayed mineralization of osteoid in mature bone. TIO or oncogenic osteomalacia is terms used to refer to a modest number of cases in which osteomalacia is direct as a result of the tumor. The majority of TIO cases are linked to bone tumors or mesenchymal soft-tissue tumors [5]. One particular kind of tumor is called a PMT determined to be the main cause of TIO.

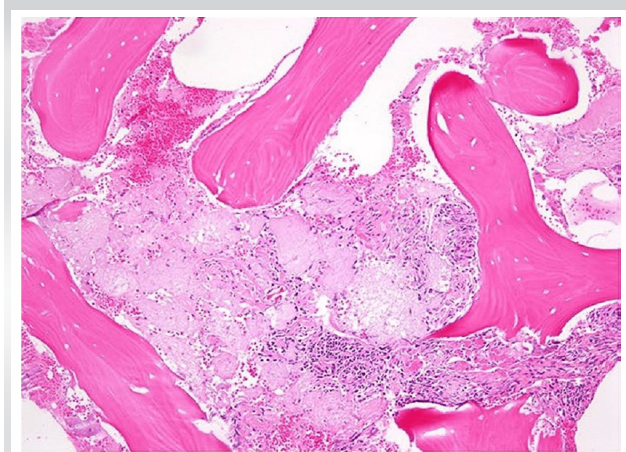


**Figure 8:** Phosphaturic mesenchymal tumors under the microscope usually show a hypocellular proliferation of monotonous spindled cells with a basophilic matrix and large cells that resemble osteoclasts.

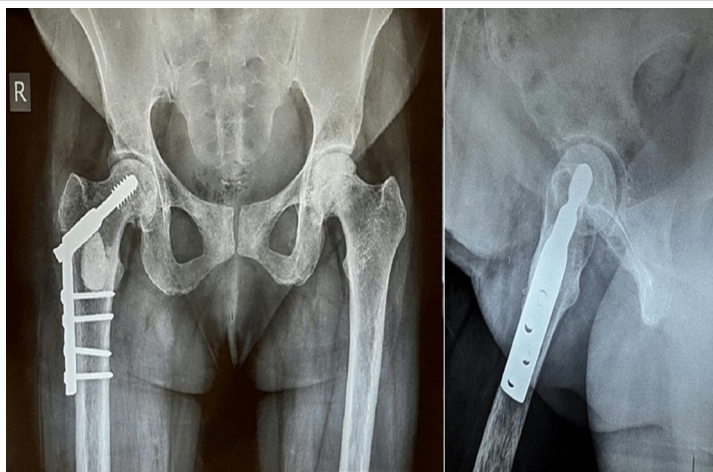
In 2004, a study by Folpe et al. [6] showed that the great majority of tumors associated with TIO were examples of a single histopathologic entity, now known as PMTs. In the 2013 Classification of Tumors of Soft Tissue and Bone, the World Health Organization included PMTs as a “morphologically distinctive neoplasms” that produce tumor-induced osteomalacia (TIO) in most affected patients. This is often caused by the tumor cells producing FGF23 [7].

PMTs are characterized by the production of a phosphaturic hormone or “phosphatonin” which is also called “FGF23”. Hypophosphatemia results from FGF23's action on the kidneys, which increases phosphate excretion and inhibits phosphate reabsorption [8]. In addition, it lowers the synthesis of active Vitamin D, which lowers phosphorus absorption through the gastrointestinal system. This dysregulation of phosphate homeostasis leads to abnormal bone mineralization and development of osteomalacia [9].

Severe hypophosphatemia is the main contributory factor of TIO's symptoms, which are unrelated to the illness itself [10]. The diagnosis of TIO can be challenging due to its non-specific symptoms, and there is often a significant delay in treatment. Patients commonly experience progressive musculoskeletal pain, muscle weakness, and bone insufficiency fractures. Misdiagnosis with other musculoskeletal or rheumatological conditions or even psychiatric conditions is common [11]. To diagnose TIO, laboratory findings typically show hypophosphatemia, hyperphosphaturia, increased levels of intact FGF23, low-normal serum calcium and PTH levels, and decreased levels of active Vitamin D. Renal tubular phosphate wasting can be confirmed through calculations of tubular reabsorption of phosphate and



**Figure 9:** Because pathologists are not acquainted with PMTs, they may confuse them for osteosarcoma when they develop permeatively between pre-existing bone trabecula.



**Figure 10:** Post-operative radiographs after 1 year.

the TmP/GFR ratio. Various imaging modalities can be used to localize PMTs, including whole-body scans such as Tc-99m sestamibi scanning, octreotide scintigraphy, FDG-PET/computed tomography (CT), whole-body MRI, and CT. Among these, 68Ga-DOTATATE PET/CT is considered the most sensitive and specific method for detecting PMTs [12].

The primary treatment for TIO is complete surgical resection of the tumor with adequate margins. To help minimize the risk of local recurrence, it is often recommended to have a margin of 10 mm for lesions on extremities and 5 mm for lesions on the trunk [13]. A rapid resolution of symptoms and normalization of serum FGF23 and phosphate levels typically follow surgical cure.

Long-term follow-up is necessary due to the possibility of late recurrence, although recurrence and metastasis are rare. For individuals who cannot have surgery or in cases where the tumor cannot be targeted, medical treatment with calcitriol and phosphate supplements may be explored. Regular follow-up with biochemical testing is essential to monitor phosphorus, calcium, alkaline phosphatase, PTH, and 24-h urine calcium levels. Adjuvant radiotherapy may be used in recurrence or incomplete resection cases, and radiofrequency ablation has been employed for inoperable tumors [14]. It is important to note that PMTs are considered benign tumors, and metastasis is uncommon, with the lung being the most common site if it does occur.

Overall, early detection, accurate diagnosis, and appropriate treatment are crucial for managing TIO and improving patient outcomes.

### Conclusion

TIO should be considered in adult patients with unexplained non-specific symptoms such as bone pain, progressive

weakness, and multiple bone fractures, especially when there is no family history of similar conditions. The rarity of the condition and the non-specific nature of its symptoms often result in a delayed diagnosis.

Complete resection of the tumor is the appropriate treatment of choice for TIO. The surgical intervention most often leads to the prompt and complete resolution of long-standing symptoms and biochemical abnormalities associated with TIO. In addition, it allows for the remineralization of the skeleton. Therefore, when there is suspicion of TIO, active efforts should be made to localize and resect the tumor, as this often leads to significant improvement in both clinical and biochemical parameters of the patient which was otherwise pushed to a blind end. Hypophosphatemia with elevated alkaline phosphatase levels should raise suspicion and prompt further evaluation for TIO. It is important to investigate the underlying cause of these abnormalities, including the possibility of a PMT.

In conclusion, TIO must be considered part of the potential causes for patients experiencing muscle weakness and musculoskeletal pain. If hypophosphatemia with elevated alkaline phosphatase is observed, it warrants further investigation in this context. In such cases, it is crucial to identify the presence of tumors and proceed with surgical resection, as this intervention often results in significant clinical and biochemical improvement.

### Clinical Message

In patients presenting with muscle weakness and musculoskeletal pain and diagnostic dilemma exists, TIO can be included in the differential diagnosis. Timely recognition, localization, and surgical resection of the tumor are essential for achieving the resolution of symptoms and restoring normal bone mineralization.

**Declaration of patient consent:** The authors certify that they have obtained all appropriate patient consent forms. In the form, the patient has given the consent for his/ her images and other clinical information to be reported in the journal. The patient understands that his/ her names and initials will not be published and due efforts will be made to conceal their identity, but anonymity cannot be guaranteed.

**Conflict of interest:** Nil **Source of support:** None

## References

1. Chong WH, Molinolo AA, Chen CC, Collins MT. Tumor-induced osteomalacia. *Endocr Relat Cancer* 2011;18:R53-77.
2. Jan de Beur SM. Tumor-induced osteomalacia. *JAMA* 2005;294:1260-7.
3. Beygi S, Denio A, Sharma TS. The foot that broke both hips: A case report and literature review of tumor-induced osteomalacia. *Case Rep Rheumatol* 2017;2017:3191673.
4. Higley M, Beckett B, Schmahmann S, Dacey E, Foss E. Locally aggressive and multifocal phosphaturic mesenchymal tumors: Two unusual cases of tumor-induced osteomalacia. *Skeletal Radiol* 2015;44:1825-31.
5. Boland JM, Tebben PJ, Folpe AL. Phosphaturic mesenchymal tumors: What an endocrinologist should know. *J Endocrinol Invest* 2018;41:1173-84.
6. Folpe AL, Fanburg-Smith JC, Billings SD, Bisceglia M, Bertoni F, Cho JY, et al. Most osteomalacia-associated mesenchymal tumors are a single histopathologic entity. *Am J Surg Pathol* 2004;28:1-30.
7. Mangham DC. World Health Organisation classification of tumours: Pathology and genetics of tumours of soft tissue and bone. *J Bone Joint Surg Br* 2004;86-B:466-6.
8. Riminucci M, Collins MT, Fedarko NS, Cherman N, Corsi A, White KE, et al. FGF-23 in fibrous dysplasia of bone and its relationship to renal phosphate wasting. *J Clin Invest* 2003;112:683-92.
9. Farrow EG, White KE. Tumor-induced osteomalacia. *Expert Rev Endocrinol Metab* 2009;4:435-42.
10. Piemonte S, Romagnoli E, Cipriani C, De Lucia F, Pilotto R, Diacinti D, et al. Six-year follow-up of a characteristic osteolytic lesion in a patient with tumor-induced osteomalacia. *Eur J Endocrinol* 2014;170:K1-4.
11. Leow MK, Hamijoyo L, Liew H, Thirugnanam U, Cheng MH, Loke KS, et al. Oncogenic osteomalacia presenting as a crippling illness in a young man. *Lancet* 2014;384:1236.
12. El-Maouche D, Sadowski SM, Papadakis GZ, Guthrie L, Cottle-Delisle C, Merkel R, et al. 68Ga-DOTATATE for tumor localization in tumor-induced osteomalacia. *J Clin Endocrinol Metab* 2016;101:3575-81.
13. Minisola S, Peacock M, Fukumoto S, Cipriani C, Pepe J, Tella SH, et al. Tumour-induced osteomalacia. *Nat Rev Dis Primers* 2017;3:17044.
14. Hesse E, Rosenthal H, Bastian L. Radiofrequency ablation of a tumor causing oncogenic osteomalacia. *N Engl J Med* 2007;357:422-4.

**Conflict of Interest:** Nil  
**Source of Support:** Nil

**Consent:** The authors confirm that informed consent was obtained from the patient for publication of this case report

## How to Cite this Article

Tungenwar S, Subith S, Mukadam M, Kokate S, Gunay S. Phosphaturic Mesenchymal Tumor in the Proximal Femur Presenting as Tumor-induced Osteomalacia: A Case Report and Literature Review. *Journal of Orthopaedic Case Reports* 2024 February;14(2):23-28.