

# Dual energy CT and research of the bone marrow edema: Comparison with MRI imaging

Luca Saba<sup>1,2</sup>, Massimo De Filippo<sup>3</sup>, Francesco Saba<sup>4</sup>, Federica Fellini<sup>5</sup>, Pierre-Yves Marcy<sup>1,2</sup>, Robert Dagan<sup>1,2</sup>, Philippe Voituriez<sup>1,2</sup>, Jacques Aelvoet<sup>1,2</sup>, Gérard Klotz<sup>1,2</sup>, Roland Bernard<sup>1,2</sup>, Valérie Salinesi<sup>1,2</sup>, Serge Agostini<sup>1,2</sup>

<sup>1</sup>Groupe ELSAN, Department of Radiology, Clinique Les Fleurs, Avenue Frédéric Mistral, Ollioules, France, <sup>2</sup>Groupe ELSAN, Department of Radiology, Clinique du Cap-d’Or, 1361 Avenue des Anciens Combattants Français d’Indochine, La Seyne-sur-Mer, France, <sup>3</sup>Department of Radiology, University of Parma, Via Gramsci 21, Parma, <sup>4</sup>University of Sassari, Via Vienna 2, Sassari, Italy, <sup>5</sup>Department of Cardiology, St Musse Hospital, 54 Rue Henri Sainte-Claire Deville, Toulon, France

**Correspondence:** Dr. Luca Saba, Groupe ELSAN Department of Radiology, Clinique du Cap D’Or, 1361 Avenue des Anciens Combattants Français d’Indochine, 83500 La Seyne-sur-Mer, France. E-mail: lukas\_red@hotmail.it

## Abstract

**Aims:** To evaluate the diagnostic accuracy of the Dual Energy Computed Tomography (DECT) in the research of the bone marrow edema. **Methods and Material:** The MRI images of 100 patients with episodes of articular and or bone pains with or without traumatic lesion were prospectively evaluated during a period between March 2018 and February 2019. In the presence of bone marrow edema, a DECT was performed. The measurement of the density of the bone marrow edema in the DECT was compared with healthy bone in the same patient by two operators. **Result:** The DECT and MRI images of 15 patients with bone marrow edema were compared. The mean of pathologic bone marrow edema was 1008.20 (Standard Deviation (SD) 23.00), for healthy bone marrow 947.53 (SD 16.42), and  $t = 11.75$ , with a statistical significance  $P < 0.05$  (Statistical significance 95%). The agreement between the measurements of the two radiologists has a statistical significance ( $P < 0.05$ ). **Conclusion:** The DECT presents an excellent diagnostic accuracy to detect the bone marrow edema, comparable to MRI. The utility of these recent possibilities is maximum where access to MRI is still very difficult.

**Key words:** Bone marrow edema; dual energy CT; magnetic resonance imaging

## Background

The terminology of bone marrow edema suggests that the water content of bone marrow is increased when it is T1W hypointense and T2W hyperintense.<sup>[1,2]</sup>

Bon marrow edema is often post-traumatic or linked to a multiples causes of biomechanical alteration; it can also be generated to acute or chronic inflammation.<sup>[1,2]</sup>

Bone marrow edema is easily identified in the magnetic resonance imaging (MRI) as a hyperintensity signal in specific sequences with fat suppression (proton density (PD) suppressed by fat or suppressed by fat T2).<sup>[1-3]</sup>

The histological findings vary based on the underlying etiology, and the presence of fibrosis or inflammatory infiltrate is frequent and often predominant.<sup>[1,2,4]</sup>

This is an open access journal, and articles are distributed under the terms of the Creative Commons Attribution-NonCommercial-ShareAlike 4.0 License, which allows others to remix, tweak, and build upon the work non-commercially, as long as appropriate credit is given and the new creations are licensed under the identical terms.

**For reprints contact:** reprints@medknow.com

**Cite this article as:** Saba L, De Filippo M, Saba F, Fellini F, Marcy PY, Dagan R, *et al.* Dual energy CT and research of the bone marrow edema: Comparison with MRI imaging. Indian J Radiol Imaging 2019;29:386-90.

**Received:** 04-Jun-2019  
**Accepted:** 08-Oct-2019

**Revision:** 20-Aug-2019  
**Published:** 31-Dec-2019

Access this article online	
Quick Response Code:	Website: www.ijri.org
	DOI: 10.4103/ijri.IJRI_243_19

The detection of bone marrow edema is important because of its diagnostic and prognostic value. It indicates underlying structural damage and may modify management in patients with rheumatoid arthritis or spondyloarthropathies.<sup>[3-6]</sup>

The new performance of Dual Energy CT (DECT) gives the possibility to detect the anatomical and pathological sign, not possible with the conventional CT. DECT applications can largely be divided into exploration of material-nonspecific and material-specific energy-dependent information.<sup>[7-9]</sup>

To evaluate the diagnostic accuracy of the Dual Energy Computed Tomography (DECT) in the research of the bone marrow edema.

## Methods and Material

The research was performed according to the World Medical Association Declaration of Helsinki. Informed consent was obtained from research subjects.

The MRI images of 100 patients with recent episode of articular and or bone pains, occurred until 10 days before the radiological examination (with or without traumatic lesion), were prospectively evaluated, during a period between March 2018 and February 2019. If the edema was present in the IRM images, the DECT was performed for researching CT bone marrow edema with Spectral images; written informed consents were obtained from all patients when a complementary CT was requested.

The exclusions criteria were patient age  $70 < x < 15$  years old, patient with surgical interventions (risk of the presence of the artifacts), patient with chronic pain.

Fifteen patients (11 males and 4 females, age in the range of 24–62) who was identified having edema in MRI have been completed the diagnostic path with DECT, using spectral images that enhance the concentration of water in the bone.

Out of 15 patients, 4 were vertebral columns, 2 knees, 3 ankles, 1 foot, 4 shoulders, and 1 wrist.

Bone marrow edema in MRI has been identified with water-sensitive sequences as a bone hyper-intensity in the proton density (PD) or weighted T2 sequences with fat subtraction. The MRI images were acquired with MR magnetic field 1.5 T “Faced” Array coil (GE, United States), matrix of  $224 \times 256$ , and FOV of 16–18 cm; four standardized sequences were performed for each patient: spin echo (SE) T1-weighted (W) (465/8; field of view,  $285\text{--}385 \times 250\text{--}305$  mm; matrix,  $260\text{--}300 \times 200\text{--}250$ ; section thickness, 4 mm; gap 0.4 mm), T2 W (turbo inversion-recovery magnitude imaging repetition time ms/echo time ms = 2000/70; inversion time, 150 ms; field of

view,  $285\text{--}385 \times 250\text{--}305$  mm; matrix,  $260\text{--}300 \times 200\text{--}250$ ; section thickness, 4 mm; gap, 0.4 mm). For Dual Energy images, tube voltages were set to 80 and 140 kVp with the tin filter activated.

For the evaluation of the bone marrow edema, the DECT with Dual-Energy technique was used, allows easy configuration of back-to-back axial or helical scans of the same anatomy at two different X-ray energies (kVs), which highlight the presence of water with respect to the other components constituting the analyzed tissue.

The DECT was acquired with Revolution EVO (General Electric (GE) healthcare, United States); the technical parameters were as follows:

Detector Configuration  $64 \times 0,625$  mm, 190 mAs,  $80 < x < 140$  kV, ASiR-V at 60%, Collimation 80 mm, slice thickness 0,625 mm, reconstruction increment of 1 mm, Pitch 0,9.

All the dual-energy data were obtained using a specific dual-energy deconvolution kernel provided and developed by GE healthcare.

The acquisition plan was based on the type of articulation examined.

MRI and DECT were compared to evaluate their diagnostic images’ concordances.

Two radiologists with at least 5 years of experience in musculoskeletal radiology have prospectively and independently examined the acquired images.

## Statistical analysis

We used descriptive statistical tests for nominal data such as t-Test. The statistical program used was SPSS 19 (IBM SPSS Statistics for Windows; IBM Corporation, Armonk, New York, USA). A *P* value less than 0.05 was considered significant.

## Result

The MRI images of 100 patients were evaluated to search bone marrow edema. Edema has been identified as “present or not present” in the MRI images.

When the edema was present, a DECT has been acquired.

The DECT and MRI images of 15 patients with bone marrow edema were compared.

Out of 15 patients, 4 were vertebral columns, 2 knees, 3 ankles, 1 foot, 4 shoulders, and 1 wrist.

Two radiologists with at least 5 years of experience in musculoskeletal radiology have prospectively examined the acquired images; the edema was “present or not present.”

Each radiologist made a measurement of the density of the pathological bone (with edema) of each patient (15 measurements each) using spectral images that enhance the concentration of water in the bone, and one on the healthy bone of the same patient as a control, for a total of 4 measurements for each patient (15 + 15 into the bone marrow edema et 15 + 15 into the healthy bone marrow).

The mean of pathologic bone marrow edema was 1008.20 (Standard Deviation (SD) 23.00), for healthy bone marrow 947.53 (SD 16.42), and  $t = 11.75$  [Table 1].

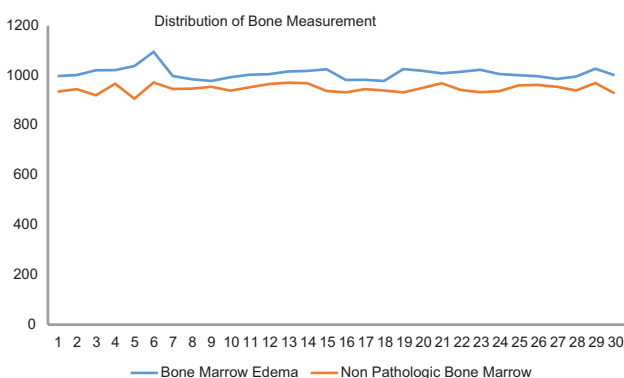
The result of the 30 measurements of the pathological bone was discordant from the 30 measurements on healthy bone, with a statistical significance  $P < 0.05$  (Statistical significance 95%).

The agreement between the measurements of the two radiologists was confirmed ( $P < 0.05$ ): The mean for the first operator of pathologic bone marrow edema was 1013.13 (SD 27.79), for healthy bone marrow 948.73 (SD 19.03), and  $t = 6.83$ .

The mean for the second operator of pathologic bone marrow edema was 1003.26 (SD 16.46), for healthy bone marrow 946.33 (SD 13,90), and  $t = 11.11$ .

The positivity of MRI in sequences with fat suppression is related to the positivity of DECT, after evaluating the images that increase the bone water presence.

**Table 1: Discrepancy between density measurements made in healthy and pathological bone marrow of the 15 patients by the two operators; each radiologist made a measurement of the density of the pathological bone marrow edema (blue) of each patient and one on the healthy bone (orange) of the same patient as a control, for a total of four measurements for each patient (15 + 15 into the bone marrow edema et 15 + 15 into the healthy bone marrow)**



Subjectively, for both radiologists, MRI has superior for edema evaluating.

DECT has fewer artifacts and more details with more spatial resolution.

### Discussion

The DECT presents a high diagnostic accuracy in the research of the bone marrow edema, comparable to that of the MRI [Figures 1A-D and 2A-D].

Subjectively, for both radiologists, MRI has superior for edema evaluation, but DECT has fewer artifacts and more details with more spatial resolution.

The use of DECT allows the search of additional information, such as bone marrow edema, even in patients without evident fractures.

Diseases such as algodystrophy can be visualized without the use of MRI, which is more expensive and less available [Figure 2a-d].

We have found few studies that speak about this topic.<sup>[10,11]</sup>

Bone marrow edema is the term given to abnormal fluid signal seen within the bone marrow on MRI. It is a nonspecific, yet important, finding usually indicating the presence of an underlying pathology.<sup>[1,4,5,10,11]</sup>

The new CT techniques developed, therefore, allow increasing the visualization of the water bone, distribution, identifying the edema.<sup>[7-9]</sup>

This novelty is extremely important above all, because until now, it was exclusively pertinent to other methods, in particular, MRI in radiology, or scintigraphy and PET-CT for nuclear medicine.<sup>[3,4,6,11,12]</sup>

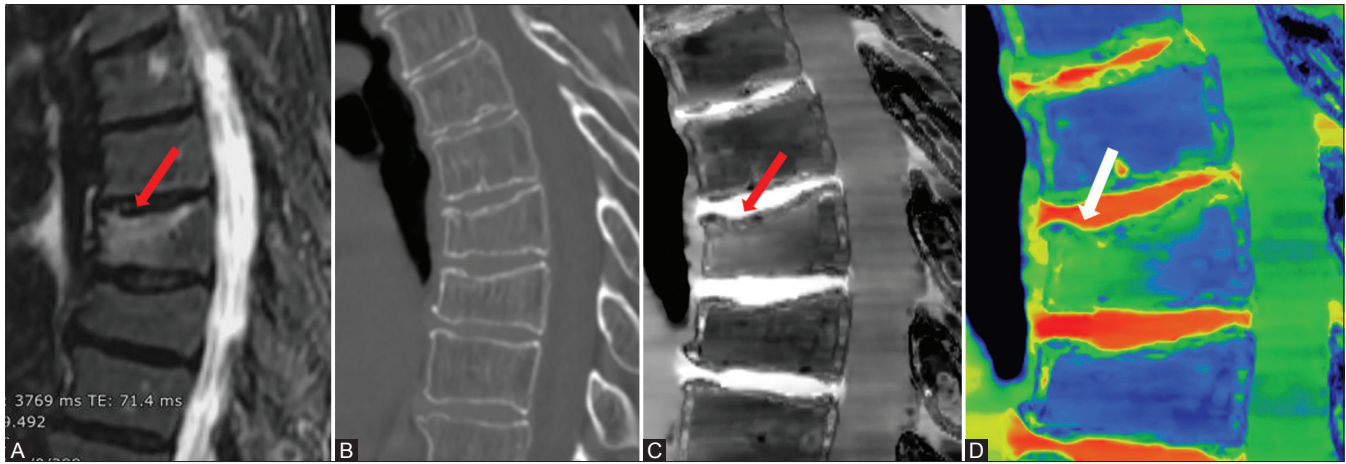
The possibility of a different diagnosis through the use of DECT will allow in the future determine the modification of the diagnostic radiology indications.<sup>[7,13]</sup>

Considering bone marrow edema, for example, it could be useful in an emergency service to search for a small no visible fracture [Figure 3a-c], a stress fracture, algodystrophy, arthritis, or other.

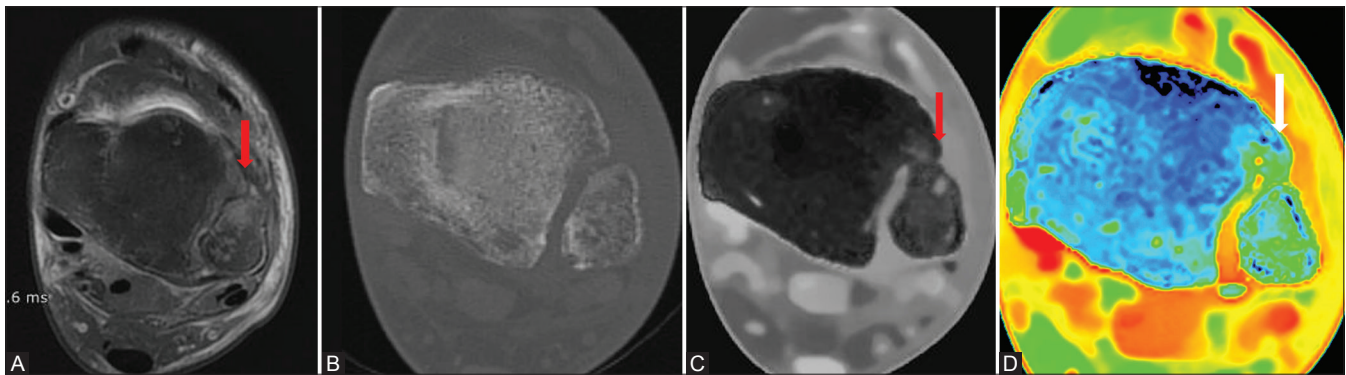
The utility of these recent possibilities is maximal where access to MRI is still very difficult.

MRI, more expensive and with limited access, can be used for more complex examinations, reducing to a minimum the diagnostic investigation after the acquisition of a DECT.<sup>[14]</sup>

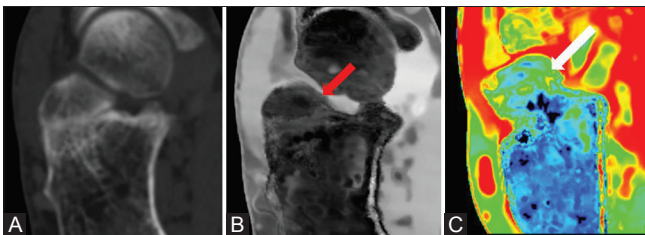




**Figure 1 (A-D):** Bone marrow edema in a recent vertebral fracture well visible in the MRI T2 weighted image with Fat Sat (A, arrow). The CT Images confirm the presence of the fracture (B); highlighting the distribution of water with Spectral CT, we observe the presence of bone marrow edema superimposable to MRI (C and D, arrow)



**Figure 2 (A-D):** Presence of fibular algodystrophy in nonrecent fracture outcomes, well visible in the MRI T2 weighted image with Fat Sat, with bone marrow edema (A, arrow). In the CT images, a minimal postfracture degenerative alteration is observed (B); highlighting the distribution of water with Spectral CT, we observe the presence of bone marrow edema superimposable to MRI (C and D, arrow)



**Figure 3 (A-C) :** A 38-year-old patient comes to our emergency service after a recent trauma. The CT images show a fracture of the anterior calcaneal joint (A); in the Spectral CT, we note the presence of consequent bone marrow edema (B and C, arrow)

The recent development of the DECT gives of the radiologist multiple diagnostic possibilities unknown with conventional CT.<sup>[7-9,13,15-17]</sup>

Dual-energy CT applications can largely be divided into exploration of material-nonspecific and material-specific energy-dependent information. Both evaluations can be qualitative or quantitative. The former includes virtual monoenergetic imaging, effective atomic map, and electron

density map. The latter includes material decomposition, material labeling, and material highlighting.<sup>[7,8,14]</sup>

With these recent techniques, two materials with different dual-energy slopes caused by different photoelectric effects can be differentiated by using a predefined separation line.<sup>[7,8,15]</sup>

Spectral imaging demonstrates clear clinical benefits. Tissue characterization utilizing CT is based on several features, including lesion enhancement, patterns of enhancement, lesion outline, and/or the presence of calcium or fat within the lesion.<sup>[7,9,14]</sup>

DECT enhances the diagnostic performance and confidence of CT by increasing iodine contrast-to-noise ratio, decreasing metal or beam-hardening artifacts, and providing material-specific information.<sup>[15]</sup>

Radiologists should explore the various clinical benefits of DECT, an emerging technology in medical imaging.<sup>[13-15]</sup>

The main limits of this study are low diffusion of the DECT presents in the territory, the small number of patients and data, and the lack of experience regarding the possibility of the DECT.

It is hoped that it will be offset in the years to come, going to greatly improve the diagnostic capabilities of the radiologist.

## Conclusion

The DECT presents an excellent capacity to detect the bone marrow edema, comparable to MRI.

The utility of these recent possibilities are maximum where access to MRI is still very difficult.

## Financial support and sponsorship

Nil.

## Conflicts of interest

There are no conflicts of interest.

## References

1. Manara M, Varena M. A clinical overview of bone marrow edema. *Reumatismo* 2014;66:184-96.
2. Sharma UK, Dhungel K, Pokhrel D, Tamang S, Parajuli NP. Magnetic resonance imaging evaluation of musculoskeletal diseases of ankle and foot. *Kathmandu Univ Med J (KUMJ)* 2018;16:28-34.
3. Rios AM, Rosenberg ZS, Bencardino JT, Rodrigo SP, Theran SG. Bone marrow edema patterns in the ankle and hindfoot: Distinguishing MRI features. *AJR Am J Roentgenol* 2011;197:W720-9.
4. Hayes CW, Conway WF, Daniel WW. MR imaging of bone marrow edema pattern: Transient osteoporosis, transient bone marrow edema syndrome, or osteonecrosis. *Radiographics* 1993;13:1001-11.
5. Blum A, Roch D, Loeuille D, Louis M, Batch T, Lecocq S, *et al.* Bone marrow edema: Definition, diagnostic value and prognostic value. *J Radiol* 2009;90:1789-811.
6. Takatori Y, Kokubo T, Ninomiya S, Nakamura T, Okutsu I, Kamogawa M. Transient osteoporosis of the hip: Magnetic resonance imaging. *Clin Orthop* 1991;271:190-4.
7. Goo HW, Goo JM. Dual-energy CT: New horizon in medical imaging. *Korean J Radiol* 2017;18:555-69.
8. Omoumi P, Verdun FR, Guggenberger R, Andreisek G, Becce F. Dual-energy CT: Basic principles, technical approaches, and applications in musculoskeletal imaging (Part 2). *Semin Musculoskelet Radiol* 2015;19:438-45.
9. Johnson TR, Krauss B, Sedlmair M, Grasruck M, Bruder H, Morhard D, *et al.* Material differentiation by dual energy CT: Initial experience. *Eur Radiol* 2007;17:1510-7.
10. Kaup M, Wichmann JL, Scholtz JE, Beeres M, Kromen W, Albrecht MH, *et al.* Dual-energy CT-based display of bone marrow edema in osteoporotic vertebral compression fractures: Impact on diagnostic accuracy of radiologists with varying levels of experience in correlation to MR imaging. *Radiology* 2016;280:510-9.
11. Ali IT, Wong WD, Liang T, Khosa F, Mian M, Jalal S, *et al.* Clinical utility of dual-energy CT analysis of bone marrow edema in acute wrist fractures. *AJR Am J Roentgenol* 2018;210:842-7.
12. Kon E, Ronga M, Filardo G, Farr J, Madry H, Milano G, *et al.* Bone marrow lesions and subchondral bone pathology of the knee. *Knee Surg Sports Traumatol Arthrosc* 2016;24:1797-814.
13. Kivity S, Gofrit SG, Baker FA, Leibushor N, Tavor S, Lidar M, *et al.* Association between inflammatory back pain features, acute and structural sacroiliitis on MRI, and the diagnosis of spondyloarthritis. *Clin Rheumatol* 2019;38:1579-85.
14. Martín Noguero T, Luna Alcalá A, Beltrán LS, Gómez Cabrera M, Broncano Cabrero J, Vilanova JC. Advanced MR imaging techniques for differentiation of neuropathic arthropathy and osteomyelitis in the diabetic foot. *Radiographics* 2017;37:1161-80.
15. Faby S, Kuchenbecker S, Sawall S, Simons D, Schlemmer HP, Lell M, *et al.* Performance of today's dual energy CT and future multi energy CT in virtual non-contrast imaging and in iodine quantification: A simulation study. *Med Phys* 2015;42:4349-66.
16. Wang CK, Tsai JM, Chuang MT, Wang MT, Huang KY, Lin RM. Bone marrow edema in vertebral compression fractures: Detection with dual-energy CT. *Radiology* 2013;269:525-33.
17. Pomerantz SR, Kamalian S, Zhang D, Gupta R, Rapalino O, Sahani DV, *et al.* Virtual monochromatic reconstruction of dual-energy unenhanced head CT at 65-75 keV maximizes image quality compared with conventional polychromatic CT. *Radiology* 2013;266:318-25.