

Comparative evaluation of success of ultrasound-guided internal jugular vein cannulation using needle with guard: A randomized, controlled study

Vikas Arya, Devendra Gupta, Anil Agarwal, Mekhala Paul, Prabhaker Mishra¹

Departments of Anaesthesiology and ¹Biostatistics, Sanjay Gandhi Post Graduate Institute of Medical Sciences, Lucknow, Uttar Pradesh, India

Abstract

Background and Aims: We devised a guard which can be slid and fixed over the central venous puncture needle at a desired length (measured through ultrasound) preventing the needle from penetrating deeper into the skin beyond this guard. This randomized, single blinded, controlled study was designed to evaluate the success of ultrasound guided internal jugular vein (IJV) cannulation using measured guided needle with guard in terms of success and occurrence of complications.

Material and Methods: After ethical approval and written informed consent from the patients ultrasound-guided right-sided IJV cannulation was done with a conventional puncture needle (length of 6.4 cm) in the control group ($n = 210$) and with a conventional puncture needle with a guard fixed proximal to the bevel at a distance equal to the distance between the skin entry point and the midpoint of IJV measured with the help of USG in the study group ($n = 210$). The primary outcome studied was the number of attempts for successful cannulation. The secondary outcomes studied were complications and ease of cannulation.

Results: 419 patients were randomized into control ($n = 209$) and study groups (210). Successful IJV cannulation in the first attempt (primary endpoint) in the study group was significantly higher compared to the control group (98.6 vs. 85.7%, $P = 0.007$). Posterior venous wall puncture was reduced in the study group, that is, 0.5% (1/210) compared to control group, that is, 8.61% (18/209) ($P = 0.001$). Common carotid artery puncture was 7.18% (15/209) in control group and 0% (0/210) in study group ($P = 0.001$). Operators rated better ease in study group ($P < 0.001$).

Conclusions: The use of measured guided needle with guard significantly improved the accuracy, success and ease of USG guided IJV cannulation and decreased complications.

Keywords: Central venous access, complications, ultrasonography, Internal jugular

Introduction

Ultrasound guidance has been suggested as being beneficial for placement of central venous catheters (CVCs) by improving the success rate, reducing the number of needle passes, and decreasing complications^[1-5] associated with CVCs. Despite the usage of ultrasound guidance for Internal Jugular Vein (IJV) cannulation, the incidence of carotid artery and

posterior venous wall puncture has been reported to be about 20% and 64%, respectively, in human simulators.^[6] Average distance of midpoint of IJV to the skin is 1-2 cm.^[7] However, the commercially available central venous cannulation sets are supplied with conventional 6.4 cm puncture. This puncture needle has a tendency to penetrate deeper and is thus more likely to puncture the posterior wall of the vein leading to hematoma formation and may even damage the structures lying underneath. The risk of common carotid artery (CCA)

Address for correspondence: Dr. Devendra Gupta,
Department of Anaesthesiology, Sanjay Gandhi Post
Graduate Institute of Medical Sciences, Lucknow - 226 014,
Uttar Pradesh, India.
E-mail: drdevendragpt@yahoo.com

Access this article online	
Quick Response Code:	Website: www.joacp.org
	DOI: 10.4103/joacp.JOACP_305_18

This is an open access journal, and articles are distributed under the terms of the Creative Commons Attribution-NonCommercial-ShareAlike 4.0 License, which allows others to remix, tweak, and build upon the work non-commercially, as long as appropriate credit is given and the new creations are licensed under the identical terms.

For reprints contact: reprints@medknow.com

How to cite this article: Arya V, Gupta D, Agarwal A, Paul M, Mishra P. Comparative evaluation of success of ultrasound-guided internal jugular vein cannulation using needle with guard: A randomized, controlled study. *J Anaesthesiol Clin Pharmacol* 2020;36:57-61.

Submitted: 23-Sep-2018 **Revised:** 29-Mar-2019 **Accepted:** 24-May-2019
Published: 18-Feb-2020

puncture is high in this scenario as the vein is found anteriorly placed or overlaps anterolaterally with respect to the artery in 41% and 34% of the cases, respectively.^[8]

We therefore devised a guard which can be slid and fixed over the needle at a desired length (measured through ultrasound) thus preventing the needle from penetrating deeper into the skin beyond this guard. This prospective, randomized, single-blinded, controlled study was designed to evaluate the efficiency of ultrasound-guided (US-guided) IJV cannulation using measured guided needle with guard in terms of success, ease and the complications.

Material and Methods

After approval from the Institutional Ethics Committee a prospective, randomized, single-blinded controlled study was conducted over a period of 2 years. Patients aged between 19 and 65 years of both sexes with ASA grade I-II undergoing surgery and requiring internal jugular venous access were included. Written informed consent was taken from all the patients. Patients with a history of neck surgery, CVC insertion within the previous 15 days, bleeding disorder, infection or phlebitis at the site of insertion, congestive heart failure, pulmonary or tricuspid valve stenosis/regurgitation, pulmonary hypertension, extreme obesity, severe obstructive pulmonary disease and patients with body mass index (BMI) of $>35 \text{ kg/m}^2$ were excluded.

Patients were evaluated for inclusion during their preoperative examination by Anesthesia consultant. In the operating room, the anesthesia consultant randomized and allocated the patient in to control or study groups with the help of computer generated table of random numbers. In the Control group: US-guided right-sided IJV cannulation was done with conventional puncture needle (length of 6.4 cm) and in the Study group: US-guided right-sided IJV cannulation was done with conventional puncture needle with guard fixed proximal to the bevel at a distance equal to the distance between skin entry point and the midpoint of IJV measured with the help of USG. The guard was prepared with a non-PVC disc with a central hole through which the needle shaft fits snugly [Figure 1].

IJV cannulations were performed by senior residents of the respective operation rooms who had more than 2 years of

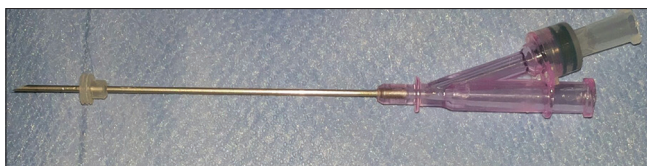


Figure 1: Puncture needle with guard

experience in US-guided IJV cannulation. The procedure and method was explained to them with the help of a pre-recorded video. After induction of anesthesia and intubation patients were placed in 15° Trendelenburg position. Appropriate skin preparation and draping of the skin of the right side neck was done at the apex of the triangle formed by sternal and clavicular heads of the sternocleidomastoid. A linear transducer probe of a 6.5 to 13-MHz (Micromax portable ultrasound machine, Sonosite, USA) was placed at the apex of triangle with minimal pressure to avoid IJV compression in the short axis approach. The distances between skin and midpoint of the right IJV, skin to posterior wall of the IJV, position of the IJV in relation of CCA were noted. The IJV of right side was punctured under real-time ultrasound guidance by a conventional needle in control group and a needle with guard fixed at the measured distance from the needle's tip in the study group. Insertion of needle in effort to puncture the IJV was considered as an attempt. Pulling out the needle in case of failure to puncture the IJV was also considered as an attempt.

An independent observer not involved in the IJV cannulation monitored the procedure. The primary outcome was the number of attempts for successful cannulation. Secondary outcomes were complications and ease of cannulation. The expected complications were failure to cannulate the vein, accidental CCA puncture, pneumothorax, vertebral artery puncture and damage to other important structures of neck. Based on the success of cannulation and the presence of complications, the performer anesthesiologists were asked to rate the ease of cannulation on a score of 1-5 (1 = extreme dissatisfaction, 2 = dissatisfied, 3 = neutral, 4 = satisfied and 5 = highly satisfied).

Sample size estimation

A sample size of 201 patients in each group was calculated to achieve 85% power with an alpha error of 0.05 to detect a difference of 7.5% between the groups based on a pilot study which showed success rates of 95 and 87.5%.

Statistical analysis

Normality of the continuous variables was assessed and the variables were considered normally distributed when standard deviation (SD) was approximately less than $\frac{1}{2}$ mean. Normally distributed variables were presented in mean \pm SD and categorical variables as frequency and percentage. To compare the mean score between control and study groups, independent samples t-test was used while to compare the proportions between two groups, Chi-square test/Fisher's exact test was used. Difference in proportions and its 95% confidence interval (CI), relative risk (RR) and its 95% CI, number needed to treatment (NNT) were calculated.^[9] A *P* value <0.05 was

considered to be statistically significant. Statistical analysis was done using software “Statistical Package for Social Sciences, version-23 (SPSS-23, IBM, Chicago, IL, USA)” and “MedCalc”.

Results

A total of 445 consecutive patients were evaluated. 25 patients were excluded on account of history of previous CVC insertion within 15 days ($n = 3$), antiplatelet therapy/bleeding disorder ($n = 9$), body mass index (BMI) >35 kg/m² ($n = 5$) and COPD ($n = 8$). The remaining 420 patients enrolled in the study. In one patient of control group, the right IJV was found to be thrombosed on ultrasonography and therefore the procedure was abandoned. This patient was considered as a drop out and was not included in the final analysis. 419 patients completed the study and were subjected to statistical analysis (209 and 210 control and study groups, respectively) [Figure 2].

Patients of both the groups were comparable with respect to age, weight, height, gender and BMI [Table 1]. In control and study groups, the mean depth of midpoint of IJV (mean \pm SD 12.7 ± 1.5 vs 12.8 ± 1.3 mm,

Independent samples t test, $P = 0.454$) depth of posterior wall of IJV (mean \pm SD 15.4 ± 1.3 vs 15.6 ± 1.2 , Independent samples t test, $P = 0.078$) and depth of anterior wall of CCA (mean \pm SD 15.9 ± 1.3 vs 16.0 ± 1.2 , Independent samples t test, $P = 0.459$) from point of entry at skin as measured through ultrasound scanning were statistically same. There was no significant difference in proportions of the relationship of IJV to CCA between two study groups [Table 2].

Successful IJV cannulation in the first attempt in study group, that is, 98.6% (207/210) was significantly higher compared to control group, that is, 85.7% (179/209) [difference = 12.9%, 95% corrected CI for the difference 7.9%-18.5%, [Figure 3a].

Posterior venous wall puncture (secondary endpoint) was 8.6% (18/209) in the control group compared to 0.5% (1/210) in the study group. [difference = 8.1%, 95% corrected CI for the difference 4.1%-12.8%, $P = <0.001$]. RR of posterior venous wall puncture in the study group was 0.06 [95% CI = 0.008-0.41, = 0.005], NNT was 12.3. Common carotid artery puncture was 7.2% (15/209) in the control group, no CCA puncture was observed in the study group [difference = 7.2%, 95% CI = 3.6%-11.6%, $P = 0.001$]. NNT was 13.9. In the control group, CCA puncture was more common in the patients with IJV and CCA in anterior relationship [11/15 (73.3%), $P = 0.011$]. In 12 cases, the needle passed through posterior venous wall to puncture CCA. Operator anesthesiologists rated better ease in study group ($P < 0.001$) [Figure 3b].

Discussion

The present study has shown that the use of guard over the conventional needle increased the success of IJV cannulation in the first attempt and decreased the complications associated like carotid puncture or posterior venous wall puncture.

The ultrasound beam in real-time ultrasound scan is narrow (0.2-1.2 mm) and despite the operator trying to

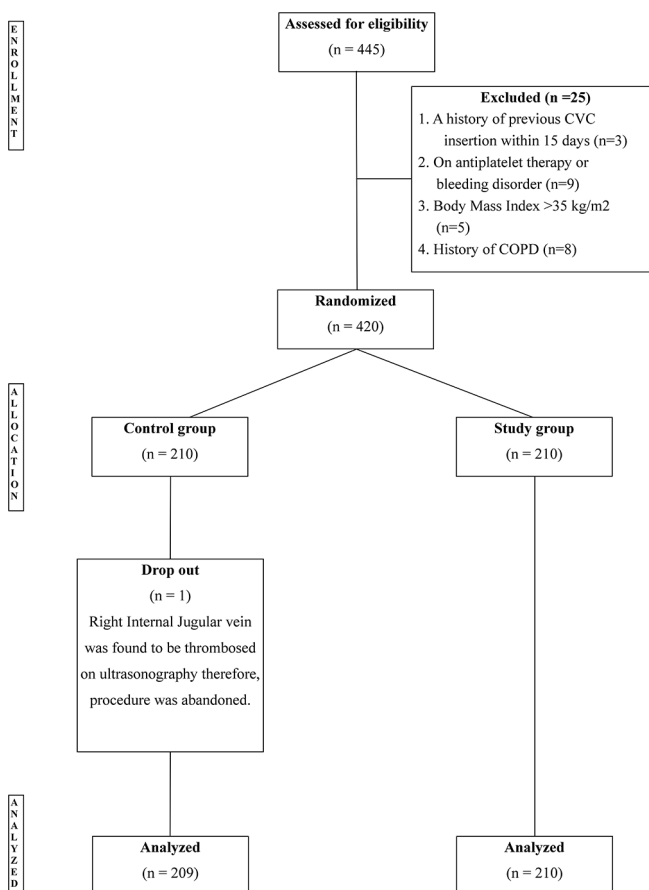


Figure 2: Consort diagram

Table 1: Demographic characteristics of the study participants

Groups Parameters	Control Group (n=210)	Study Group (n=210)	P
Age (years)	44.0 \pm 13.2	43.3 \pm 13.4	0.6
Sex ratio (M/F)	121/89	132/78	0.2
Weight (kg)	62.3 \pm 8.1	62.5 \pm 8.7	0.9
Height (cm)	160.4 \pm 7.5	161.2 \pm 7.3	0.3
Body mass index (kg/m ²)	24.2 \pm 3.0	24.0 \pm 2.8	0.5

Continuous variables presented in mean \pm SD and compared using independent samples t test. *Categorical variable's presented in frequency and compared using Chi-square test. $P < 0.05$ denotes significant difference

Table 2: Anatomical relationship between IJV and CCA shown by ultrasonography

Groups Parameters	Control Group (n=209)	Study Group (n=210)	Total (n=419)	P
Lateral	128 (61.2%)	115 (54.8%)	243 (58.0%)	0.3
Anterior (complete overlapping)	27 (12.9%)	42 (20%)	69 (16.5%)	
Anterio-lateral (partial overlapping)	48 (23.0%)	45 (21.4%)	93 (22.2%)	
Medial	6 (2.9%)	8 (3.8%)	14 (3.3%)	

Categorical variable's presented in frequency and compared using Chi-square test. $P < 0.05$ denotes significant difference

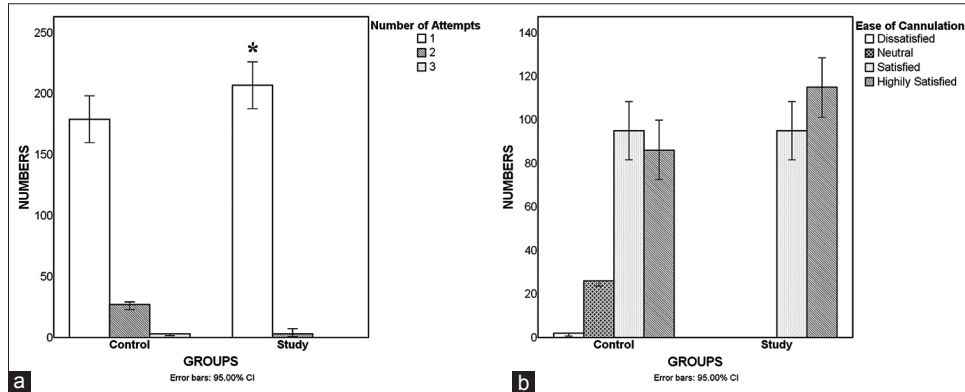


Figure 3: (a) Number of attempts. Categorical variable's presented in frequency and compared using Chi-square test. *denotes $P < 0.05$. (b) Ease of cannulation. Categorical variable's presented in frequency and compared using Chi-square test. * $P < 0.05$

visualize the needle tip and place it in the vein, many a time the tip might actually cross beyond the ultrasound beam, and a cross section of the proximal part of the needle is appreciated in the view.^[10] In this circumstance, the tip may have already penetrated the posterior venous wall. In case any structure like the CCA lies beneath the posterior venous wall it can get punctured or damaged. Placement of guard over the needle prevented the operator from overshooting the needle beyond the venous lumen. Additionally, the operator did not require to withdraw the needle to bring the tip in the venous lumen thus increasing the success of IJV cannulation in first attempt. The guard over the needle also provided a visual feedback of the length of penetration to the operator outside the skin. In control group, carotid artery puncture was more common in the patients with IJV and CCA in anterior relationship suggesting that any degree of overshoot leading to posterior venous wall puncture caused puncture of the carotid artery lying just underneath.

A meta-analysis comparing the long-axis/in-plane and short-axis/out-of-plane (SA-OOP) approaches for ultrasound-guided vascular catheterization, found that the total success rate was similar for US-guided IJV catheterization; however, the number of attempts may be reduced with the SA-OOP approach.^[11] In longitudinal-axis approach, the needle easily moves out of plane and disappears from the screen. Further, disproportion between the thickness of the ultrasound plane and the needle diameter creates difficulty in visualization

of the entire needle longitudinally.^[10] Partial visualization may cause the same phenomenon described previously for the posterior wall and makes one vulnerable for injury to posterior or lateral wall of IJV. A high degree of skill and good hand eye coordination are required to keep the entire needle length within the sonographic view.^[10] Hence, a major portion of the studies on ultrasound-guided vascular access in literature use the short-axis approach.^[12-14]

Many modifications of needle were done in the past. Creating indenting markings on the existing unmarked introducer needle has been shown to improve IJV cannulation and decrease the complications.^[15] An echogenic vascular cannula with "Cornerstone" reflectors near the tip significantly improved cannula visibility and decreased access time though failed to reduction in mechanical complications.^[16] Although interpretation of dynamic 2D ultrasound images remains subjective, differentiation of the real needle tip and echogenic reflectors of the shaft in ultrasound image requires greater expertise. Our guard over needle technique provided additional safety as it not only indicated the length of the needle to be inserted but also protected against any inadvertent force on the needle by the operator.

Limitations

The present technique guards the excessive needle penetration inside the subcutaneous plane. However, applying undue inward force on the needle per se causes venous collapse thereby decreasing the depth of the posterior venous wall from

the skin and thus jeopardizing safety. A minimal application of force is utmost important for safe central venous catheterization. Operator blinding was also not possible so might have created some bias in the results.

In conclusion, our investigation demonstrated that the use of measured guided needle with guard significantly improved the accuracy, success and eases of USG-guided IJV cannulation and decreased the incidences of posterior venous wall puncture and CCA puncture. Our data also provided anatomical relationship between IJV and CCA and the clinical rationale of using real-time ultrasonography for all IJV cannulation. We therefore suggest that measured guided needle with guard should be routinely used for IJV cannulation. Further studies with larger sample size are suggested to explore the usage of this needle with guard for other venous and arterial cannulation in future.

Financial support and sponsorship

Nil.

Conflicts of interest

There are no conflicts of interest.

References

- Randolph AG, Cook DJ, Gonzales CA, Pribble CG. Ultrasound guidance for placement of central venous catheters: A meta analysis of the literature. *Crit Care Med* 1996;24:2053-8.
- Machi J, Takeda J, Kakegawa T. Safe jugular and subclavian venipuncture under ultrasonographic guidance. *Am J Surg* 1987;153:321-3.
- Bond DM, Champion LK, Nolan R. Real-time ultrasound imaging aids jugular venipuncture. *Anesth Analg* 1989;68:700-1.
- Malloy DL, McGee WT, Shawker TH, Brenner M, Bailey KR, Evans RG, et al. Ultrasound guidance improves the success rate of internal jugular vein cannulation: A prospective, randomized trial. *Chest* 1990;98:157-60.
- Dennys BG, Uretsky BF, Reddy S. Ultrasound-assisted cannulation of the internal jugular vein a prospective comparison to the external landmark-guided technique. *Circulation* 1993;87:1557-62.
- Blaivas M, Adhikari S. An unseen danger: Frequency of posterior vessel wall penetration by needles during attempts to place internal jugular vein central catheters using ultrasound guidance. *Crit Care Med* 2009;37:2345-49.
- Fragou M, Gravvanis A, Dimitriou V, Papalois A, Kouraklis G, Karabinis A, et al. Real-time ultrasound-guided subclavian vein cannulation versus the landmark method in critical care patients: A prospective randomized study. *Crit Care Med* 2011;39:1607-12.
- Umaña M, García A, Bustamante L, Castillo JL, Sebastián Martínez J. Variations in the anatomical relationship between the common carotid artery and the internal jugular vein: An ultrasonographic study. *Colomb Med (Cali)* 2015;46:54-9.
- Armitage P, Berry G. *Statistical Methods in Medical Research*. 3rd ed. London: Blackwell; 1994. p. 131.
- Levitov AB, Aziz S, Slonim AD. Before we go too far: Ultrasound-guided central catheter placement. *Crit Care Med* 2009;37:2473-4.
- Liu C, Mao Z, Kang H, Hu X, Jiang S, Hu P, et al. Comparison between the long-axis/in-plane and short-axis/out-of-plane approaches for ultrasound-guided vascular catheterization: An updated meta-analysis and trial sequential analysis. *Ther Clin Risk Manag* 2018;14:331-40.
- Hrics P, Wilber S, Blanda MP, Gallo U. Ultrasound-assisted internal jugular vein catheterization in the ED. *Am J Emerg Med* 1998;16:401-3.
- Miller AH, Roth BA, Mills TJ, Woody JR, Longmoor CE, Foster B. Ultrasound guidance versus the landmark technique for the placement of central venous catheters in the emergency department. *Acad Emerg Med* 2002;9:800-5.
- Hilty WM, Hudson PA, Levitt MA, Hall JB. Real-time ultrasound-guided femoral vein catheterization during cardiopulmonary resuscitation. *Ann Emerg Med* 1997;29:331-36.
- Ghatak T, Singh RK, Baronia AK. Comparison between marked versus unmarked introducer needle in real-time ultrasound-guided central vein cannulation: A prospective randomized study. *Ann Card Anaesth* 2016;19:621-5.
- Stefanidis K, Fragou M, Pentilas N, Kouraklis G, Nanas S, Savel RH, et al. Optimization of cannula visibility during ultrasound-guided subclavian vein catheterization, via a longitudinal approach, by implementing echogenic technology. *Crit Care Res Pract* 2012;2012:617149.