



Cerebral venous thrombosis after COVID-19 vaccines: Do we know the mechanism?

Cesare de Gregorio,^{a*} Giuseppe Calcaterra,^b Nicholas G. Kounis,^c Pier Paolo Bassareo,^d and Jawahar L. Mehta^e

^aDepartment of Clinical and Experimental Medicine, Cardiology Unit. Outpatient Heart failure, Cardiomyopathy and Vascular Lab. University Hospital of Messina, Via Consolare Valeria, Messina 98125, Italy

^bUniversity of Palermo, Adjunct Professor of Cardiology, Postgraduate Medical School of Cardiology, Palermo 90127, Italy

^cDepartment of Internal Medicine, Division of Cardiology, University of Patras Medical School, Patras 26221, Greece

^dDepartment of Cardiology, Mater Misericordiae University Hospital, University College of Dublin, School of Medicine, Dublin D07R2WY, Ireland

^eDepartment of Medicine, University of Arkansas for Medical Sciences and the Veterans Affairs Medical Center, Little Rock, AR 72205, USA

The Covid-19 pandemic has affected the world community for over 2 years. Since December 2020, most countries started with Covid-19 vaccination programmes using messenger RNA (BNT162b2 and mRNA-1273/CX-024414) and adenovirus vector (ChAdOx1nCoV-19 and JNJ-78436735) vaccines, with an extraordinarily rapid distribution that allowed over 10 billion doses administered to date.

We read with interest the article of Andrews et al. recently published in the *Journal*,¹ who reported a large retrospective study of hospital admissions for venous thrombotic events, including cerebral venous sinus thrombosis (CVST), with and without thrombocytopenia, in a national cohort of over 45 million Covid-19 vaccine eligible individuals in England. In their in-depth analysis, authors revealed a significant risk for thrombosis and thrombocytopenia in adults under 65 years of age (under 40 years the most) after receiving ChAdOx1nCoV-19, but not BNT162b2, vaccination.

Interestingly, these findings support ours from a recent review of 552 worldwide-published cases of CVST after Covid-19 vaccination.² In both studies, CVST occurred after the first dose of ChAdOx1nCoV-19 vaccination, and coexisting thrombocytopenia was established in some patients. Andrews et al. reported such events within 30 days of the primary immunization (in our study, the median time was 9 days, range: 2-42), but it is unclear whether cases of Covid-19 infection-related CVST were also included in their analysis.

It was surprising to see no gender effect for any outcome, first for CVST (the subset at the highest attributable risk after adenovirus vector vaccine). Conversely, in

the same period, the European Medicines Agency³ and a German registry⁴ reported a clear female gender predominance, with up to 75% of cases among the ChAdOx1nCoV-19 vaccine recipients. In the 41 studies reviewed in our article, the occurrence of CVST was 2.25-fold higher in women than in men, even though two studies from England quoted this complication in 111 women and 86 men, with a women/men ratio of 1.29. This could be an expression of sex-related discrepancies among countries.²

Further, from all examined English hospital admissions Andrews et al. provided an attributable risk of 16.1 CVST per million doses for individuals aged 15–39 years and 3.2 for those aged 40–64 years, suggestive of an interplay between adenovirus vaccination and venous thrombotic risk. In view of early scientific reports on CVST among vaccinated women between 35 and 50 years of age, it is reasonable to believe that this age-clustered analysis could have been more epidemiologically relevant.

Although their proven causality comes in the late stages of current pandemic, we congratulate the authors for their insightful work that substantiates the incident CVST among ChAdOx1nCoV-19 vaccinated people, resulting in a higher risk rate than the estimated incidence of 0.5–0.8 per 1,000,000 individuals in the (pre-pandemic) US general population. Regrettably, most patients experiencing poor outcomes after vaccine administration were apparently healthy subjects (approximately one third of cases in our review died due to severe intracranial bleeding and brain injury, with multiorgan thrombosis present in >90% of these), and available histopathological findings demonstrated an underlying immune macro- and micro-vasculitis.²

Several pathological issues were discussed in our study (Figure), such as vaccine-induced immune thrombotic thrombocytopenia, prothrombotic conditions, age, sex, anatomical and dysfunctional variants of the venous system, allergic reactions to vaccine components and impaired protein-homeostasis-systems,^{2,5} but we as yet have no certain proof of the precise mechanism(s) of

The Lancet Regional Health - Europe

2022;16: 100387

Published online 14 April 2022

<https://doi.org/10.1016/j.lanepe.2022.100387>

DOI of original article: <http://dx.doi.org/10.1016/j.tgie.2019.150641>

*Corresponding author.

E-mail address: cesare.degregorio@unime.it (C. de Gregorio).

© 2022 The Author(s). Published by Elsevier Ltd. This is an open access article under the CC BY-NC-ND license (<http://creativecommons.org/licenses/by-nc-nd/4.0/>)

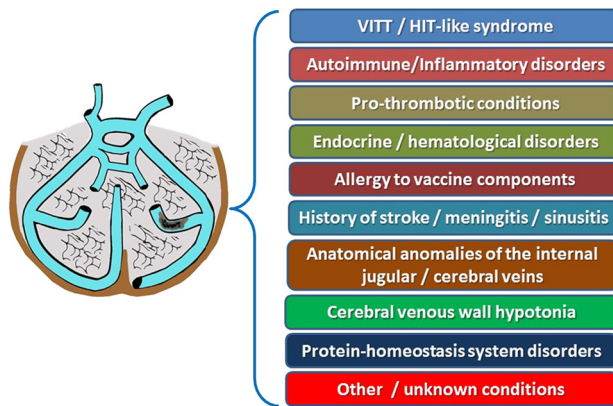


Figure. Pathogenetic hypotheses of CVST in ChAdOx1nCoV-19 vaccine recipients. VITT: vaccine-induced immune thrombotic thrombocytopenia; HIT: heparin-induced thrombocytopenia.

vascular thrombogenicity. Therefore, additional efforts should be directed towards redefining the COVID-19 vaccine-related thrombogenic settings and preparing clinicians to be aware of such unexpected, often devastating, outcomes.

Author contribution

CdG, GC: conceptualization, data curation, original draft, writing. CdG, PPB, JLM, GC: critical analysis, review and editing. CdG, NJK and JLM: supervision and validation. All authors have read and approved the manuscript.

Declaration of interests

None to declare.

References

- 1 Andrews NJ, Stowe J, Ramsay ME, Miller E. Risk of venous thrombotic events and thrombocytopenia in sequential time periods after ChAdOx1 and BNT162b2 COVID-19 vaccines: a national cohort study in England. *Lancet Reg Health Eur.* 2022;13:100260. <https://doi.org/10.1016/j.lanepe.2021.100260>.
- 2 de Gregorio C, Colarusso L, Calcaterra G, et al. Cerebral venous sinus thrombosis following COVID-19 vaccination: analysis of 552 worldwide cases. *Vaccines.* 2022;10(2):232. <https://doi.org/10.3390/vaccines10020232>. (Basel).
- 3 Krzywicka K, Heldner MR, Sánchez van Kammen M, et al. Post-SARS-CoV-2-vaccination cerebral venous sinus thrombosis: an analysis of cases notified to the European Medicines Agency. *Eur J Neurol.* 2021;28(11):3656–3662. <https://doi.org/10.1016/j.euroneuro.2021.08.001>.
- 4 Schulz JB, Berlit P, Diener HC, et al. COVID-19 Vaccine-associated cerebral venous thrombosis in Germany. *Ann Neurol.* 2021;90:627–639. <https://doi.org/10.1002/ana.26172>.
- 5 Kounis NG, Koniari I, de Gregorio C, et al. Allergic Reactions to current available COVID-19 vaccinations: pathophysiology, causality, and therapeutic considerations. *Vaccines.* 2021;9(3):221. <https://doi.org/10.3390/vaccines9030221>. (Basel).